

A
CROSS-SECTION
ANATOMY

EYCLESHYMER & SCHOEMAKER

A
CROSS-SECTION
ANATOMY

R
024:611
C 97
1911
c.1

A CROSS-SECTION ANATOMY

BY

ALBERT C. EYCLESYMER, B.S., Ph.D., M.D.

PROFESSOR OF ANATOMY, ST. LOUIS UNIVERSITY; FORMERLY ASSISTANT PROFESSOR OF ANATOMY, UNIVERSITY OF CHICAGO; SOMETIME ASSISTANT PROFESSOR OF EMBRYOLOGY, RUSH MEDICAL COLLEGE

AND

DANIEL M. SCHOEMAKER, B.S., M.D.

ASSOCIATE PROFESSOR OF ANATOMY, ST. LOUIS UNIVERSITY; FORMERLY ASSISTANT IN ANATOMY, UNIVERSITY OF CHICAGO

AVERAGE POSITION OF ORGANS FROM ELEVEN RECONSTRUCTIONS, By PETER POTTER, A.M., M.D., Formerly Associate Professor of Anatomy, St. Louis University, Sometime Instructor in Anatomy, University of Missouri; *SECTIONS OF THE FEMALE PELVIS*, By CARROLL SMITH, A.B., M.D., Instructor in Anatomy, St. Louis University; *DRAWINGS*, By TOM JONES, Instructor in Drawing, St. Louis University



NEW YORK AND LONDON
D. APPLETON AND COMPANY

1911

COPYRIGHT, 1911, BY
D. APPLETON AND COMPANY

Printed in the United States of America

TABLE OF CONTENTS

	PAGE
I. Introduction.	
A. <i>Historical</i>	ix
B. <i>The Present Work</i>	xiii
Purpose	xiii
Materials	xiv
Methods	xiv
Illustrations	xvi
Nomenclature	xvi
Text	xvi
 II. Key-Figures, Illustrations of Cross-Sections and Explanatory Notes.	
KEY-FIGURE I.—Surface levels of sections of head and neck	3
KEY-FIGURE II.—Levels of sections with reference to surface of brain, bones of skull and superficial muscles of neck	7
KEY-FIGURE III.—Levels of sections with reference to structures seen in median sagittal section of head and neck	11
SECTION 1.—Layers of scalp and membranes of brain	15
SECTION 2.—The upper portions of the cerebral hemispheres	19
SECTION 3.—Intersecting fibres from the corona radiata and the corpus callosum	23
SECTION 4.—Just above the corpus callosum	27
SECTION 5.—The upper portion of the body of the corpus callosum	31
SECTION 6.—The knee and the splenium of the corpus callosum	35
SECTION 7.—The upper margin of the orbit and the anterior and posterior commissures	39
SECTION 8.—The lens and just above the optic chiasma, and through the crura cerebri	43
SECTION 9.—The hypophysis and the middle of the cerebellum	47
SECTION 10.—The lower margin of the orbit and the external auditory meatus. (Reid's base line)	51
SECTION 11.—The inferior turbinate bones and upper portion of the medulla oblongata	55
SECTION 12.—The hard palate and the condyles of the occipital bone	59
SECTION 13.—The oral cavity and the odontoid process of the axis	63
SECTION 14.—The body of the axis	67
SECTION 15.—The lower third of the axis	71
SECTION 16.—The middle of the third cervical vertebra	75
SECTION 17.—The third cervical disc	79
SECTION 18.—The lower third of the fourth cervical vertebra	83
KEY-FIGURE IV.—The levels of the sections of the trunk with reference to the bones	87
KEY-FIGURE V.—The levels of the sections of the trunk with reference to the principal muscles	91
KEY-FIGURE VI.—The levels of the sections of the trunk with reference to the heart, principal blood vessels and nerves	95
KEY-FIGURE VII.—The levels of the sections of the trunk with reference to the principal organs of the thorax and abdomen	99
SECTION 19.—The lower third of the fifth cervical vertebra	103
SECTION 20.—The upper third of the seventh cervical vertebra	107
SECTION 21.—The lower third of the first thoracic vertebra	111
SECTION 22.—The upper third of the third thoracic vertebra	115
SECTION 23.—The middle third of the fourth thoracic vertebra	119
SECTION 24.—The lower third of the fifth thoracic vertebra	123
SECTION 25.—The upper third of the seventh thoracic vertebra	127
SECTION 26.—The lower third of the eighth thoracic vertebra	131
SECTION 27.—The ninth thoracic disc	135
SECTION 28.—The tenth thoracic disc	139
SECTION 29.—The eleventh thoracic disc	143
SECTION 20.—The lower margin of the twelfth thoracic vertebra	147
SECTION 31.—The lower third of the first lumbar vertebra	151
SECTION 32.—The middle of the second lumbar vertebra	155
SECTION 33.—The upper third of the third lumbar vertebra	159

TABLE OF CONTENTS

	PAGE		PAGE
SECTION 34.—The third lumbar disc	163	SERIAL SECTIONS 61, 62.—The upper third of the forearm	243, 247
SECTION 35.—The lower third of the fourth lumbar vertebra	167	SECTION 63.—The junction of the upper and middle thirds of the forearm	247
SECTION 36.—The upper third of the fifth lumbar vertebra	171	SERIAL SECTIONS 64, 65, 66.—The middle third of the forearm	247, 251
SECTION 37.—The lower margin of the fifth lumbar vertebra	175	SECTION 67.—The junction of the middle and lower thirds of the forearm	251
SECTION 38.—Just below the promontory and through the anterior superior iliac spines	179	SERIAL SECTIONS 68, 69.—The lower third of the forearm	251
SECTION 39.—The third sacral vertebra	183	SECTION 70.—The styloid process of the radius and the semilunar, scaphoid and cuneiform bones	255
SECTION 40.—The fifth sacral vertebra and the upper portion of the acetabulum	187	SECTION 71.—The distal row of the carpal bones	255
SECTION 41.—The upper portion of the greater trochanter and just below the crest of the pubis	191	SECTION 72.—The proximal portion of the metacarpal bones	255
SECTION 42.—The lower portion of the greater trochanter and the subpubic angle	195	SECTION 73.—The base of the first phalanx of the first digit and the shafts of the second, third, fourth and fifth metacarpal bones	255
SECTION 43.—The lesser trochanters and the ischial tuberosities	199	SECTION 74.—The distal portion of the first phalanx of the first digit and the distal portions of the second, third, fourth and fifth metacarpal bones	259
SECTION 44.—The upper third of the femur, a little below the lesser trochanter	203	SECTION 75.—The middle portion of the first phalanx of the second, third, fourth and fifth digits	259
KEY-FIGURE VIII.—The levels of the sections of the female pelvis with reference to structures seen in mesial sagittal plane	207	KEY-FIGURE XI.—The levels of the sections of the lower extremity with reference to the bones, principal blood vessels and nerves	263
SECTION 45.—The female pelvis at the level of the sacro-coccygeal articulation and the anterior inferior spines of the ilium	211	KEY-FIGURE XII.—The levels of the sections of the lower extremity with reference to the principal muscles	263
SECTION 46.—The female pelvis at the level of the middle of the acetabulum	215	SECTION 76.—The lower portion of the upper third of the femur	267
SECTION 47.—The female pelvis at the level of the upper portion of the pubic symphysis	219	SECTION 77.—The junction of upper and middle thirds of the femur	267
SECTION 48.—The female pelvis at a level just above the lesser trochanter of the femur	223	SERIAL SECTIONS 78, 79, 80, 81, 82, 83.—The middle third of the femur	271, 275, 279
SECTION 49.—The female pelvis at the level of the lower margin of the lesser trochanter of the femur	227	SECTION 84.—The junction of the middle and lower thirds of the femur	283
KEY-FIGURE IX.—The levels of the sections of the upper extremity with reference to the bones, principal blood vessels and nerves	231	SERIAL SECTIONS 84, 85.—Hunter's canal	283
KEY-FIGURE X.—The levels of the sections of the upper extremity with reference to the principal muscles	231	SERIAL SECTIONS 86, 87, 88.—The lower third of the femur	287, 291
SECTION 50.—The arm at the level of the lower portion of the bicipital groove	235	SECTION 89.—The base of the patella	291
SERIAL SECTIONS 51, 52, 53, 54.—The middle third of the humerus	235, 239	SECTION 90.—The epicondyles of the femur and apex of patella	291
SERIAL SECTIONS 55, 56, 57.—The lower third of the humerus	239	SECTION 91.—The knee joint	291
SECTION 58.—The olecranon, coronoid and radial fossae	243	SECTION 92.—The head of the fibula and the lower portion of the condyles of the tibia	295
SECTION 59.—The elbow joint	243	SECTION 93.—The tuberosities of the tibia	295
SECTION 60.—The neck of the radius and just below the coronoid process of the ulna	243	SERIAL SECTIONS 94, 95, 96.—The upper thirds of the tibia and fibula	295, 299
		SERIAL SECTIONS 97, 98, 99, 100, 101.—The middle thirds of the tibia and fibula	299, 303

TABLE OF CONTENTS

vii

PAGE	PAGE
KEY-FIGURE XIII.—The levels of the sections of the lower portion of the leg and the foot with reference to the bones	307
KEY-FIGURE XIV.—The levels of the sections of the lower portion of the leg and the foot with reference to the muscles	307
SERIAL SECTIONS 102, 103, 104, 105, 106.—The lower thirds of the tibia and fibula	303, 311
SECTION 107.—The external malleolus, the proximal portion of the astragalus and the calcaneus	311
SECTION 108.—The distal portion of the astragalus and the body of the calcaneus	315
SECTION 109.—The sesmoid, cuboid and distal portion of the calcaneus	315
SECTION 110.—The first, second and third cuneiforms, the cuboid and the base of the fifth metatarsal bones	315
SECTION 111.—The proximal portions of the metatarsal bones	315
SECTION 112.—The shafts of the metatarsal bones	319
SECTION 113.—The distal portions of the first, second, third and fourth metatarsals and the base of the first phalanx of the fifth digit	319
III. <i>Topography of Organs.</i> ¹	
Sternum	321
Innominate bones	322
Stomach	322
Duodenum, jejunum, ileum	323
Cecum	324
Vermiform appendix	324
Colon	325
Pancreas	325
Liver	326
Gall-bladder	327
Spleen	327
Trachea	328
Lungs	328
Kidneys	330
Suprarenals	331
Heart and heart valves	332
Aorta	334
Vena Cava (Superior)	335
Vena Cava (Inferior)	335
Umbilicus	336
Table giving vertebral levels of various organs 339, 340	
Illustration showing organs at average vertebral levels	343
IV. <i>Bibliography</i>	345
V. <i>Index</i>	347

¹ The order in which the various organs have been considered is that given in the BNA.

INTRODUCTION

A. Historical.—The following historical sketch is given to show the growth of the section method in the study of gross anatomy and to emphasize its importance for the student, the anatomist and the clinician.

To state positively by whom and when the method was introduced would necessitate a long and tedious search. Certain it is that the method was used in the early part of the sixteenth century, since at this time Leonardo da Vinci, according to Chamberlaine and Choulant, pictured median sagittal sections of the bodies of both the male and female; the sections are represented as extending from the level of the shoulder to the lower portion of the pelvis. The Flemish anatomist, André Vésale, was probably the first to represent transverse sections of the brain. In the seventeenth century Vidius, Placentinus, Spieghel, Fludd, Bartholin, Vesling, de Graaf, and others showed sections of various parts of the body, such as the brain, eye, and sexual organs. In the first half of the eighteenth century many anatomists gave illustrations of sections of various parts of the body, yet they scarcely excelled those given by the anatomists of the preceding century. It should be said, however, that Haller's pictures of longitudinal sections of the brain show some details beyond those previously shown. In the latter half of the century much progress was made. S. Soemmering worked out and carefully illustrated the structures observed in the median sagittal section of the brain. This work was soon followed by that of Vieq d'Azyr, who represented various sections of the brain in some detail. The surgeons likewise used sections to a very considerable extent. Camper worked out and engraved an excellent picture of a longitudinal section of the pelvis. Scarpa illustrated the operation of lithotomy by means of sections through the pelvis.

The preceding suffices to show that the anatomists of the sixteenth, seventeenth and eighteenth centuries frequently employed sections to supplement their dissections. One of the obstacles which precluded the more extensive use of sections was the lack of a method which would harden the bodies or hold the parts *in situ*.

In the early part of the past century De Riemer, a Dutch anatomist, gave demonstrations of transverse sections of frozen bodies, and later published an atlas showing, as he states, "the exact position of the internal parts of the body in relation to their mutual positions and their contact with the walls of the various cavities." That this method of freezing the body to hold the parts in position was a decided advance beyond the methods previously employed, is indicated by his own words, which read as follows: "Considering that the position and the condition of the internal parts of the human body can be demonstrated in a more exact manner by means of freezing than by ordinary anatomy effected with all the talent possible, I have made several sections and the results surpass all my expectations. Stimulated by the advantage that medicine and surgery may obtain from this method, which can be effected so exactly, I have resolved to give a more useful and more general exposition of this kind of work by the publication of several illustrations."

A few years later von Froriep used sections in the study of the arm, leg and pelvis. Von Froriep was so impressed by the new view of the relation of parts that he states: "It is necessary for one to feel his way, as it were, among the parts." G. Soemmering, Rosenmueller, Lizars, Cloquet, Mascagni, and others frequently used sections in their studies. It is probable that the freezing method employed by De Riemer was not widely known, since Pirogoff states that the brothers Weber, as late as 1836, employed gypsum to retain the parts of the body *in situ*. Braune, however, in the first edition of his work (1872) gives E. Weber the credit of being the first anatomist to employ the freezing method.

Huschke, in 1844 published ten pictures of transverse sections through the neck, thorax, abdomen and pelvis of the cadaver of a girl eighteen months old, and was so pleased by the beauty and usefulness of these sections that he says: "In case these pictures meet with favor, I shall later undertake a comprehensive study of the adult male and female body by means of transverse and longitudinal sections."

Some years later (1852-59) the great Russian

anatomist and surgeon, Nicolas Pirogoff, produced a monumental work entitled: "Anatomie topographique, sectionibus per corpus humanum congelatum, triplici directione ductis illustrata." This work consists of five volumes—an octavo containing seven hundred and ninety-six pages of descriptive matter and four imperial folios containing two hundred and thirteen plates. The first volume of plates represents life-size sections of the head taken for the most part in transverse planes. The second volume of plates is entitled "Sectiones transverse cavi thoracis," but it also contains a number of sagittal sections. The third volume is entitled "Sectiones transverse cavi abdominis"; this volume also contains a number of sagittal and frontal sections of both sexes. The fourth volume is entitled "Sectiones per extremitates et per articulos extremitatis superioris, inferiorisque triplici directione ductae." It is quite evident from Pirogoff's introduction that, although the freezing method had been used for half a century previous, he was entirely unaware of the fact and credited himself with an independent discovery. He states: "Nobody before me, as far as I know, has ever proposed or employed a method by which the human body could be so solidified by freezing that it could be cut like wood into thin sections." Professor His says that "the work of Pirogoff represents an entire anatomical collection, and through him the science of anatomy was enriched by an abundance of new views, which are of special value to the clinician."

Soon after the appearance of the first part of Pirogoff's work, Le Gendre (1858) published a work entitled "Anatomie Chirurgicale Homolographique." This work, published in folio, contains twenty-five plates representing natural size sections taken in horizontal, sagittal, and oblique planes from various portions of the body. The frontispiece serves as a key figure to show the various planes of the sections. A brief text accompanies the plates. The drawings were made by the author, and show but little detail.

The following extracts are taken from the author's introduction: "The first impulse was given to this kind of work in France and abroad when the anatomists and the surgeons published complete works upon this new branch of anatomy. This alliance of anatomy and surgery is one of the most excellent methods of studying the human body. But the application of this idea, in the description of different regions of the body, is carried out by the authors with numerous divergences. Some have described the organs layer by layer as they presented themselves; others, in considering the same regions have described successively the aponeuroses, the muscles, the vessels and the nerves, and

have then dwelt upon the surgical importance of the anatomical relations. There is wanting in these works a study of the ensemble of the organs of each region. Delpeau, in his 'Anatomie Chirurgicale,' after having emphasized these different methods and recognized that each has its advantages, admits that in order to render this study complete there should be added a transverse section of each region. Desoult was the first to announce this idea for the extremities. Portal later applied it to the organs of the splanchnic cavities. Chaussier and Beclaire say that the operator is only on a secure basis when he forces his instrument through the body with that surety which he would have if all the parts of the body were transparent and he could follow its pathway with the eye."

Le Gendre speaks of the method of enveloping the parts in gypsum employed by Weber and Arnold, the method of hardening in alcohol employed by Kohrausch, and the method of decalcifying the entire pelvis by weak nitric acid, and adds: "These methods are still insufficient to give to the organs the rigidity necessary to keep the parts from being disturbed in preparing them. It is by freezing cadavers that we can preserve the organs, their respective relations, and their exact form. This method permits making sections of various parts of the body and at levels perfectly determined. The examination of these plane sections gives the most exact appreciation of the situation, of the form, and of the relations of the organs; likewise the distances which instruments have to penetrate in operations. Any dissection whatever which isolates the organs, disarranges them so that they lie one against the other, or shows areas of contact which do not exist, since in nature the organs are always inclosed in a cellular tissue. In the most modern works on surgical anatomy where horizontal sections have been represented—e. g., of the extremities, neck, etc.—the muscles are shown enveloped by a perfectly distinct aponeurotic sheath. The ordinary dissection removes all the cellular tissue which exists between the aponeurotic sheaths. It is precisely the knowledge of these sheaths and the disposition of the intermediate cellular tissue of the organs which interest the surgeon. It is in these spaces that tumors and abscesses originate, and it is important to know well their precise seat, their extension, and their connections with the neighboring parts, in order to judge of the pathways that they may follow. I attach the greatest importance to the representations of a surgical region in its natural condition. The operator can then without any effort glance upon the plate, judge of the extent of the parts that he will be obliged to traverse, and see

the relations of the organs he has to encounter; in a word, he can study the different phases of the operation as if he had, under his eyes, this region prepared upon the cadaver."

Braune, in 1872, published a splendid atlas entitled "Topographisch-anatomischer Atlas. Nach Durchschnitten an gefrorenen Cadavern." The first part of Braune's atlas appeared, according to His, in 1867, and contained illustrations of the sagittal sections of male and female bodies; these illustrations have since become classics. The work, containing sections taken in three planes, was completed in 1872. The text gives a very careful description of the relations of organs and a critical discussion of the work of preceding authors, partaking in many places, as His has well said, of the character of special monographs. So well was the work received by the clinicians that a second edition was published in 1875. A photographic reproduction in 1875 made the work more accessible for clinicians and students. This edition was translated into English by E. Belamy in 1877. Shortly after the appearance of this second edition Henke called attention to the work and emphasized the importance of making reconstructions from the sections, as His had done in his embryological studies. To illustrate how sections could be utilized best in the study of topographical anatomy, Henke reconstructed the heart and projected its contour on the thoracic wall. In speaking of this work Henke says: "I have given an illustration only of how these sections, and the questions involved, must be handled, according to my mind, if anything is to come from them." The third edition of Braune's atlas appeared in 1888. In the introduction to this edition, Braune refers to the suggestions made by Henke regarding reconstructions and agrees that such would be of great value, but states that the sections must be thinner and the parts must be held *in situ*.

The work of Braune is less extensive but more detailed and accurate than that of Pirogoff. His says: "In the selection of material and the detailed working out of the same, Braune goes decidedly farther than Pirogoff." The superiority of Braune's work is due largely to his improvements in technic. He invented a freezing mixture and devised a method of obtaining exact drawings. This method consisted of freezing a thin layer of water over the surface of the section, placing a transparent paper on the thin layer of ice, and tracing on this paper the outlines of the underlying structures. It was also claimed by His that Braune was the first to devise a method of preserving frozen sections by allowing them to thaw out in strong alcohol. It is probable, however, that the method of thawing in alcohol was

invented by Rüdinger, as stated by von Kupffer, and later accepted by His. Braune worked with great diligence and care. His attitude is well expressed in the following words: "I place special emphasis upon careful details in anatomical drawings, and I cannot consider many of the schematic anatomical sketches as accurate. When the drawings concern such an elaborate mechanism as the human body, every line must be true to nature and copied with the greatest care. The most exact technic is just good enough to do justice in anatomical illustrating. It will give me only pleasure if some one is able to produce pictures which show greater care and better methods than those which I offer."

In 1873 the first part of Rüdinger's "Topographisch-chirurgische Anatomie des Menschen" appeared, the second part in 1874-75, the third part in 1878, the supplemental part in 1879. The entire work contains seven hundred and twenty-one pages of text, together with one hundred and eighty-three illustrations. There are seventy-three illustrations of frozen sections of the adult and newborn, taken in the three principal planes. The illustrations which are photographic reproductions are most excellent, but the structures are not worked out in anything like the detail shown in Braune's work. In all the illustrations of sections, preceding the supplemental part, the structures bear numerals which in many cases are found only after a tedious search. In the supplemental part a great improvement is made in that the structures are designated by leaders which bear numerals. The purpose of the work, as stated in the author's preface, is "to present the individual structures, in the various regions of the body, in comprehensive groups, thus making it of direct value in practical medicine. Not only for medicine, but also for all the phases of science and art in which anatomy takes a prominent place, does this specialized anatomical knowledge reach its true worth, both by giving a deeper insight into the topographical relations of the organs, and by enabling one to carry over from the cadaver to the living body the total picture thus obtained."

Thomas Dwight in 1881 published a small volume entitled "Frozen Sections of a Child." This was the first attempt in this country to emphasize the importance of studying gross anatomy by means of serial sections. The work includes an explanatory text and twenty-five illustrations of serial transverse sections through the trunk of a three-year-old girl. The work, although lacking in details, should have stimulated other American anatomists to adopt this method of studying and teaching gross anatomy. Professor Dwight realized the importance of this method since he says: "Believing, as I do, that

frozen sections will play an important part in the anatomical teaching of the future, I shall say nothing of their advantages, which speak for themselves."

Symington, a few years later (1887), published a work entitled "The Topographical Anatomy of the Child." The work is based on a study of frozen sections and contains fourteen life-size colored plates, with a brief explanatory text. The work is more comprehensive and detailed than that of Dwight, but is lacking in all the finer details. One decided advance beyond that of previous workers is the introduction of accurate key figures showing the lines along which the sections were taken. The method adopted in the preparation of these key figures was as follows: "Before the bodies were frozen they were measured, and a life-size outline drawing was made of the anterior aspect of each. Upon these drawings lines were placed indicating the position of the various sections. After the sections were traced and the slabs hardened in spirit, the reconstruction of the figures was accomplished by first marking the position of the viscera, etc., in the plane of each section, and then ascertaining, by dissection of the slabs, the relation of the parts in the intervals between the various sections. This process of, as it were, building up the body again is a somewhat tedious one, but it greatly increases the value of any series of sections, for it can be accomplished with great accuracy, and it enables one to realize the position and relations of the various parts much better than plates of sections only."

The last attempt to produce an exhaustive work based on a study of frozen sections was made by Macewen (1893), who published an "Atlas of Head Sections." This consists of seven series of sections: three series of coronal sections, two from the adult and one from the child; one series of sagittal sections from the adult; three series of transverse sections, two from the adult and one from the child. The text is restricted to very brief explanatory notes which accompany the sections. The work merits the distinction of being the first to show, in any detail, the skull and brain *in situ*. The illustrations are from copper plates made from photographs, and are as artistic as can be made from frozen sections, yet as in all other frozen sections, the saw has destroyed or obscured many of the finer details. Moreover, the sections are exceedingly variable in thickness, ranging from one-eighth inch to one inch; again, in the same series, some are reduced one-half, some two-thirds, and some three-fourths. In the coronal series some are viewed from the front and some from behind; in the sagittal, some from within and some from without; in the transverse, some from above

and some from below. These irregularities practically preclude any serial study. The atlas is intended primarily for the practitioner. The author says: "The surgeon who is about to perform an operation on the brain has in these cephalic sections a means of refreshing his memory regarding the position of the various structures he is about to encounter."

There has been a growing appreciation of the value of sections in the study of gross anatomy, but the technical difficulties are still serious obstacles. The freezing of bodies is not so easily accomplished in the southern latitudes. Very few anatomical laboratories are provided with the apparatus necessary for artificial refrigeration, and, accordingly, must depend on low winter temperatures. Braune emphasizes the natural advantages which Pirogoff possessed in this respect. Even when temperatures are such that natural refrigeration is satisfactory, the cutting of sections is attended with many difficulties. The sections must be cut in a very cold room. The saw must be chilled. The finest saw, moreover, tears away the minute structures and leaves a rough surface. The surface of the section must be brushed and washed and then placed in strong, cold alcohol. The thawing of the sections in the alcohol causes unequal shrinkage in different organs. Sections of frozen bodies are so unsatisfactory that various methods of polishing the surface have been devised—for example, the method of Tunis (1909), which consists, according to the author, "in polishing sawn sections, while still frozen hard, on a rapidly revolving wooden wheel wet with water and finely powdered pumice stone."

The introduction of formalin as a hardening fluid marked the beginning of a new epoch in the study of sectional anatomy. It was first used by Gerota (1895), who injected a five-per-cent aqueous solution of formalin and then froze and sectioned the body.

A very important advance was made by Terry (1900), who injected a solution made of equal parts of fifty-per-cent formalin and ninety-five-per-cent alcohol, and obtained excellent sections without freezing. The best sections, according to Terry, are obtained from material fixed as above and then thoroughly decalcified with ten-per-cent hydrochloric acid.

In the following year (1901) Jackson published a method which has since been used extensively. The method is simply the thorough injection of the blood vessels with a fifty-per-cent aqueous solution of formalin. Its points of superiority as stated by Jackson are as follows: "No freezing is necessary; the sections are made more easily and smoothly; and, finally, they do not thaw out and become loose

and flabby upon handling. This method is also superior to all embedding methods, since not only the surfaces of the sections, but also the structures between, are accessible for examination. In fact, it combines the advantages of dissection with those of plane sections."

The first work of any considerable importance based on formalin-hardened material was done by Sellheim in 1903. His results are published in a large folio consisting of forty life-size reproductions of sections of pelvises from females of different ages, taken in the three principal planes. The plates are well executed, but in the designations of structures little attention is given to nomenclature. There are eleven key figures in the text showing the lines along which the sections are cut. These figures are small, imperfect reconstructions made from the sections. None of the structures are designated in these key figures. The text is confined to brief explanatory notes of the key figures and plates. No attempt has been made to discuss the work of previous authors. The method employed was as follows: the entire pelvis was fixed in ten-per-cent formaldehyde solution. The fundus of the uterus was then fixed in position with fine silver wires and the pelvis placed in five- to ten-per-cent formaldehyde solution for three to six months. This was followed by "after-hardening" in increasing strengths of alcohol, followed by alcohol-ether, then imbedded in celloidin, hardened in seventy- to eighty-per-cent alcohol for several days, then cut with a fine saw.

Potter (1905) was the first to take advantage of the method suggested by Jackson and to make an exhaustive study of the sections thus obtained. The results were published in a volume entitled "Topography of the Thorax and Abdomen." The structures are identified in greater detail than in any previous work. Its usefulness, however, is greatly impaired by the reduction of the plates and by the confused labeling of parts. Some structures are designated by names written on them; others by leaders running from them which cross and intersect in such a way that they are confusing; many are designated by numerals which can only be deciphered by means of a magnifying glass. The reconstructions which serve as key figures mark a decided advance beyond any work previously published, and give us a method by which a new and exact anatomy may be built.

A number of other works might have been mentioned with the above, especially those of Kohlrausch, Pansch, Brun, Hermann and Rüdell, and Chievitz. The purpose, however, of this historical sketch is not so much to review all the works on sectional anatomy as to indicate the main steps in the development of this method of anatomical study.

B. The Present Work.—The inception of the present work dates back to 1902, when the senior author with Dr. Dean Lewis formulated plans for a "Cross-Section Anatomy," which were approved by Dr. Levellys F. Barker, then Director of the Anatomical Laboratories of the University of Chicago. Material was being selected when it was learned that Dr. Peter Potter, of the University of Missouri, had partially completed a similar work. Subsequent events brought both Dr. Potter and the senior author to St. Louis University, where, during the winter of 1904, Dr. Potter completed his "Topography of the Thorax and Abdomen." At this time the senior author suggested that the Anatomical Department of St. Louis University should undertake a more comprehensive study of the same character, and with this end in view the task was begun. After the work on the trunk was well under way, the entire project suffered interruption owing to Dr. Potter and Dr. H. D. Kistler retiring from the department to engage in the practice of medicine. The continuance of the work devolved upon the senior author, who later secured the cooperation of Dr. D. M. Schoemaker. The senior author, Dr. Schoemaker, and Mr. Tom Jones (artist) are responsible for the work, excepting that on the reconstructions of the viscera of ten negro subjects, which has been done by Dr. Peter Potter, and that on the anatomy of the female pelvis, by Dr. Carroll Smith.

Purpose.—The student, the anatomist, and the clinician have been kept in mind in preparing this volume.

The importance of the study of sectional anatomy for the medical student can scarcely be overestimated, either from the disciplinary or from the practical standpoint. The student is shown the way from dissection to construction, from the analytic to the synthetic. The mental pictures gained from a study of sections are easily carried over to the living body and thus form the immediate anatomical basis for practical work. The sectional method of studying gross anatomy has been given such emphasis in late years that the Council on Medical Education of the American Medical Association has recently recommended that it be a part of the anatomical work in all medical colleges.

It is hoped that this work may stimulate anatomists to record more abundant and more accurate data on the topography of organs in the adult; that the study be extended, on the one hand, to include fetal organs, and thus form a direct continuation of embryology; and, on the other hand, to include the study of the changes accompanying senility. Mall has well said: "Using serial sections in the study of anatomy is fully as valuable as dissecting the em-

bryo and making reconstructions are in the study of embryology."

A special effort has been made to furnish the clinician with a practical gross anatomy. In this effort we have kept in mind the following words from Henle: "The systematic anatomist must never forget that the common purpose of all anatomical studies is the orientation of the organs in the living body . . . diagnostic investigations as well as surgical procedures begin at the surface. The questions which the clinician demands that anatomy shall answer, have first of all the purpose, as it were, of making the body transparent."

The purpose of this anatomy, then, is to show the student the essential step between dissection and visualization; to suggest to the anatomist a basis for an exact anatomy and to furnish the clinician a gross anatomy in practical form.

Materials.—The material for the study of the trunk was selected from some fifty negro subjects which were sectioned for class use. This was the original material, and it was not then contemplated that the work would be extended to include the entire body. The material for the study of the head and neck was selected from a large number which had been sectioned for class and research work. A number of the heads were decalcified by various methods with the hope of finding some decalcifying agent which would neither shrink nor swell the brain, but finding none satisfactory, the head was sectioned with the saw and knife. The extremities were later selected from a large number, with a view of obtaining those which represented the average.

It is thus obvious that the serial sections are not from a single cadaver. The work comprises three, more or less, distinct parts, viz., head and neck, trunk, and extremities. It would, of course, have been preferable to have had an entire series from a single body. The difficulty, however, in obtaining an average body which is neither obese nor emaciated is known to all who have tried to obtain such a one. Rather than defer the work until such material was available, it has been put forth in its present form.

Methods.—The body should be placed supine and fifty-per-cent formalin injected either through the femoral or common carotid artery or both. The injecting should be done slowly. The amount of formalin injected varies from a minimal quantity of about one gallon to a maximal quantity of about three gallons, depending upon the size of the cadaver. In a few days the body is thoroughly hardened. If allowed to harden in the supine position it will be flattened on the supporting surfaces. This flattening may be overcome by floating the body in a large tank filled with three- to five-per-cent formalin.

It may also be overcome by frequent rolling or by suspending.

When the body is thoroughly hardened a study of the surface should be made and the topographical areas and landmarks outlined. Photographs of the body thus marked should be made, as should also radiographs of the skeletal structures. In selecting the planes in which sections are to be cut, one should keep in mind some fixed plane—e. g., that passing in a horizontal plane through "Reid's base line" may be used as a guide in cutting the sections of the head. The levels of the sections of the trunk may be selected with reference to the spinous processes, the intervertebral discs, or the bodies of the vertebrae. In the limbs it may be found advisable so to space the sections that certain ones pass through the joints.

The thickness of the sections is largely a matter of choice. No difficulty arises in making sections of the head or extremities 5 mm. in thickness, while those of the trunk need not exceed 1 cm. In marking the lines along which the sections are to be cut, considerable difficulty is frequently experienced. A frame large enough to admit the body is fastened across the end of the table, flush with it. The body is placed on the table, projecting the desired thickness beyond the edge of the frame. A straight edge provided with a blade marker is placed against the frame and rotated so as to mark the line of the section.

In handling the sections rubber gloves should always be worn to protect the hands. The sections should be cut with a long, keen-edged butcher's knife and a very sharp, thin metal worker's saw. Before cutting the succeeding section the loose parts are stitched to prevent displacement. After cutting as far as possible, the section should be slightly separated so that the saw does not roughen the surface cut by the knife. As each section is cut it is placed on a piece of cloth, washed in running water, and finally stored in a moist chamber or in weak formalin in any convenient receptacles, such as glass jars, zinc-lined or galvanized iron boxes. If galvanized boxes are used it is advantageous to paint them once or twice during the year with asphalt paint in order to prevent corroding.

The sections are taken from the storage boxes or jars, and immersed in water or a weak solution of ammonia to free them from the excessive formalin. A thin pane of glass, large enough to cover the surface of the section, is placed upon it. The underlying structures are traced on the glass with a fine pen in waterproof India ink. Having secured an accurate tracing of the section on the glass, the outlines thus obtained are then retraced on the drawing paper, by placing the paper upon the inked surface

of the glass, while holding in front of a window or over an electric light. The tracing on drawing paper serves as the basis for the completed drawing.

The projections are made from a series of measurements taken on the surfaces of the sections. The method is as follows: before the body to be reconstructed is sectioned, two perpendicular lines are drawn upon the surface of it from top to bottom, the one in front and the other behind, in the same parallel and directly opposite, so that when viewed from either side in the plane of the projection it presents two equal parts. These lines, which will henceforth be termed "vertical bisectors," are plainly marked or cut upon the skin. The location of these lines should be determined previously by their several anatomical guide points. If, for instance, the projection is to be a front view of the trunk, the anterior vertical bisector should pass through the middle of the suprasternal notch and symphysis pubis, while the posterior being directly opposite would pass through the spinous processes. When a side or profile view is taken the vertical bisectors would be in the axillary line on either side, etc.

A plate of glass large enough to cover the section is ruled with parallel lines 1 cm. apart. The central, which is termed the "zero line," is made heavier since this is the line from which all the measurements are made. The plate is now reversed and the lines numbered consecutively both to the right and the left of the zero line. The plate is reversed in order that the lines may be in direct contact with the surface of the section upon which it is laid, thus avoiding slight errors caused by the thickness of the glass.

Upon a sheet of cross-section millimeter paper, which must be large enough to contain the entire projection, a perpendicular line is drawn from top to bottom, dividing it into halves which will correspond to the right and left halves of the body to be reconstructed—i. e., as viewed by the reconstructor. This is termed the "central line." It will correspond to the vertical bisectors, which, when seen in the plane of projection, would coincide. The sections are now carefully measured, and their several thicknesses indicated in their serial order by horizontal lines crossing the millimeter paper. These lines represent the upper surfaces of the sections, and are only horizontal when the cut is exactly transverse. Where a section is cut obliquely, the line indicating the upper surface of that section must have a corresponding obliquity.

The ruled glass is placed upon the surface of the first section with the zero line in direct contact with the vertical bisectors on the skin, where it is cut or marked at opposite sides. Care should be taken not

to move the glass so placed while the readings are made, and to keep the eye immediately above the structure being measured. The measurements are made by reading in centimeters and decimals thereof from the zero line to the extreme inner and outer edges of the structure measured—i. e., the point nearest to the zero line and the one farthest away. This applies when the structure lies entirely to the right or the left of the line. Should it cross the line, as in the case of the liver, only the extreme lateral point on either side is measured.

The measurements are now carried over to the millimeter paper, which has been ruled as before described, and indicated by dots on the line representing the upper surface of the section. Thus if the body outline is to be projected and the reading in a given section be 14 cm. on the right and 14 cm. on the left of the zero line, these distances are indicated by dots 14 cm. to the right and 14 cm. to the left of the central line. The dots are placed on the horizontal line representing the surface of the section measured. This process is repeated in serial order for each section. The dots are then connected by lines, which indicate the contour of the body. The same method is employed to obtain the outline of each structure. With the exception of the body outline, this can only be determined by dissection if exactness be required.

It is well to retrace in different colored inks the outlines of the structures so obtained, since the pencil lines become confusing after several structures have been outlined. When the projection is finished it is transferred to the drawing paper by means of carbon paper or traced by transmitted light and the outlines of the various structures filled with washes of different colors.

While the above method has been described as applying to transverse sections, it is equally applicable to reconstructions from sections in other planes. It is only necessary to change the vertical bisectors at right angles to the line of section and to rule the millimeter paper accordingly. Thus if the sections be sagittal, horizontal bisectors are established, and the central line of the millimeter paper becomes horizontal, while the surfaces of the sections are indicated by perpendicular lines. The procedure after this is the same as described for transverse sections.

It is also possible to make a reconstruction from the transverse sections which would show the organs as they would appear in any given coronal or sagittal section. The method follows: Vertical bisectors are established in the usual manner, anteriorly and posteriorly if the reconstruction is to be of a coronal section, and in the axillary plane on either side for

a sagittal section. The section to be reconstructed is now marked or cut upon the body by a vertical line. Upon the glass plate (ruled as before described) an additional line must now be drawn exactly at right angles to the others. This is termed "cross-line" and corresponds to the line of section to be reconstructed. The glass is placed upon the section with this line in direct contact on one side with the line of section marked on the body, and the zero line in contact with the vertical bisectors in the usual manner. The millimeter paper is prepared as before described. The readings are made in the usual manner, but only where the structure comes in contact with the cross line on the glass plate. It should be understood that vertical bisectors are not necessary in making reconstructions. Any two lines can be used, provided they are parallel and on opposite sides as viewed in the plane of projection.

It should be remembered that the projection does not represent the structures exactly as they would appear were the body transparent, but rather as if each structure were viewed separately, with the eye directly in front of and on a plane with it. The reconstruction is a map, showing only the exact profile and position of a given structure in a given plane.

Illustrations.—The illustrations consist of those made from the upper surfaces of the serial sections and the projections made from them. The projections serve as key figures, and precede the serial sections in each subdivision of the work. The illustrations of sections are so arranged that the posterior or dorsal surface is nearer the observer. This is obviously incorrect from the standpoints of embryology and comparative anatomy, and valid objections, as pointed out by Jackson (1901), could be offered. This anatomy, however, is primarily for the clinician, and the clinical position has been adopted; moreover, this is the position generally adopted by previous workers.

The key figures of the head and neck and that of the female pelvis are about four-fifths natural size, those of the trunk and extremities are about two-fifths natural size. The sections are uniformly four-fifths natural size. It is thus obvious that the key figures and sections of the head and neck and of the female pelvis are approximately of equal dimensions. The key figures of the trunk and extremities are about one-half the diameter of the sections.

The transverse lines and affixed numerals on the key figures indicate the positions and serial numbers of the sections.

It will be noted that often a single leader carries

two or more names. The order of the names in general indicates the order in which the structures at the ends of the leaders are to be read. In nearly all cases this order is from left to right.

Nomenclature.—The "Nomina Anatomica," adopted by the Anatomical Society at Basle in 1895, is commonly designated by the abbreviation "BNA." There is no doubt but what this precise and brief nomenclature will in a few years completely replace the indefinite extensive and mixed terms so frequently found in the anatomies of the past decade. Were this work intended primarily for the anatomist the BNA would be used exclusively. Since it is intended largely for the clinician, it has been advised that the mixed terms also be given. With this end in view, the following method has been adopted. The structures shown in the drawings are uniformly designated by the BNA terms, except when otherwise specified. The descriptive notes contain the common or mixed terms in all cases where they differ widely from those adopted in the BNA. These terms bear numerals citing the corresponding BNA terms on the drawings. In case the reader is in doubt regarding the common equivalent of any of the BNA terms he should refer to the index, where he will find these equivalents given.

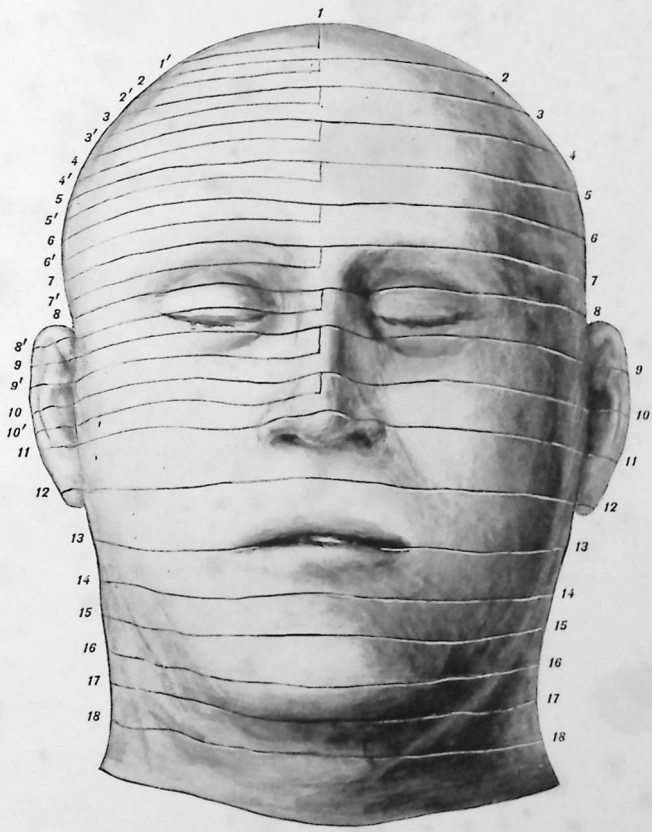
Text.—The text is little more than an explanation of drawings. Its purposes are: first, to precisely define the level of the section with reference to the principal structures; second, to give some information concerning the structures which begin or end in the body of the section or those which lie wholly within the same. Beyond these points an effort has been made to abbreviate rather than to elaborate the text. The interpretations of the relations of organs can no more be complete when studied in sections alone than when studied in dissections alone. The two methods are mutually dependent each upon the other. The best results will be obtained only when constant reference is made to the ordinary descriptive anatomies.

Acknowledgments.—The authors wish to acknowledge their deep obligation to Dr. C. M. Jackson for making a careful search throughout the entire work for errors in the identification of structures and to Mr. A. M. Schwitalla, S.J., for his efficient aid in the final revision of the labels and text. They would express their indebtedness to Dr. E. P. Lyon, Dr. R. L. Thompson, Dr. H. W. Loeb and Dr. M. G. Seelig for many valuable suggestions. They wish to thank Dr. J. M. Keller, Rev. C. H. Keller, Mr. M. W. Schmidt and Miss Ethel Spero for assistance given in the preparation of the work.

Key-figure I

Key-figure I

This Key-figure represents a front view of the head and the greater portion of the neck. The lines 2-18 indicate the levels at which the principal sections were cut, while those on the opposite side, 1'-10', indicate the levels at which the principal sections were bisected. This was done to show the structures in the brain at an additional number of levels. In spacing the sections before cutting an effort was made so to orient them with reference to "Reid's base line" that the upper surface of Section 10 would be in the plane indicated by this line. It should be recalled that Reid's base line is a line drawn backward from the lower margin of the orbit to the center of the external auditory meatus. It will be observed by glancing at Key-figure II that the upper surface of Section 10 is at this level. This line is nearly the same as the "horizontal line" of the German authors, which passes through the lower margin of the orbit and the upper margin of the external auditory meatus.

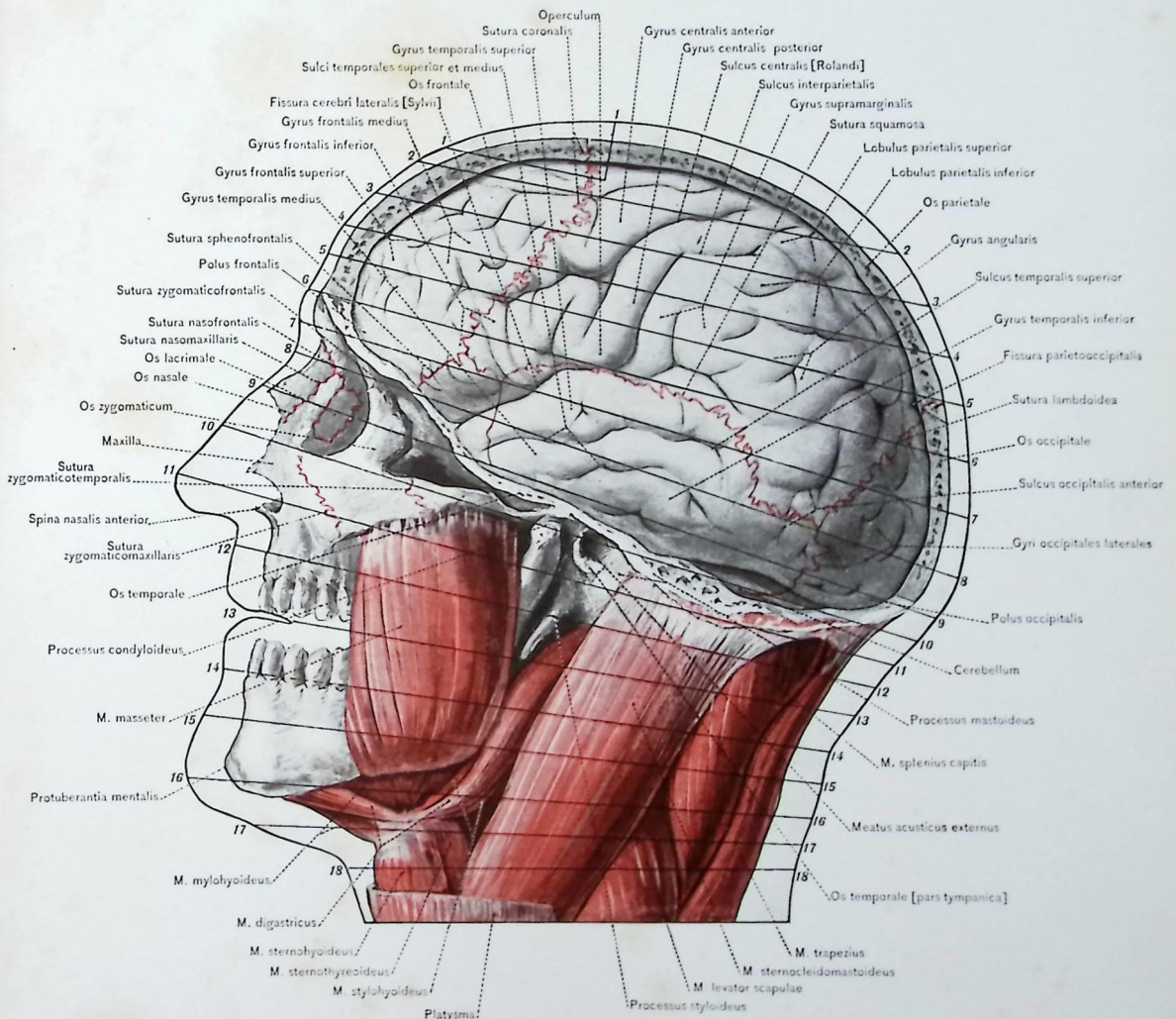


KEY-FIGURE I

Key-figure II

Key-figure II

This Key-figure represents a reconstructed side view of the head and greater portion of the neck, showing the levels of the sections from the left side, with reference to the convolutions and fissures, the bones of the face, and principal muscles. These levels are indicated by the transverse lines 2-18. The left half of the skull has been removed as far as the upper margin of the orbit and the external auditory meatus. The location of the sutures in the removed portion of the skull have been represented by red lines in order to show their relation to the principal convolutions and fissures. The platysma has been but partially reconstructed, since it would obscure the underlying muscles.



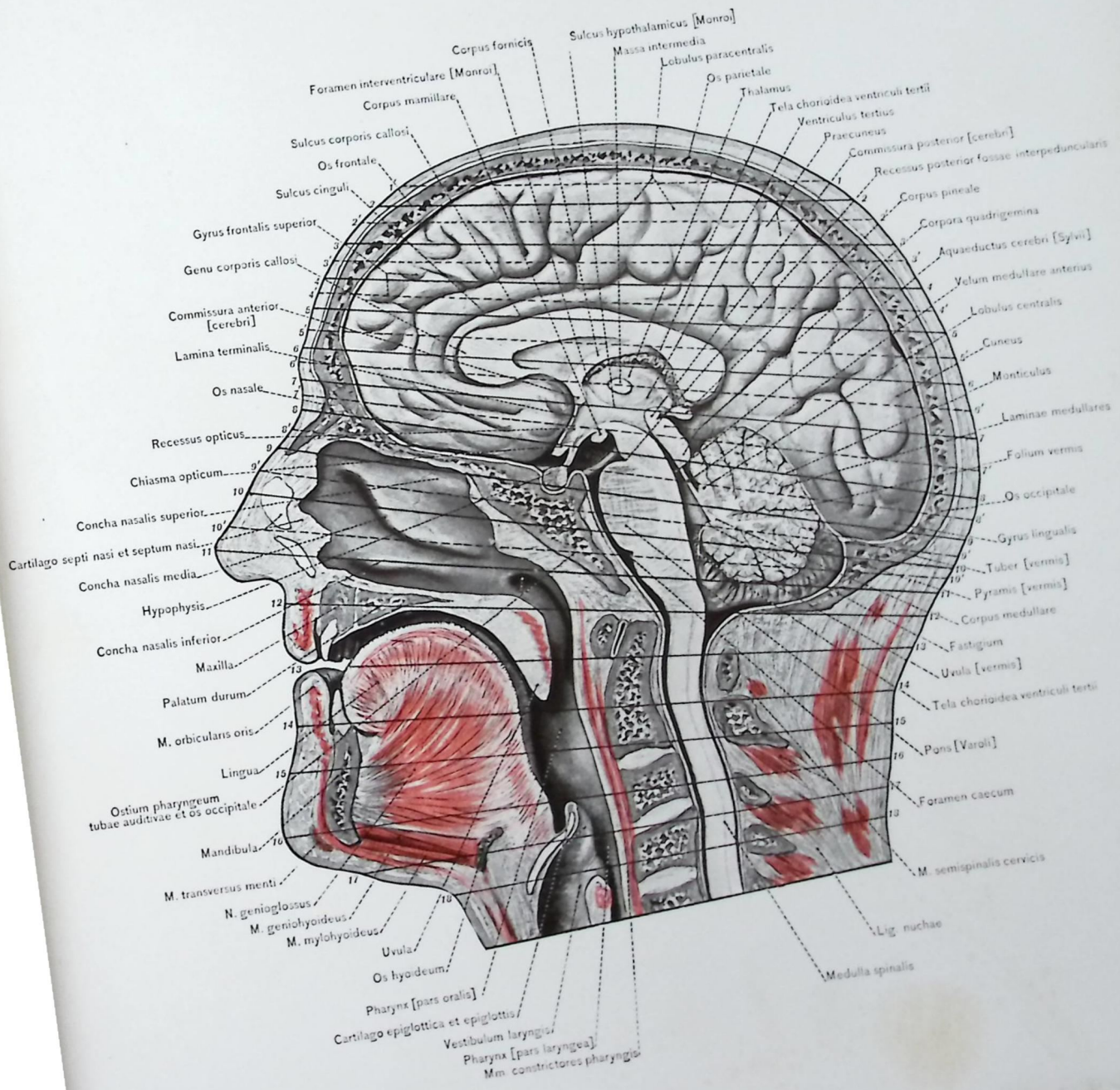
KEY-FIGURE II

Key-figure III

Key-figure III

This Key-figure represents a mesial sagittal section of the head and greater portion of the neck. It is largely a reconstruction from the sections, but some details, especially of the brain, have been obtained by cutting the sections in the mesial sagittal plane, superimposing them, and then confirming and correcting the reconstruction. The solid lines 2-18 indicate the lines of the principal sections, while the broken lines 1'-10' indicate the levels of the horizontally bisected sections. The solid lines indicate the levels on the left side, while the broken lines show the levels of the sections on the right side. It should be stated that in this subject the sphenoidal sinuses are very small and bilaterally placed. Certain structures which are unlabeled need a word of explanation: the stalk of the infundibulum connects the hypophysis with the third ventricle; the oculomotor nerve is shown extending obliquely across the interpeduncular fossa; the tentorium cerebelli, extending over the cerebellum, is partially shown. The gyrus lingualis in this subject extends to the region indicated. The venous sinuses of the dura are not shown.

Note.—The leader labeled "Recessus opticus" ends slightly above the optic recess.



KEY-FIGURE III

Section 1

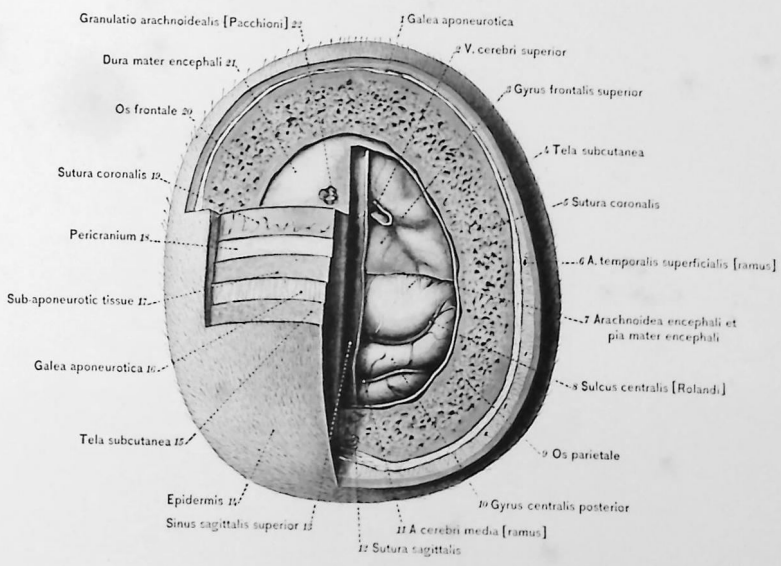
Section 1

This section is cut in the plane indicated in Key-figures I, II, III.

On the left anteriorly the upper portion of the scalp and skull have been removed, exposing the dura mater (21) and one of the underlying Pacchionian bodies (22). The layers of the scalp are shown in the following order: outer surface of epidermis (14), superficial fascia or stratum subcutaneum (15), the epicranial aponeurosis (16) joining the frontal and occipital muscles. Beneath the epicranial aponeurosis is a comparatively thin layer of sub-aponeurotic connective tissue (17), followed by the periosteal layer of the bone, the so-called pericranium (18).

On the right side the upper portion of the frontal (20) and parietal (9) bones and the dura mater (21) have been excised, exposing the upper surface of the brain. The pia mater (7) and the overlying arachnoid mater are intact over the anterior portion. One of the cerebral veins (2) is shown as it enters the superior longitudinal sinus (13). One small ascending branch of the frontal artery is shown anteriorly on either side of the median line. The pre-central gyrus lying just in front of the fissure of Rolando (8) is not clearly defined at this level, and has not been labeled.

Note—The BNA includes the m. frontalis, m. occipitalis, galea aponeurotica and the m. procerus under the generic term m. epicranicus. The English term sub-aponeurotic tissue (17) has been used since there is no equivalent term in the BNA.



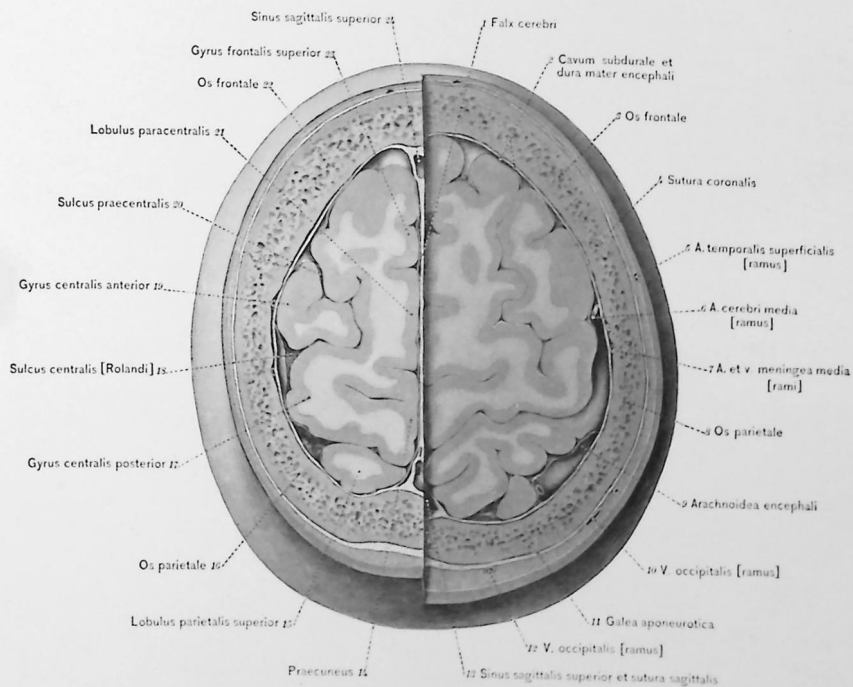
SECTION I

Section 2

Section 2

This and the succeeding sections, including No. 10, have been bisected in a horizontal plane on the right side, as previously stated. In the Key-figures the lower half of the section is designated by a prime ('). The section is cut at the levels indicated by the numerals 2 and 2' in Key-figures I, II, III.

The frontal (3) and the parietal (8) bones appear to be very thick, owing to the obliquity of the section. The branches of a number of blood vessels are cut at this level. Those lying in the scalp anteriorly are branches of the frontal artery. On the right there is a branch of the superficial temporal artery (5). Posteriorly are two branches of the occipital vein (10, 12) and a small branch of the occipital artery. Branches of the anterior, middle (6), and posterior cerebral arteries are shown in the sulci of the brain. Branches of the middle meningeal artery and vein (7) are shown on both sides, but are labeled on the right side only. The cerebral hemispheres are separated by the great longitudinal fissure in which lies the falx (1). The cortical layer of the brain at this level is apparently exceedingly variable in thickness. It should be kept in mind that this appearance is due largely to the obliquity of the section. The section may pass through one of the surfaces of a given convolution—e. g., gyrus centralis anterior (19) in such a manner that it is apparently cut off; but such is not the case, since it is continuous above or below. A portion of the gray matter may appear to be isolated—e. g., the small oval area on the right; this in reality is the cortical substance at the bottom of a fissure (sulcus) which has penetrated the hemisphere from above.



SECTION 2

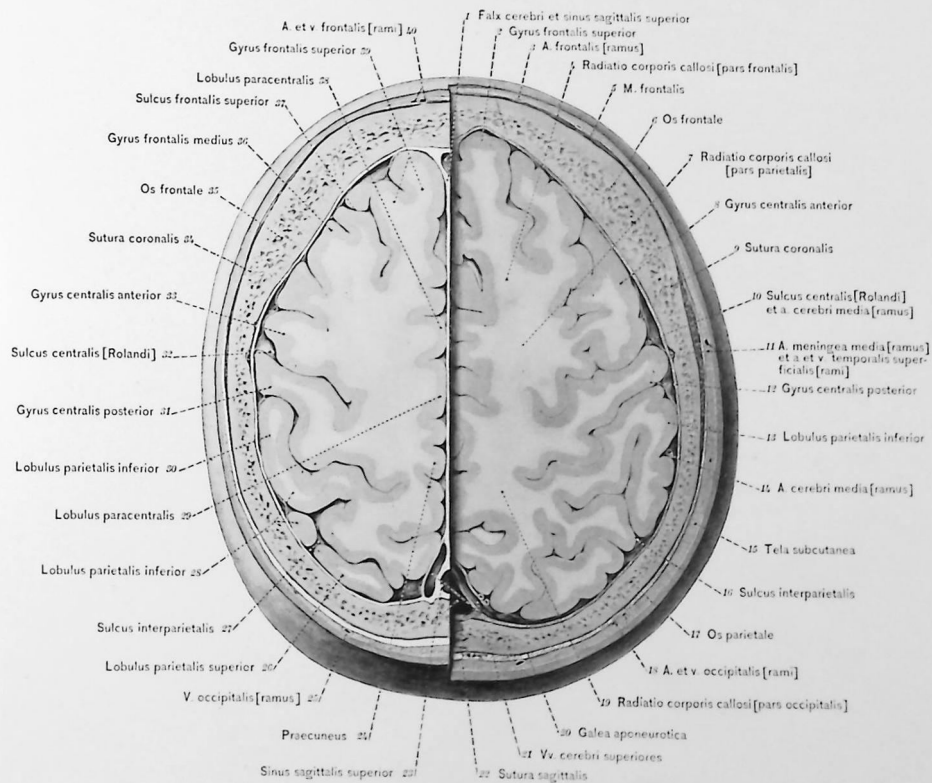
Section 3

Section 3

The levels of the halves of this section are indicated by the lines 3 and 3' in Key-figures I, II, III.

The coronal sutures (9, 34) and the sagittal suture (22) are shown. The frontal (5) and the temporal muscles are distinct. The branches of the blood vessels show little change from the positions indicated in the preceding section. Posteriorly, near the median line, two of the large superior cerebral veins (21) are cut. The superior longitudinal sinus (1, 23) is cut both anteriorly and posteriorly.

The right side of this section is cut deep enough to show the radiating fibers of the corpus callosum (4, 7, 19) and the converging fibers of the corona radiata which intersect them.



SECTION 3

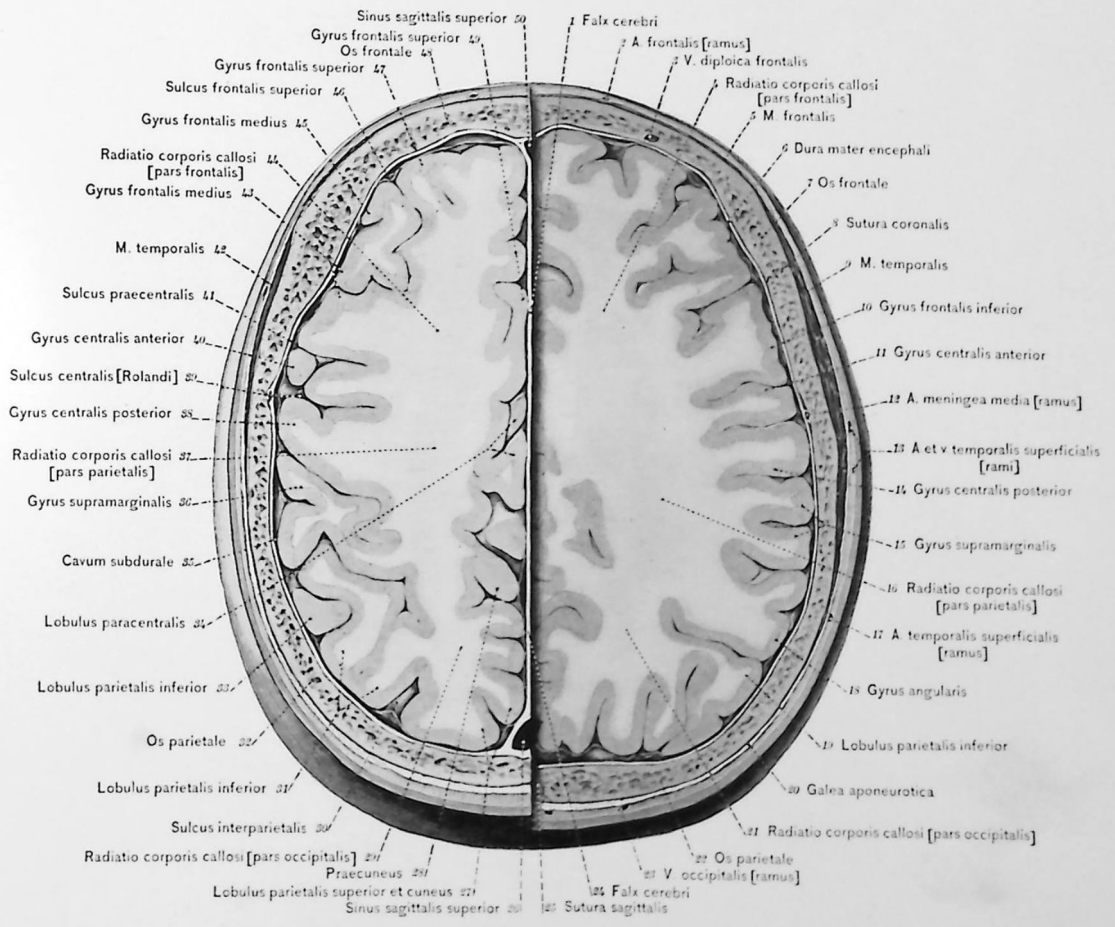
Section 4

Section 4

The levels of the halves of this section are indicated by the lines 4 and 4' in Key-figures I, II, III.

The obliquity of the plane of section to the scalp and skull and dura mater still give to these structures an appearance of excessive thickness. The muscles are more prominent than in the preceding section, this being especially true of the temporal (9). One of the diploic veins (3) is shown in the frontal bone. The blood vessels otherwise differ but little from the condition previously described.

The right half of the section is cut just above the trunk of the corpus callosum, as will be apparent by glancing at Key-figure III. At this point a word on the membranes, or meninges, may be helpful. The dura mater (6), or outer membrane, is closely applied to the inner surface of the skull. Just within it is the subdural space (35). The arachnoid, or middle membrane, is shown in several places as it stretches across from one convolution to another. The pia mater, or internal membrane, is closely applied to the entire surface of the brain, covering not only the convolutions, but also extending into the fissures. This membrane is so delicate that it has not been indicated in the drawings.



SECTION 4

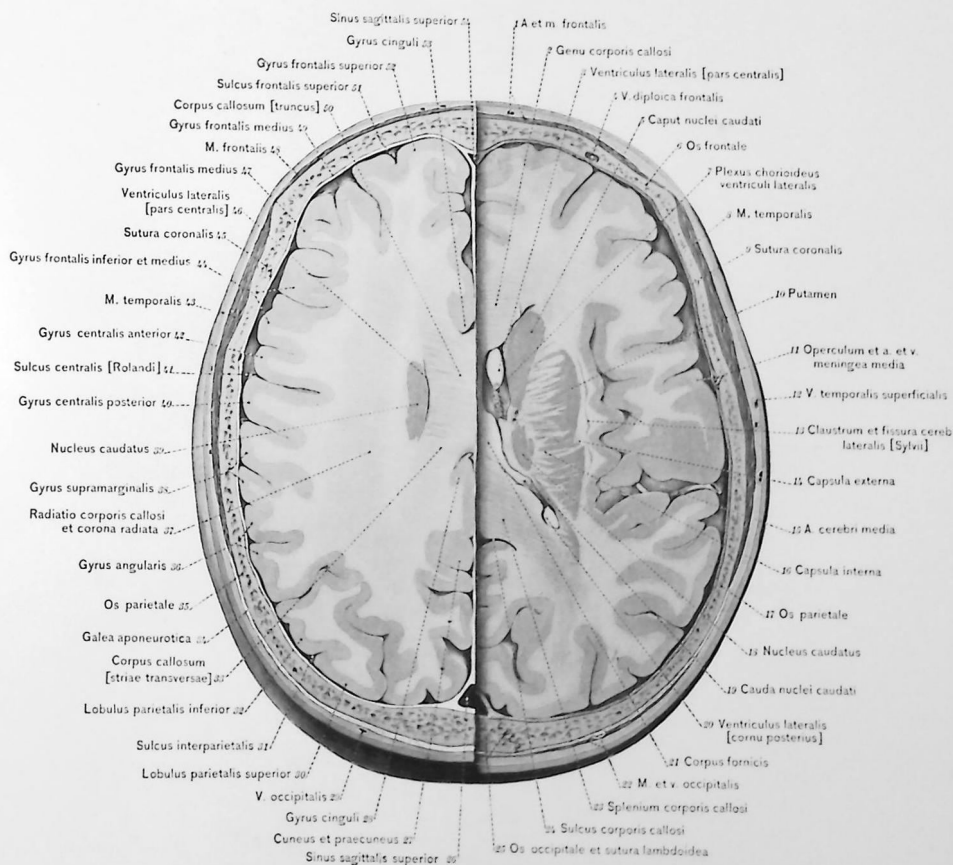
Section 5

Section 5

The levels of the halves of this section are indicated by the lines 5 and 5' in Key-figures I, II, III.

The left half of the section passes about 1.5 cm. above the glabella and about 2 mm. above the superior margin of the occipital bone. The frontal (48) and temporal (8, 43) muscles are more prominent. The blood vessels are essentially as in Sections 2, 3 and 4. The inferior longitudinal sinus is so small at this level that it has not been indicated in the drawing. The trunk of the corpus callosum (50) shows plainly its transverse striations. Along the mesial margin of the corpus callosum a faint white line represents a longitudinal band of fibers (*stria longitudinalis medialis*). The falx does not extend across the corpus callosum, as might be inferred from the fact that it appears to be continuous with the band of longitudinal striations of the corpus callosum.

The right half of the section passes about 1 cm. above the glabella and through the upper margin of the occipital bone. It cuts the upper part of the central portion of the lateral ventricle (46), also the upper portion of the knee (2) and splenium (23) of the corpus callosum. It cuts the corpus striatum which is made up of the caudate (5, 18) and lenticular nuclei. The putamen (10) of the lenticular nucleus is shown, but the globus pallidus lies below this level. The body of the fornix (21) is shown near the median line, where it comes in contact with the body of the corpus callosum. One of the posterior pillars of the fornix (*crus fornicis*) is shown as it extends backward along the posterior horn (20) of the lateral ventricle. The fissure of Sylvius (13) appears as a long, tortuous fissure. Just within the fissure is the island of Reil (*insula*) containing a number of small gyri (*gyri breves insulæ*). Just outside the fissure is a wide zone, the operculum (11).



SECTION 5

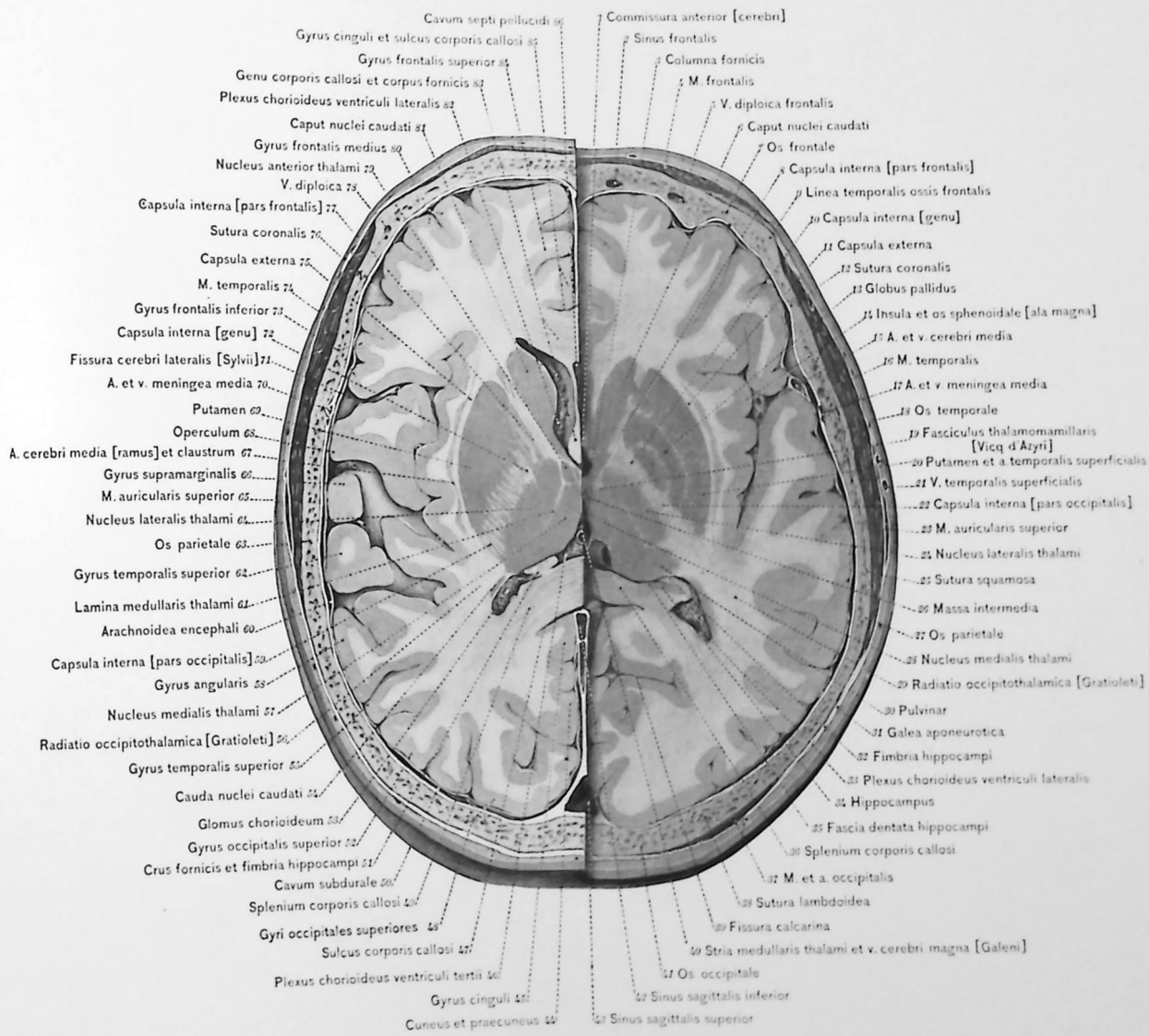
Section 6

Section 6

The levels of the halves of this section are indicated by the lines 6 and 6' in Key-figures I, II, III.

On the left side the section passes through the glabella and just above the upper margin of the temporal bone, through the middle of the knee (83) and splenium (49) of the corpus callosum, and through the body of the fornix (83). Just anterior to the body of the fornix a thin layer extends to the knee of the corpus callosum; this is the left lamina of the septum pellucidum; between it and the right lamina, which has been removed, is the fifth ventricle (86). Just posterior to the body of the fornix (83) is a deep groove connecting the lateral ventricle and the third ventricle. This groove is the lower half of the foramen of Monro. The three principal nuclear masses (57, 64, 79) which make up the optic thalamus are well defined, and are partially separated by the laminae medullares thalami (61). In the region indicated by 51 the posterior pillar of the fornix comes into relation with the fimbria of the hippocampus.

On the right the section passes at the upper margin of the greater wing of the sphenoid, and through the upper margin of the temporal bone. One of the frontal sinuses (2) is cut, but the corresponding one on the opposite side is not shown; it will be noted in the succeeding section that the frontal sinuses in this subject are much smaller than the average. The section passes through the lower portion of the knee and splenium (36) of the corpus callosum, and through the middle commissure (26), which connects the optic thalami. Just external to the middle commissure is the bundle of Vicq d'Azyr (19). The anterior commissure (1) lies partly in the lower surface of this section, but is more clearly defined in the next section below. In close proximity to the anterior commissure is a well-defined bundle of fibers—the pars tecta columnæ fornicis (3).



SECTION 6

Section 7

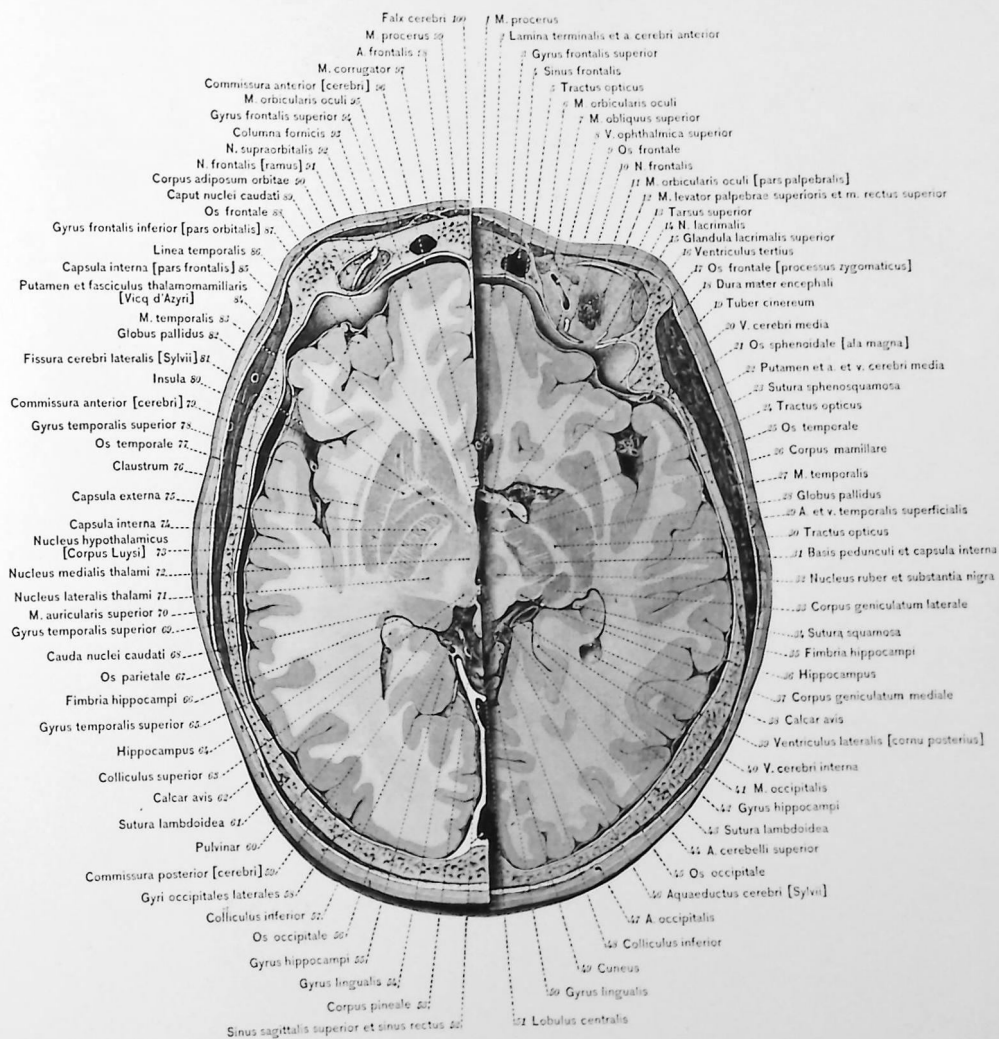
Section 7

The levels of the halves of this section are indicated by the lines 7 and 7' in Key-figures I, II, III.

The left half of the section passes just above the nasal bone and through the upper portion of the greater wing of the sphenoid. The left orbit is cut through its upper portion, exposing the supraorbital nerve (92) and a branch of the frontal nerve (91). In orienting the left half of the section it is well to recall that it passes through both the anterior (96) and the posterior (59) commissures. From Key-figure III the reader may infer that the section does not pass through the left superior quadrigeminal body (63). It should be recalled that the mesial section passes through the median groove which separates the quadrigeminal bodies. The trigonum habenulae lies in the lower surface of the section above, as does also the commissura habenularum. The pineal gland (53) is well developed in this subject. Its stalk is shown on the left as it curves outward to become continuous with the tania thalami and the stria medullaris. The optic thalamus shows the mesial (72) and lateral (71) nuclei, and the pulvinar (60). The mesial nucleus shows an inner ventral portion which is fairly distinct and which has been called the "ventral nucleus," although not recognized in the BNA. The lateral nucleus (71) extends backward beyond the mesial (72) and becomes continuous with the pulvinar (60). Just within the internal capsule (74) is a mass of gray matter, shaped like a biconvex lens, which is known as the corpus subthalamicum or body of Luys (73). The anterior commissure connecting the olfactory and temporal lobes on opposite sides of the brain is cut in two places (96, 79); the larger temporal portion is shown at 79.

On the right side the section passes through the upper end of the nasal bone, and immediately above the fronto-malar suture. The section also passes through the orbit just above the eyeball (bulbus oculi). The tendon and some fibers of the superior oblique muscle (7) are shown; its muscular portion is in close proximity to the trochlea, while its tendinous portion passes beneath the superior rectus muscle (12) to its insertion. The frontal nerve (10) passes into the section above. The lachrymal nerve (14) is continued in the section above to the lachrymal gland (15). The third ventricle shows a deep subdivided recess anteriorly. The anterior subdivision is the optic recess (recessus opticus) lying just behind the lamina terminalis (2). The posterior division, just in front of the end of leader 16, is the cavity of the infundibulum (recessus infundibuli). Posteriorly the third ventricle passes over into the aqueduct of Sylvius (46). The optic tract is shown at 24, 30. Posteriorly it divides into two limbs; the narrower internal limb passes over to the internal geniculate body (37); the shorter external limb passes to the external geniculate body (33). The reader must not infer that all the nerve fibers in the optic tract terminate in these ganglia. At this level the internal capsule (31) becomes continuous with the crista of the cerebral peduncle (basis pedunculi cerebri); just within is a dark-colored zone, the substantia nigra (32). Another important structure in the mid-brain at this level is the red nucleus (32). On the inner surface of the red nucleus is a bundle of nerve fibers which is called the fasciculus retroflexus [Meynerti]. The remainder of the mid-brain (mesencephalon) between the substantia nigra (32) and corpora quadrigemina is known as the tegmentum.

Note.—The m. corrugator (97) has been labeled following Spalteholz, Toldt and others, although not recognized in the BNA.



SECTION 7

Section 8

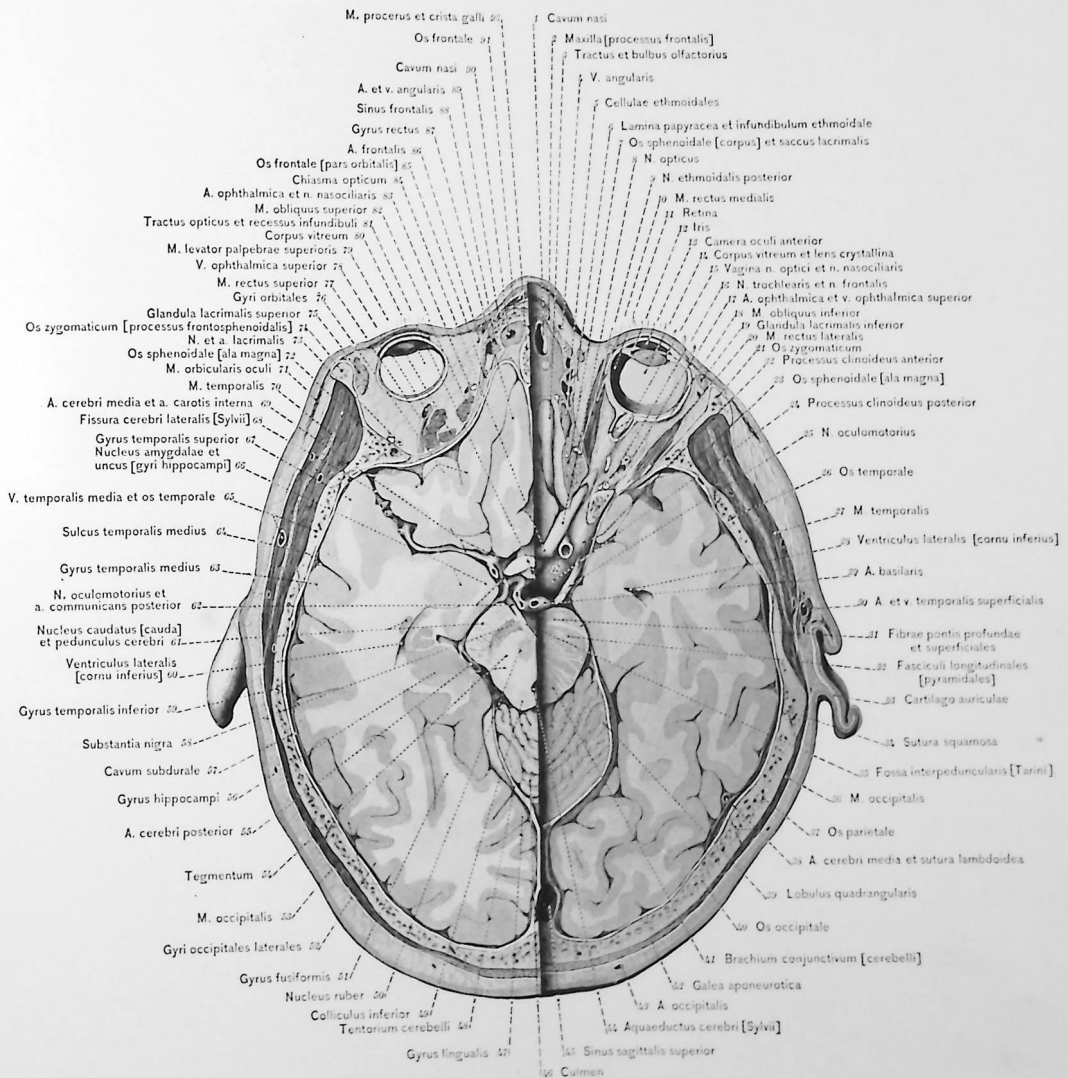
Section 8

The levels of the halves of this section are indicated by the lines 8 and 8' in Key-figures I, II, III.

On the left the section passes about 7 mm. below the upper margin of the nasal bone and just above the upper margin of the frontal process of the maxillary bone; through the squamous portion of the temporal and just above the external ear. The left orbit is cut through its upper third and through the eyeball about 2 mm. above the superior margin of the lens. The superior oblique muscle (82) extends into the body of the next section above, where it passes through the trochlea, and then to its insertion in the sclera. The superior levator palpebral muscle is at this level mesial to the rectus; it extends into the section above to its insertion. The superior rectus (77) likewise passes anteriorly into the body of the section above, piercing the capsule of Tenon, and is inserted in the sclera. The ophthalmic artery (83) with its frontal branch (86) is well shown. The nasociliary nerve (83) is cut. In the posterior portion of the orbit the lachrymal artery (73) and the lachrymal nerve (73) are shown. At this level certain arteries belonging to the circle of Willis appear; viz., the basilar (29), from which arises on either side the posterior cerebral. Anterolaterally from the basilar (29), on the left, is shown the internal carotid (69) just before it divides into the middle (69) and anterior cerebral arteries. The posterior communicating artery (62) is shown as it joins the posterior cerebral (55). The mesencephalon is cut just at the lower margins of the corpora quadrigemina (49) and red nucleus (50). At this level the oculomotor nerve (62) shows its external origin. Behind the optic tract (81) the cavity of the infundibulum is shown.

The right half of this section passes through the nasal bone and the upper portion of the frontal process of the maxilla; through the upper part of the lachrymal bone and the upper portion of the frontal process of the zygomatic bone, and through the greater wing of the sphenoid. Between the anterior (22) and the posterior (24) clinoid processes the internal carotid artery is shown. The bilateral sphenoidal sinuses lie within this section. They are very small (5 mm. in diameter). The left frontal sinus (88) communicates with the nasal cavity in the body of the section. The eyeball is cut in a plane passing through the center of the lens and through the optic nerve. The internal (10) and external (20) rectus muscles are cut lengthwise, while the inferior oblique muscle (18) is cut along its insertion. The anterior chamber (13) is labeled, but the posterior chamber is not. It should be recalled that the posterior chamber is bounded anteriorly by the iris, and posteriorly extends into the zonular spaces. Many of the smaller structures are plainly seen, but it is impossible to clearly represent or designate them on this drawing—e. g., the conjunctiva, the caruncula lacrimalis, the a. centralis retinae in the center of the cut end of the optic nerve. The ciliary ganglion lies just below the surface of the section. The trochlear nerve (16) is shown just to the right of the optic nerve. The upper portion of the pons is cut, showing the aqueduct of Sylvius in the posterior median line.

Note.—Leader 34 extends to the olfactory bulb; the olfactory tract lies just behind it.



SECTION 8

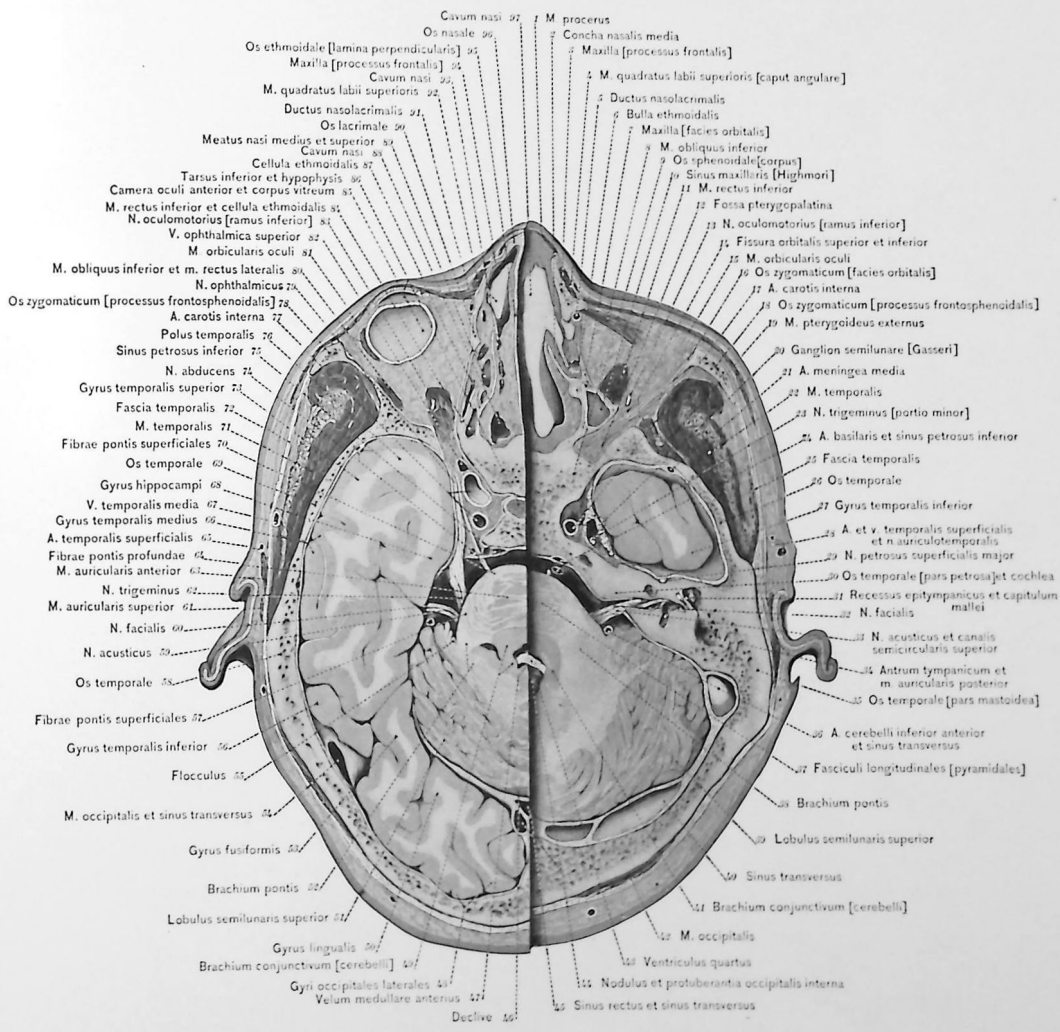
Section 9

Section 9

The levels of the halves of this section are indicated by lines 9 and 9' in Key-figures I, II, III.

On the left the section passes through the lower portion of the nasal bone, through the middle of the lachrymal bone, and about 6 mm. above the zygomatic process of the temporal bone. The left eyeball is cut through the lower third, showing the anterior chamber (85) and the vitreous body (85). In the posterior portion of the orbit the inferior rectus muscle is shown (84) with its innervating branch (83) of the oculomotor nerve. The inferior margin of the external rectus (80) and the inferior oblique muscle below its insertion are both shown. The left cerebral hemisphere is cut through the lower portion of the temporal and occipital lobes. The pons Varoli is cut just above the level of the trigeminal nerve (62), which nerve can be traced forward to a marked enlargement—the Gasserian ganglion. Just anterior to the trigeminal nerve is the sixth or abducens nerve (74). This nerve is shown on the right side just within the basilar artery (24). Behind and below the trigeminal nerve the facial nerve (60) and the auditory (59) nerve are shown. Portions of the superior (49) and middle (52) cerebellar peduncles are shown. The greater portion of the pituitary body lies in the section above. Its lower portion (86) is shown in the pituitary fossa (*fossa hypophyseos*).

The right half of the section passes just below the nasal bone, through the lower margin of the lachrymal and just above the upper margin of the zygomatic process of the temporal. The section passes just beneath the eyeball, showing the inferior oblique muscle (8) near its origin from the wall of the orbit. The inferior rectus (11) is cut obliquely through the lower portion. Just behind the orbit the upper portion of the maxillary sinus (10) is shown. The temporal bone is cut at a level which exposes a portion of the mastoid antrum (34). The epitympanic recess (31) contains the head of the malleus. A small portion of the cochlea (30) is exposed and the superior semicircular canal (33) is cut. The external pterygoid muscle (19) extends into the section above. The facial (32) and auditory (33) nerves are shown. It should be recalled that between these lies the intermediate nerve of Wrisberg, which is not labeled. The fastigium of the cerebellum lies in the section above, and its removal brings the nodulus of the vermis (44) plainly into view. The straight sinus (45) is shown just before it empties into the left lateral sinus (*sinus transversus*) which lies just anterior to it. The terminal portion of the superior sagittal sinus where it empties into the right lateral sinus has been cut off in bisecting the section.



SECTION 9

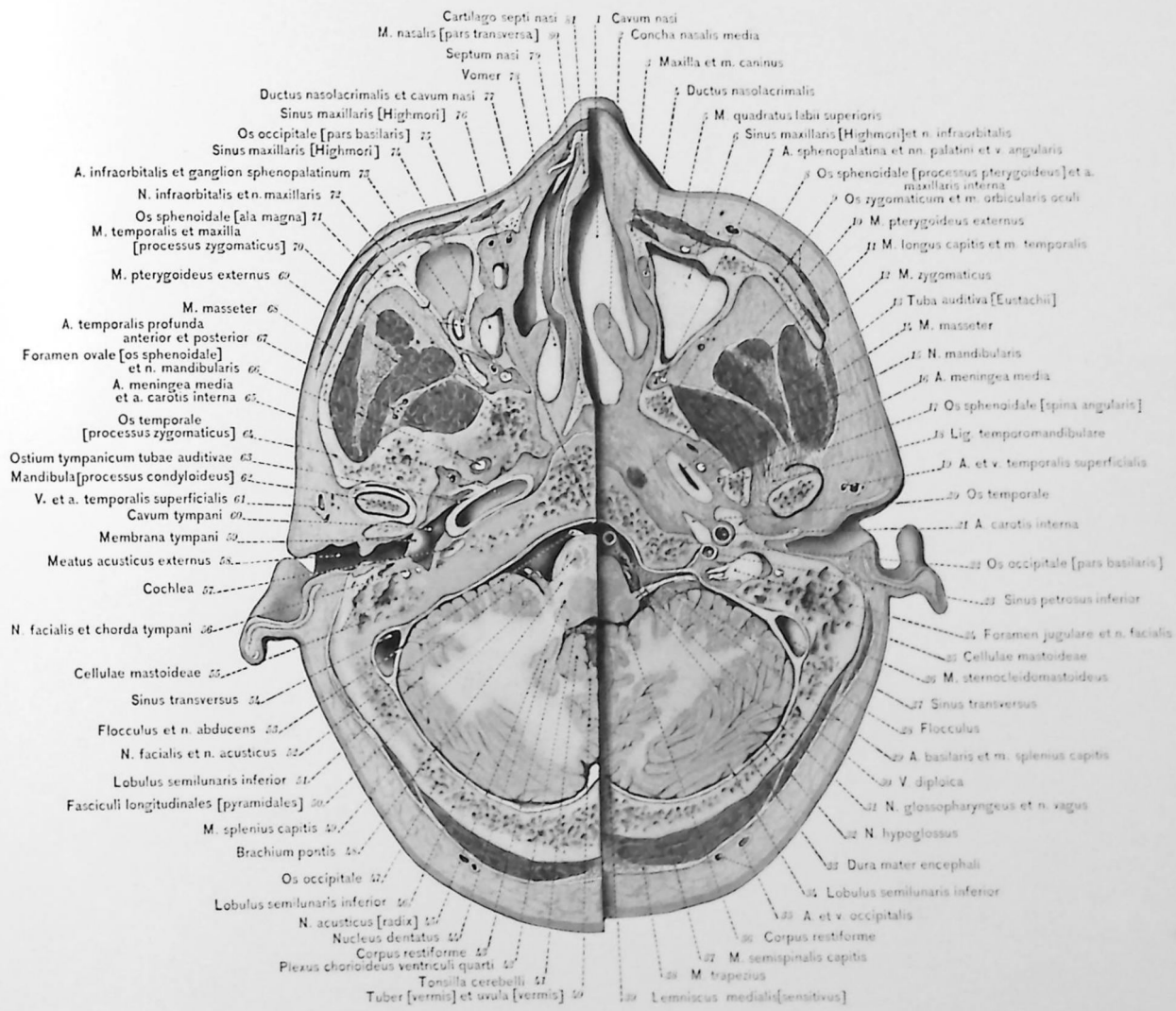
Section 10

Section 10

The levels of the halves of this section are indicated by lines 10 and 10' in Key-figures I, II, III.

On the left side the section passes through Reid's base line, as previously defined. It passes through the base of the frontal process of the malar bone (os zygomaticum); lengthwise through the upper portion of the temporal process of the malar, and through the zygomatic process (64) of the temporal; through the upper portion of the head of the condyloid process (62) and the temporo-mandibular articular cartilage. The sphenopalatine artery lies just below the surface of the section. The entrance to the Eustachian tube (63), the tympanic cavity (60), and the tympanic membrane (59) are shown. It should be noted that the ear bones are not indicated, since they were destroyed in cutting the section. The Vidian canal lies in the lower surface of the section above. The section passes through the lower portion of the pons about 5 mm. above the foramen caecum, and through the cerebellum at the level of the flocculus (53) and the lower portion of the dentate nucleus (44). Some of the superficial fibers of the pons are shown, likewise the decussating fibers of the mesial lemniscus (39).

On the right side the section passes below the orbit, through the inferior margin of the temporal process of the zygomatic bone, the lower portion of the head of the condyloid process, and the lower margin of the external auditory meatus. The following muscles are first cut: the zygomaticus (12), longus capitis (11), trapezius (38), and masseter (68). The section passes near the junction of the pons and medulla, cutting the root of the hypoglossal nerve (32), and the roots of the glossopharyngeal and vagus nerves (31). The inferior cerebellar peduncles (corpora restiformia) are shown at 36 and 43. Just within the root of the hypoglossal nerve (32) the olivary body is seen. The chorda tympani is shown just within the end of leader 56.



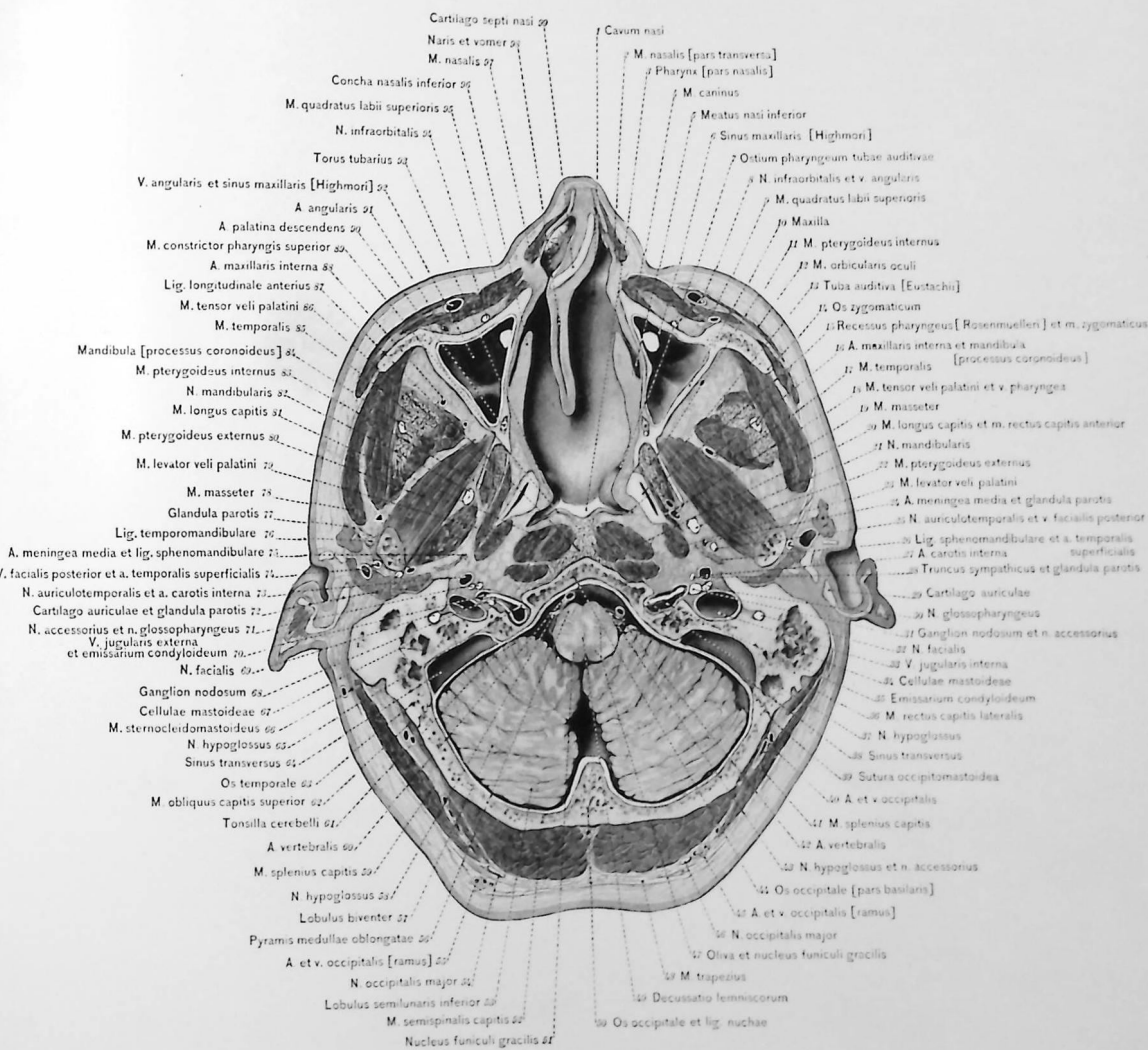
SECTION 10

Section 11

Section 11

The level of this section is indicated by line 11 in Key-figures I, II, III. It is the first section not bisected.

The section passes through the maxilla about 4 mm. above the anterior nasal spine, through the lower margin of the malar or zygomatic bone (14), the upper end of the coronoid process (16): through the condyloid process of the mandible and the mastoid portion of the temporal bone. The nasal cavity (1) is divided into unequal portions by the greatly deflected septum. The septum is made up of three distinct parts: the bony part (98), cartilaginous part (99), and the membranous part. Each of the nares is bounded above and in front by the lower lateral cartilage (cartilago alaris major). The pharyngeal openings of the Eustachian tube (7) are indicated on either side. Just behind the Eustachian cushion (torus tubarius) (93) the deep pharyngeal fossa of Rosenmueller (15) is shown on either side. The following muscles are cut for the first time: the rectus capitis anterior (20), longus capitis (81), both the tensor (18) and the levator veli palatini (23, 79), constrictor pharyngeus superior (89), and the obliquus capitis superior (62). This is the first section showing the parotid gland (24, 28, 72, 77). The external carotid artery divides in the lower part of the section into its terminal branches, the superficial temporal (74) and the internal maxillary (16). The branches of the occipital arteries (45, 55) are better defined, and the vertebral arteries (42, 60) are shown before they unite in the section above to form the basilar artery. The section passes just below the vermis of the cerebellum and through the medulla at the level of the middle of the olivary nucleus (47). Just external to the nucleus gracilis (47, 51) there is a smaller nuclear mass, the nucleus cuneatus. The cranial nerves shown at this level, anteriorly, are the hypoglossus (43, 58), and, posteriorly, the intermingled roots of the vagus and glossopharyngeus.



SECTION II

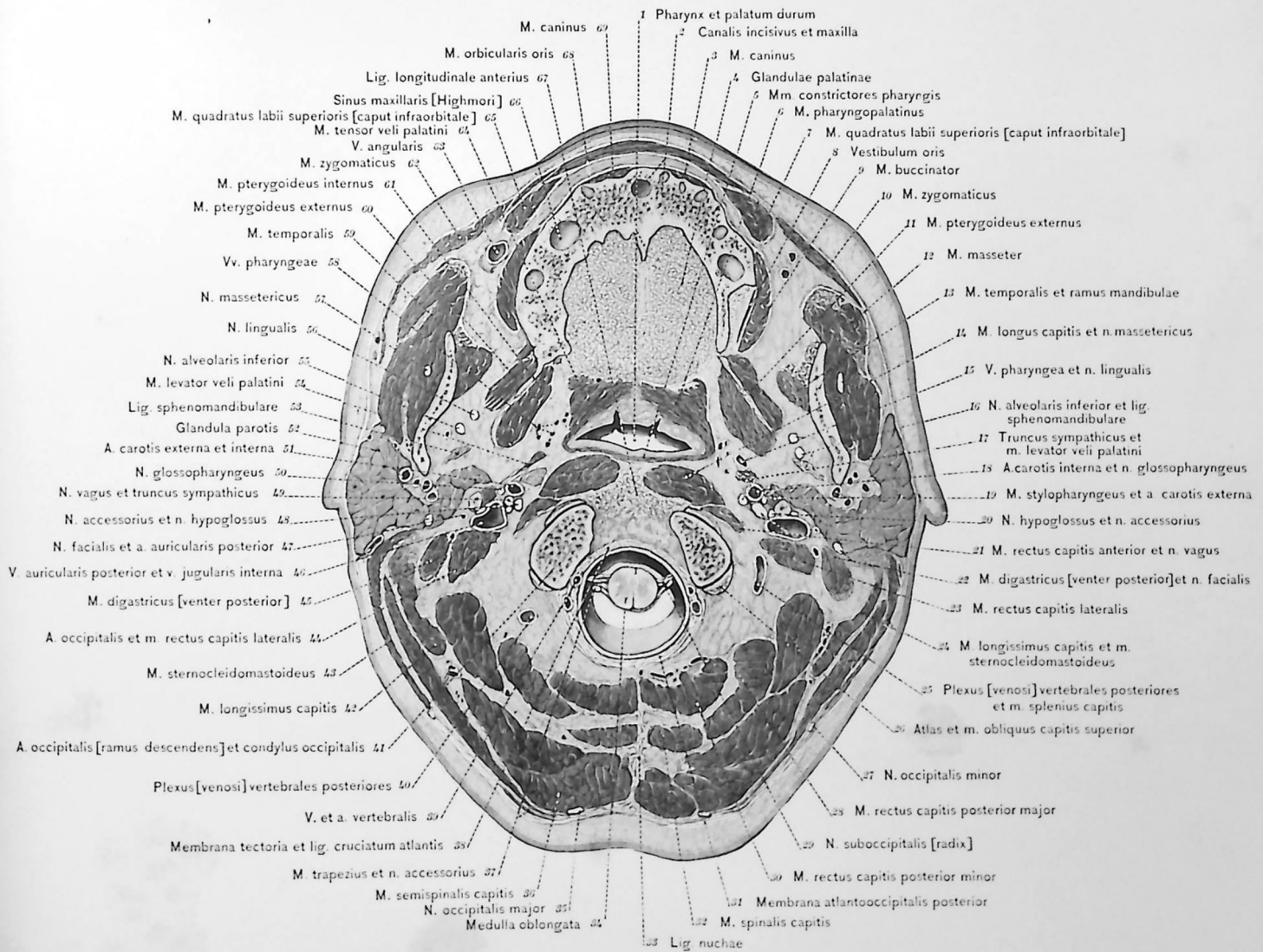
Section 12

Section 12

The level of this section is indicated by line 12 in Key-figures I, II, III.

The section passes through the alveolar process and just below the palatine process of the maxilla. The anterior palatine canal (2) lies in the median line and posterolaterally from it, on either side, the lower portion of the antrum (66). The section passes through the upper part of the ramus of the mandible (13); through the condyles (41) of the occipital bone and the superior articular processes of the atlas (26). The styloid process lies just in front of the internal jugular vein (46), but is not labeled. The occipito-axial ligament (38) and the cruciform ligament are fused at this level. The following muscles are cut for the first time: the pharyngopalatinus (6), buccinator (9), stylopharyngeus (19), digastric (22, 45), obliquus capitis superior (26), longissimus capitis (24, 42), rectus capitis posterior minor (30), spinalis capitis (32), and the orbicularis oris (68). The first cervical nerve (29) and the spinal portion of the spinal accessory nerve (37) are shown. The maximal extension of the parotid gland (52) is at this level. The mucous membrane of the hard palate shows the median raphe and numerous mucous glands (4), which are represented by small white areas.

Note.—The branch of the leader 44 to the a. occipitalis runs along the inner margin of the digastric muscle (45) but is obscure.



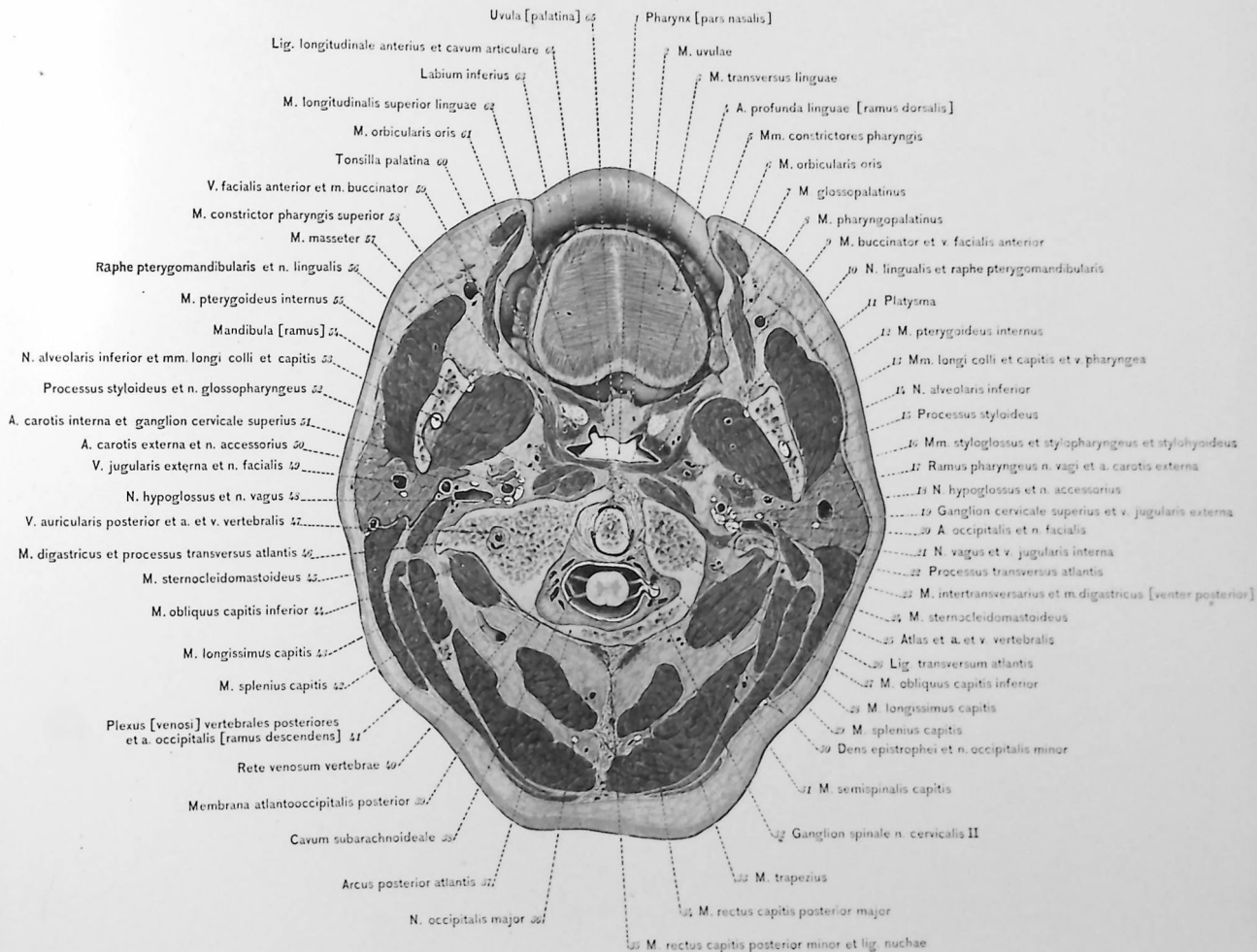
SECTION 12

Section 13

Section 13

The level of this section is indicated by line 13 in Key-figures I, II, III.

The section passes through the lower portion of the ramus of the mandible (54), the lower portion of the anterior arch of the atlas, and the upper portion of the posterior arch (37) of the same; through the odontoid process of the axis (30), showing its articular cavity (64). It passes through the upper portion of the tongue and through the uvula (65). The teeth of the lower jaw are seen below the surface. The following names are given to the teeth in the BNA: the first on either side of the median line = *Dens incisivus medialis*; the second = *Dens incisivus lateralis*; the third = *Dens caninus*; the fourth and fifth = *Dentes præmolares I and II*; the sixth, seventh, and eighth = *Dentes molares I, II, and III*. The pterygomandibular ligament (10, 56) is cut at its point of attachment to the crista buccinatoria of the mandible. The following muscles are cut for the first time: the *transversus linguæ* (3), the *longitudinalis superior linguæ* (62), *glossopalatinus* (7), *platysma* (11), *longus colli* (13, 53), *styloglossus* and *stylohyoideus* (16), *intertransversarius* (23), and the *obliquus capitis inferior* (27, 44). The *rectus capitis posterior minor* muscle (35) does not extend beyond this section. The internal carotid artery, on the right, lies just in front of the ganglion cervicalis superius (19). The glossopharyngeal nerve (52) lies anteromesially to the carotid artery. This nerve is not labeled on the right side. The posterior auricular artery arises in this section and lies externally and posteriorly to the external carotid artery.



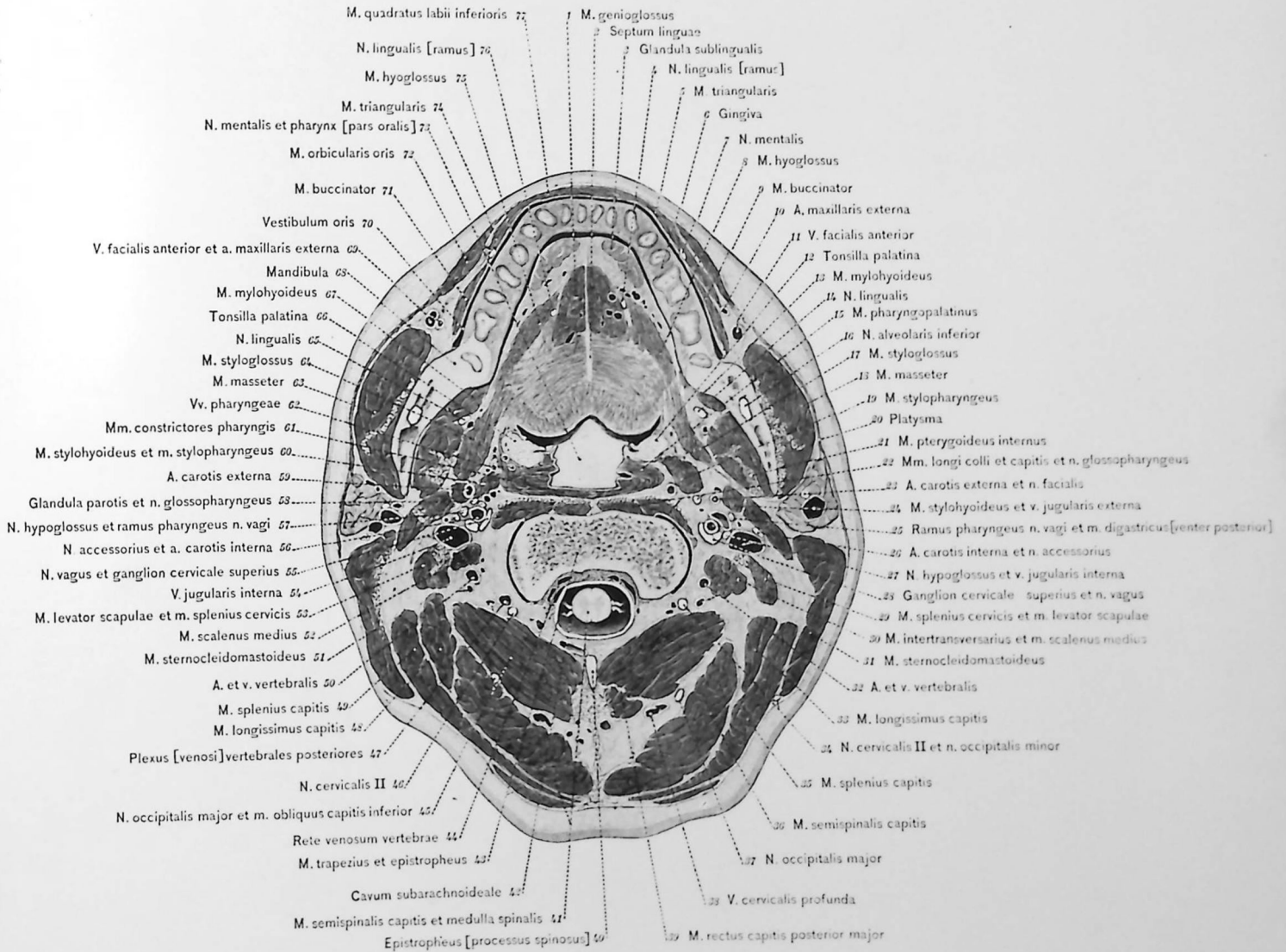
SECTION 13

Section 14

Section 14

The level of this section is indicated by line 14 in Key-figures I, II, III.

The section passes through the mandible (68) near the junction of the ramus and the body; through the lower third of the body of the axis (43), and the superior margin of the spinous process (40) of the same. The necks of all the teeth are shown in the gums (6), excepting the wisdom teeth the roots of which are seen in the alveolar process of the mandible. The section also passes through the tongue at the level of the upper portion of the sublingual gland (3), and through the pharynx (73) at the level of the middle portions of the tonsils (12, 66). The tongue shows the following muscles: the genioglossus (1), hyoglossus (8, 75), and the styloglossus (17, 64). In addition to these, the following muscles are cut for the first time: the triangularis (5), mylohyoideus (13, 67), levator scapulae (29, 53), and the splenius cervicis (29, 53). The facial nerve is not labeled on the left side, but lies just at the inner margin of the parotid gland (58).



SECTION 14

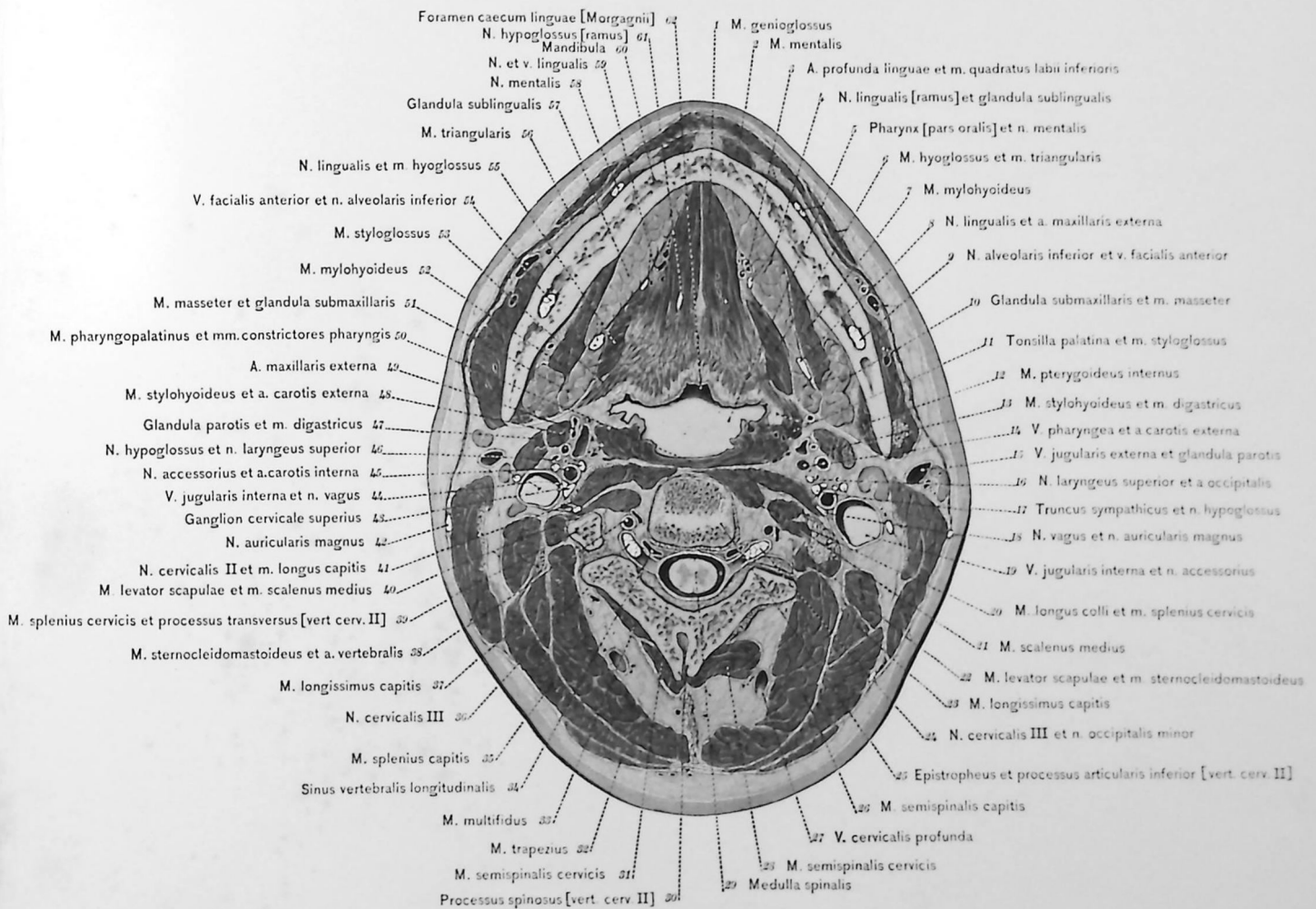
Section 15

Section 15

The level of this section is indicated by line 15 in Key-figures I, II, III.

The section passes through the body of the mandible just above the mental foramen; through the lower margin of the axis (25), and the spinous process of the same. It cuts the tongue just above the level of the foramen cæcum (62) and the inferior margin of the palatine tonsil (11). But little of the parotid gland (15, 47) extends to this level. The maximal anteroposterior extension of the sublingual gland (4, 57) is shown, and the submaxillary gland (10, 51) first appears. The following muscles are cut for the first time: the mentalis (2), depressor labii inferioris (3), scalenus medius (21, 40), semispinalis cervicis (28, 31), and the multifidus (33). The occipital artery (16) and the ascending pharyngeal artery, lying just external to the superior laryngeal nerve (16), both take origin in this section. The occipital artery on the left lies just in front of the hypoglossal nerve (46). The ascending pharyngeal artery lies between the carotid arteries. The facial artery (49) arises in this section. On either side it curves upward along the inner surface of the stylohyoid muscle (the right a little higher than the left) and overlaps the lower pole of the tonsil (11); it then passes downward, just posterior to the submaxillary gland, which it pierces, then passes anteriorly and appears in the next section below, then passes upward in the usual manner.

Note.—It should be recalled, in reading labels 25, 30, 39, that epistropheus and vertebra cervicalis II are synonymous.



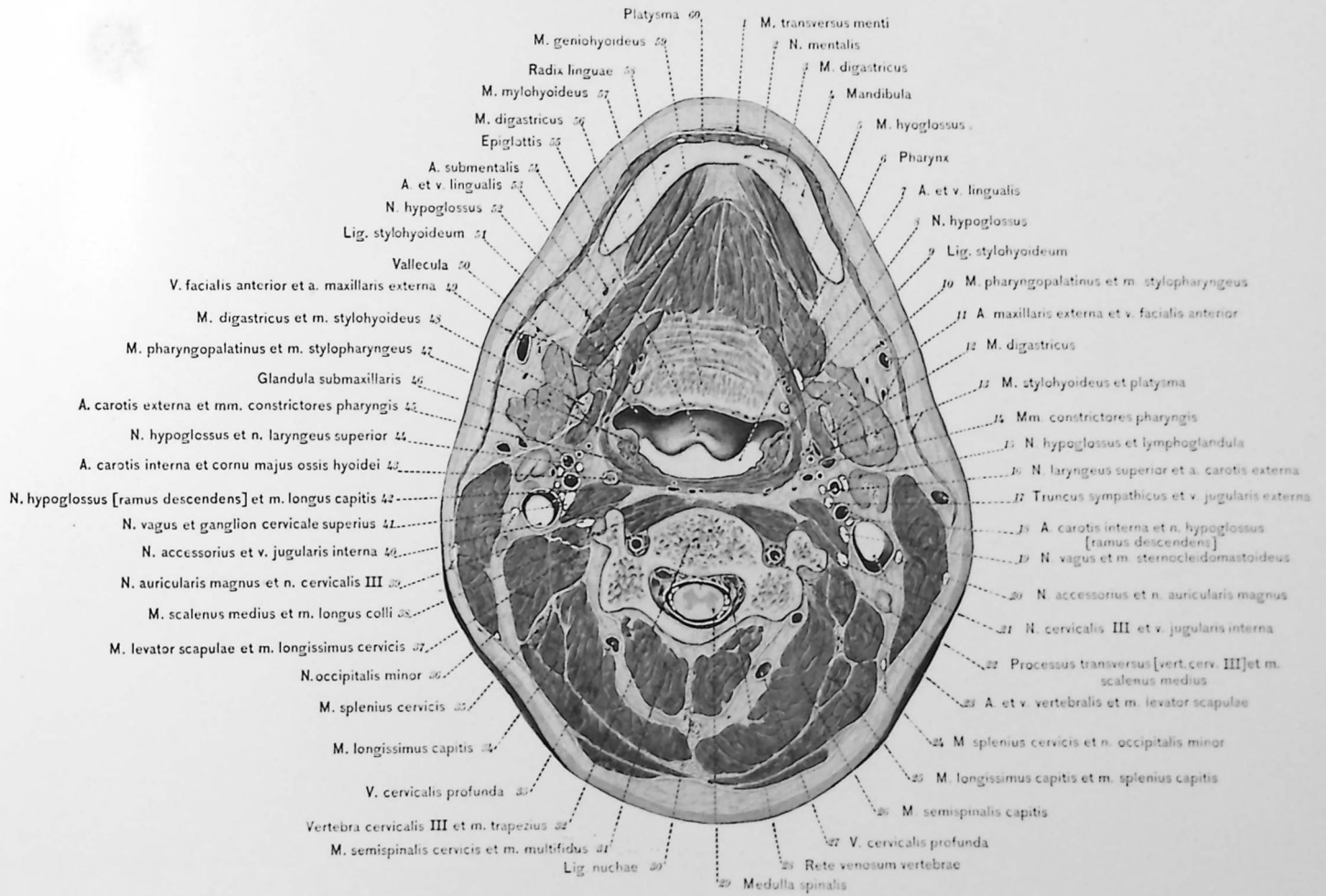SECTION 15

Section 16

Section 16

The level of this section is indicated by line 16 in Key-figures I, II, III.

The section passes through the lower margin of the mandible (4), a little below the mental protuberance; through the body of the third cervical vertebra (32), the transverse process (22) and the arch of the same. One of the superior horns of the hyoid bone (43) is shown. The section passes through the lower part of the tongue (58), and through the oral portion of the pharynx (6) just above the epiglottis (55). The submaxillary gland (46) is cut through its middle portion. Behind the submaxillary gland is a large lymph gland (15). The transverse muscle of the chin (1) is first shown in this section. The tendinous portions of the digastric muscles (12, 48) are shown. The left lingual artery takes origin in the lower part of this section. It passes vertically upward into the lower portion of the section above, then it curves downward and forward into this section, passes through the hypoglossus muscle, then curves upward and passes into the section above at 53. On the right side the lingual artery and the superior thyroid artery arise as a common trunk from the anterior surface of the external carotid artery. The course of the right lingual artery is nearly the same as that of the left.



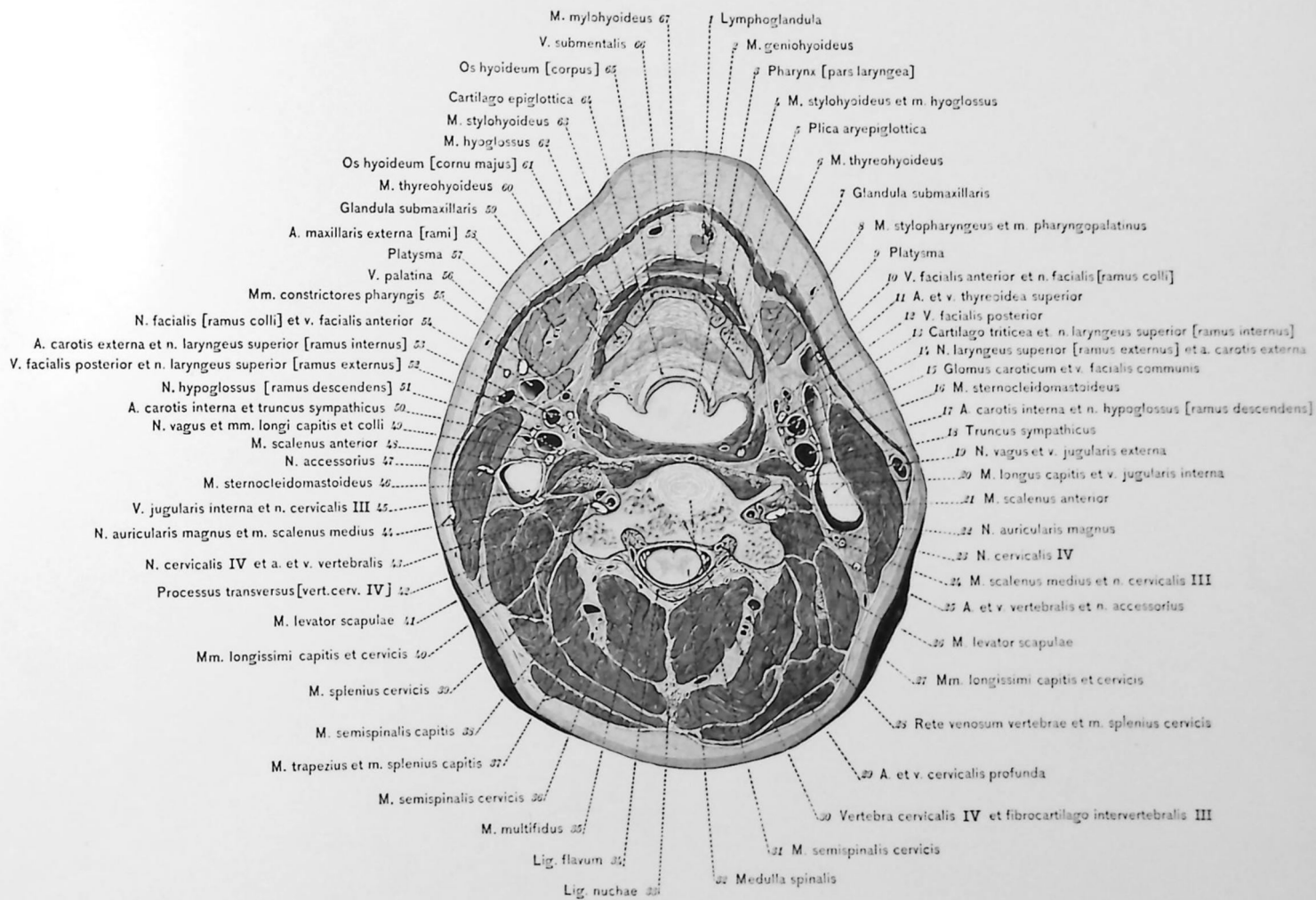
SECTION 16

Section 17

Section 17

The level of this section is indicated by line 17 in Key-figures I, II, III.

The section passes through the hyoid bone (65), and the greater horn (61) of the same; through the cartilage of the epiglottis (64), and the aryteno-epiglottidean fold (5). The triticeal cartilage (13) lies in the posterior margin of the thyreohyoid ligament. The section passes through the disc of the third and the body of the fourth cervical vertebra (30). The lower margins of the submaxillary glands (7, 59) lie in the lower portion of the section. The common carotid artery bifurcates on the right in the body of the section, giving rise to the internal (17) and the external (14) carotids. The carotid gland (15) lies between the external and internal carotid arteries. The left common carotid artery bifurcates partly in this section and partly in the section below. The superior thyreoid artery on the left side takes origin in this section, and is shown in the following section at 52. The anterior facial (10) and posterior facial (12) veins join to form the common facial vein (15), which enters the internal jugular (20) in the upper surface of the section.



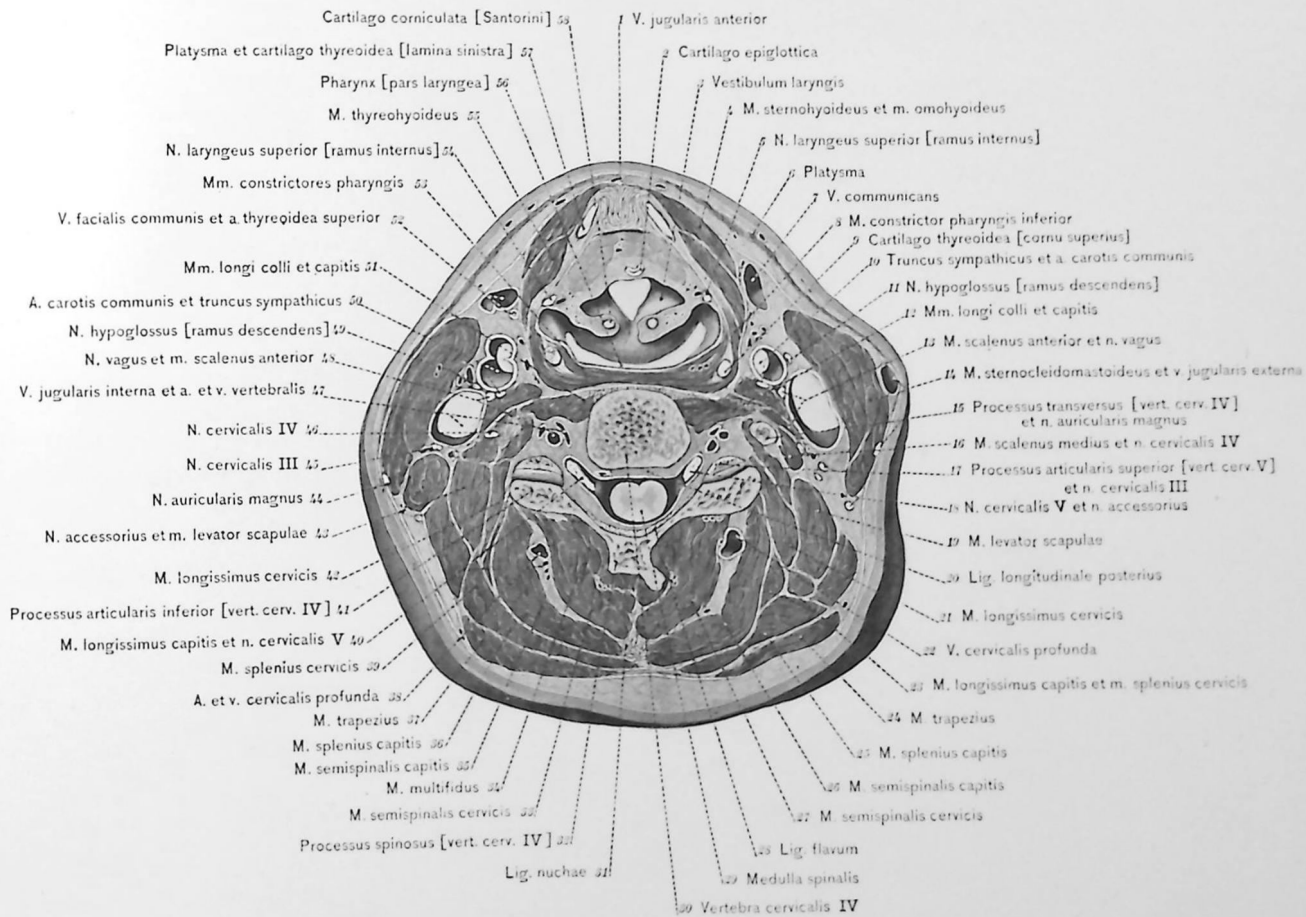SECTION 17

Section 18

Section 18

The level of this section is indicated by line 18 in Key-figures I, II, III.

The section passes through the body of the fourth cervical vertebra (30), the transverse (15) and the spinous (32) processes of the same; through the vestibule of the larynx (3); the lower portion of the cartilage of the epiglottis (2); the lamina (57) and superior horn (9) of the thyroid cartilage. Just behind and within the laminae is the so-called "fat body." On the right the thyrohyoid membrane is seen between the lamina and superior horn (9) of the thyroid cartilage. The cartilages of Santorini (58) are cut, and between them the interarytenoid notch is shown. The following muscles are cut for the first time: the sternohyoideus (4), thyrohyoideus (55), and the constrictor pharyngis inferior (8). A large vein (7) on the right side communicates with the common facial in the section above, and extends downward and anteriorly along the anterior margin of the sternocleidomastoid muscle and unites with the anterior jugular vein. Such a vein has been occasionally found (cf. Piersol, p. 884). We have labeled this communicating vein "V. communicans," although it is not given in the BNA. The vein on the left side, which apparently corresponds with the above, is the common facial (52), which empties into the internal jugular vein.



SECTION 18

Key-figure IV

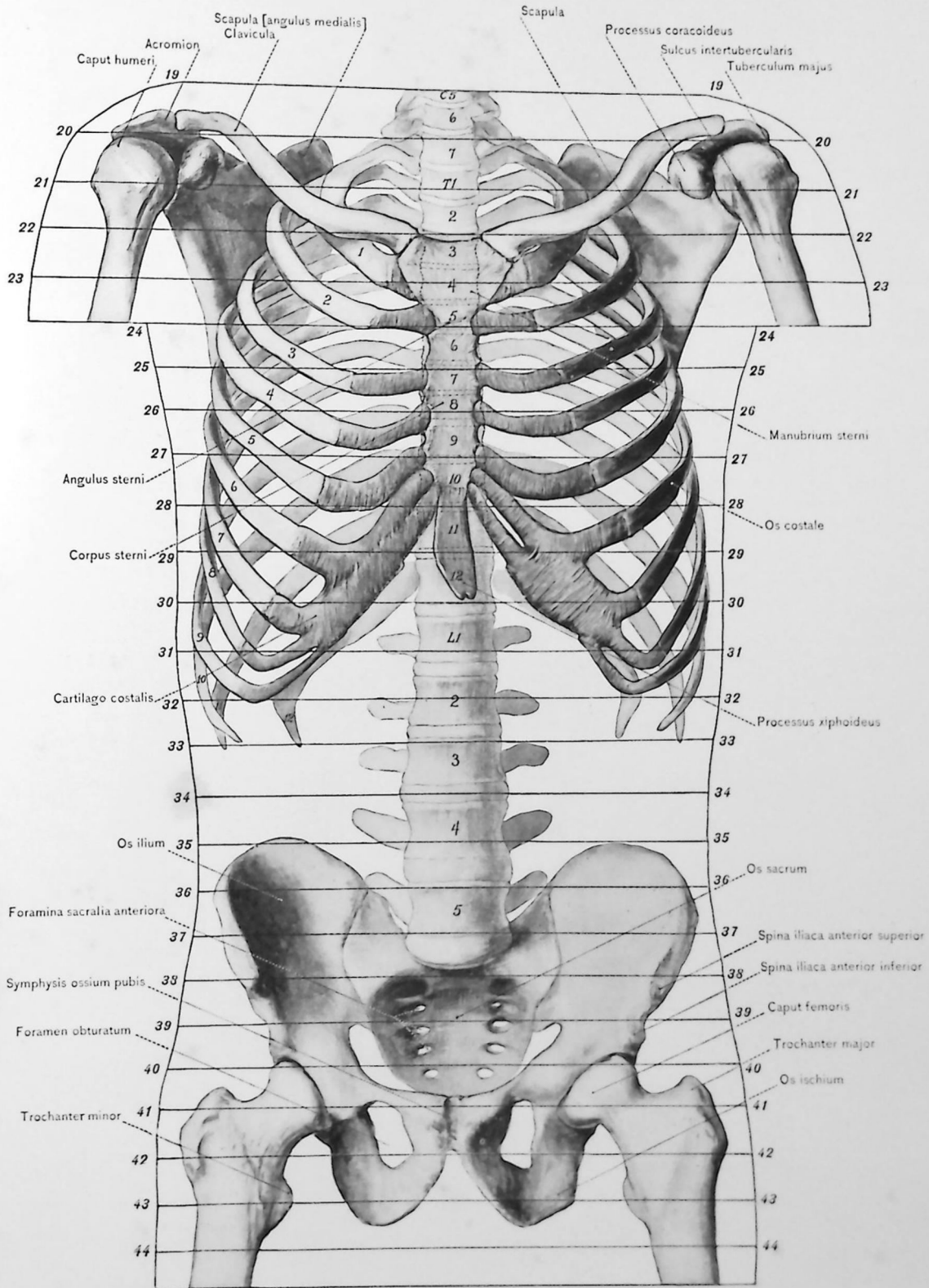
Key-figures IV, V, VI, VII

Key-figures IV, V, VI, VII cover not only the trunk, properly speaking, but also one section of the neck, a number of sections of the arm, and one, or possibly two, sections of the lower extremities.

A word of explanation is here necessary, since the BNA includes under the generic term "Trunk" (Truncus) the Thorax, Dorsum, Abdomen, and Pelvis. The Dorsum includes the columna vertebralis and the canalis spinalis. The Pelvis includes the pelvic cavity (cavum pelvis), the pubic eminence (mons pubis), the hip (coxa), the buttock (nates), the anus (anus), the anal cleft (crena ani), and the perineum (perineum). Hence it will be apparent that it is extremely difficult to fix the boundaries of the trunk. Merkel, Corning, and Schultze fix the delimitations of the neck and thorax as follows: upper margin of the sternum anteriorly, spinous process of seventh cervical vertebra posteriorly, anterolaterally the clavicles and posterolaterally lines drawn from the acromion process to the spinous process of the seventh cervical vertebra. The lower portion of the pelvis is likewise difficult to define, since there is no uniformity of opinion as to the boundary between the pelvis and limb. From the opinions of a number of anatomists we feel justified in saying that the inferior margin of the trunk lies somewhere near line 44.

Key-figure IV

This Key-figure was made entirely by reconstruction. It represents a front view of the skeleton of the trunk and shows the levels of the sections through the bones. These levels are indicated by the transverse lines 19-44. The vertebræ bear serial numbers, and the first vertebra in each subdivision bears an initial letter indicating the subdivision—e. g., C. 5 = fifth cervical vertebra, the sixth and seventh bear the numeral without the initial letter; T. 1 = first thoracic vertebra, the remaining eleven bear numerals only; L. 1 = first lumbar, the remaining four are designated by the numerals only. The sacral vertebræ are not numbered. The number of the intervertebral disc in each case we have arbitrarily designated as that of the vertebra above. The ribs on the right side bear serial numbers.

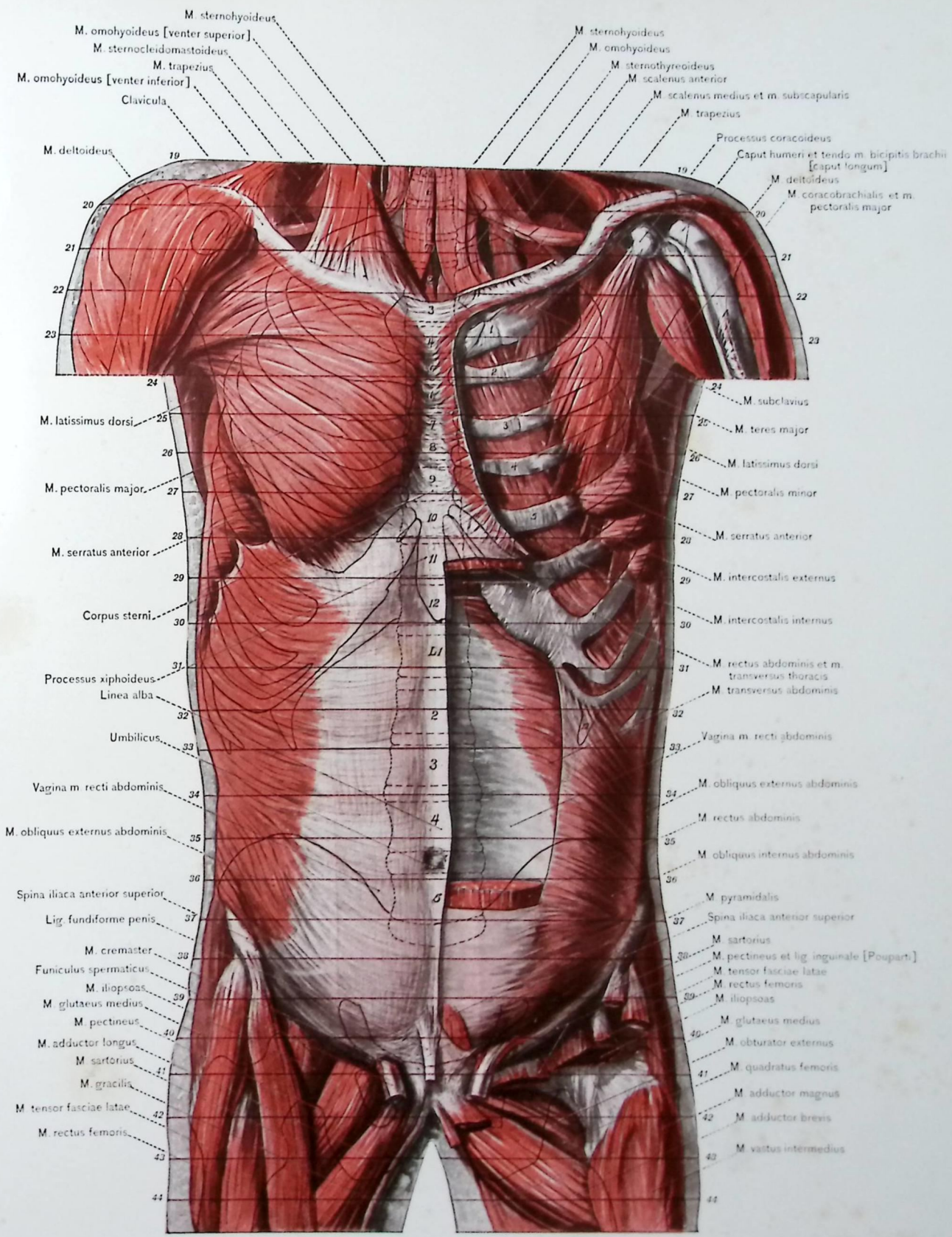


KEY-FIGURE IV

Key-figure V

Key-figure V

This Key-figure was made entirely by reconstruction. It represents a front view of the muscles of the trunk and shows the levels of the sections through these muscles. These levels are indicated by the transverse lines 19-44. The outline of the skeleton is indicated by black lines. The vertebræ and intervertebral discs are designated as explained under Key-figure IV. The ribs are serially numbered on the left side. Certain muscles have been cut away on the left side to show the underlying muscles. These are: the sternocleidomastoideus, the pectoralis major, the anterior portion of the deltoideus, the obliquus externus abdominis, the aponeurosis of the obliquus internus abdominis, the tensor fasciæ latæ, the sartorius, the rectus femoris, the iliopsoas, the pectineus, the adductor longus, and the gracilis. The rectus abdominis has been removed between sections 28-36 in order to show the transversus abdominis muscle and the posterior sheath of the rectus muscle. The penis and scrotum are not shown, the suspensory ligament (lig. fundiforme penis) and the spermatic cords have been cut off.

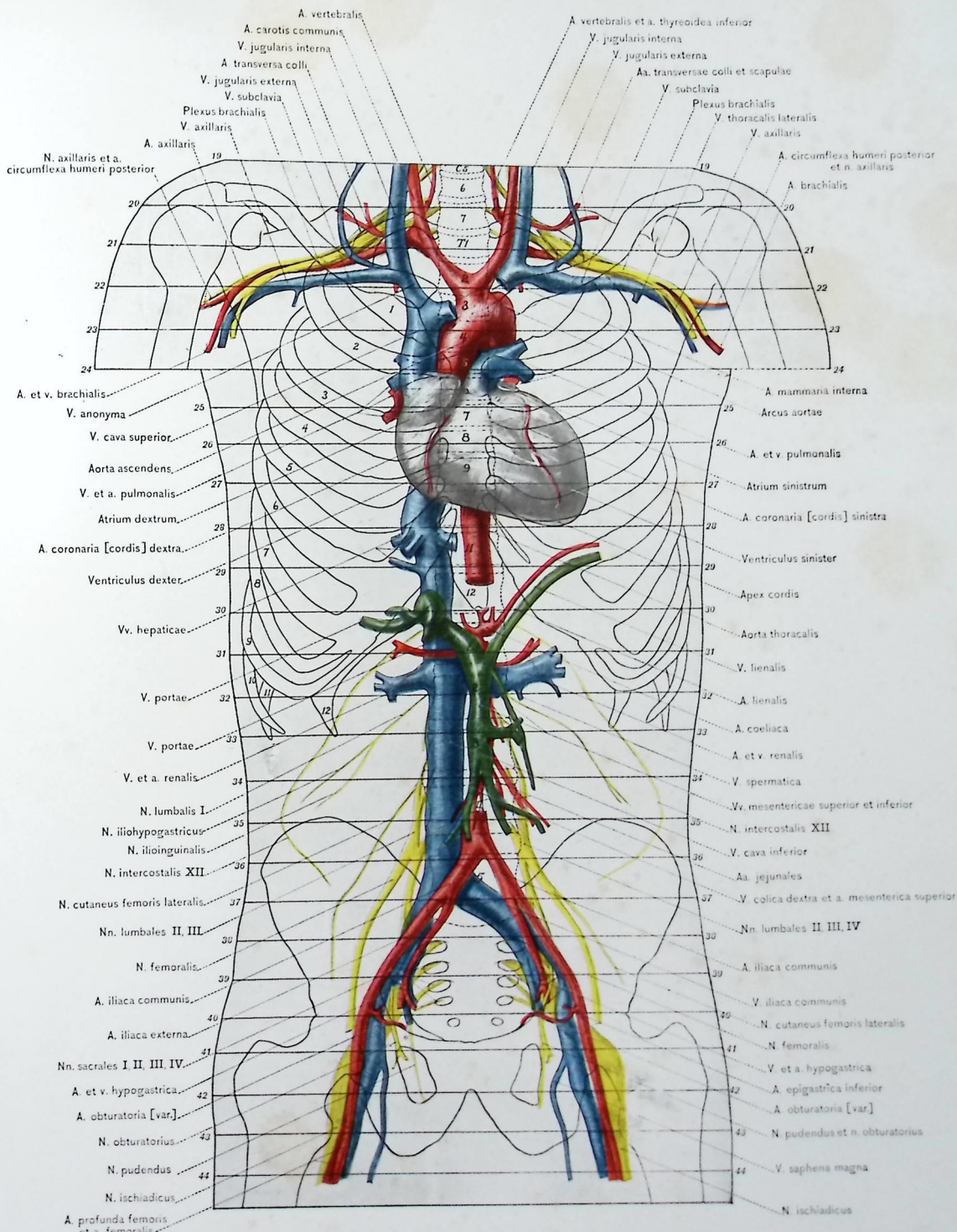


KEY-FIGURE V

Key-figure VI

Key-figure VI

This Key-figure was made entirely by reconstruction. It represents a front view of the heart and principal blood vessels, also the principal spinal nerve trunks and plexuses. The levels of the sections are indicated by the transverse lines 19-44. The outline of the skeleton is shown by black lines. The vertebrae, intervertebral discs and ribs are designated as previously stated. Conventional colors have been adopted as follows: red for heart, arteries, and pulmonary veins; blue for veins and pulmonary arteries, excepting the portal system which has been colored green; yellow for nerves. A portion of the left innominate vein (*v. anonyma*) has been left out in order to show the aortic arch with its branches. The thoracic aorta is represented as cut a little above the locality where it passes over into the abdominal aorta; this has been done to avoid confusion of colors. The aorta should be considered as continuous, since its branches are represented. Three important variations are found in the arteries, viz.: the left common carotid, which arises from the innominate; the inferior phrenic, which arises from the cœliac axis; and the obturators, which arise from the deep epigastrics.

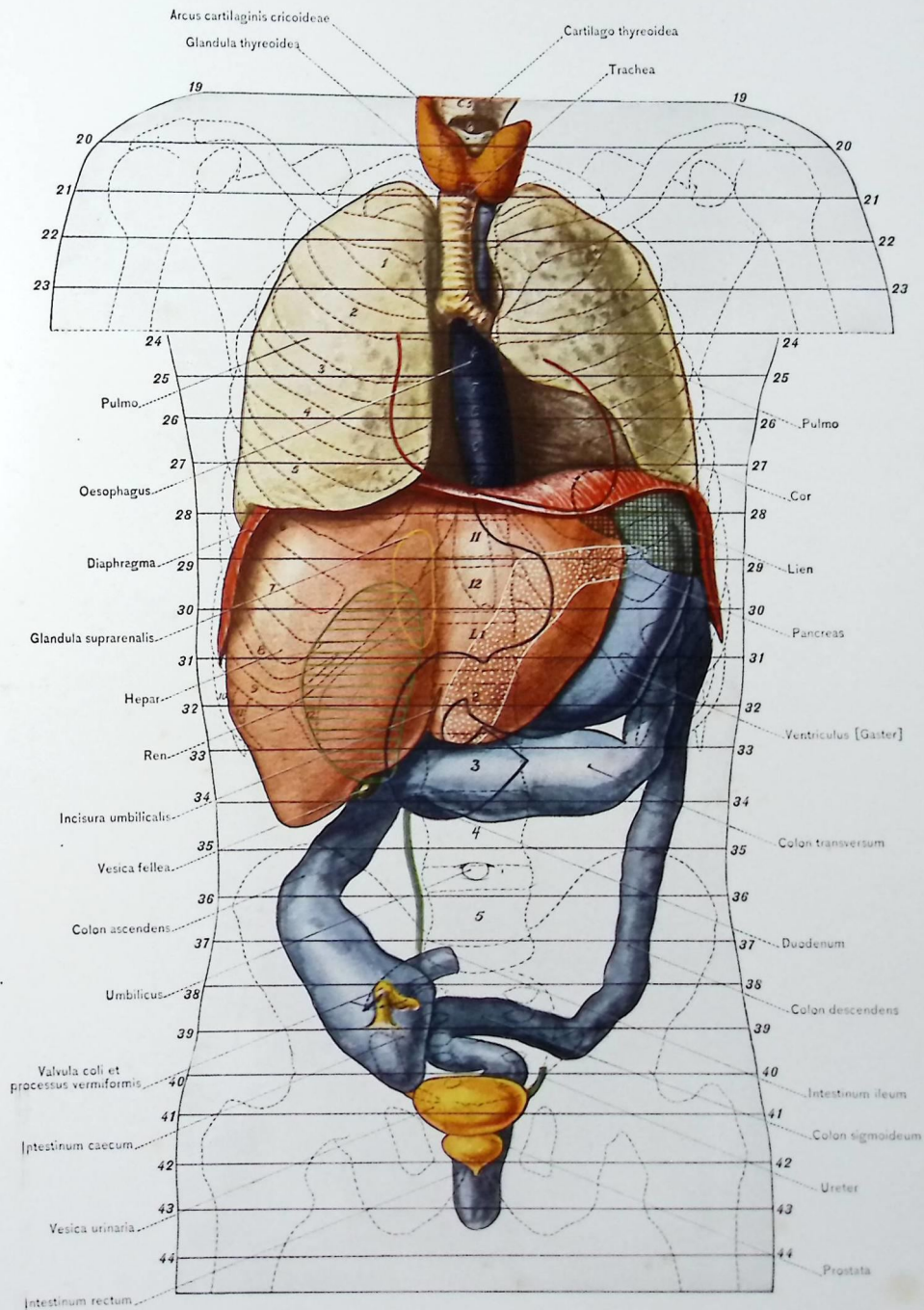


KEY-FIGURE VI

Key-figure VII

Key-figure VII

This Key-figure has been made entirely by reconstruction. It shows the topography of the thoracic and abdominal viscera and the levels of the sections with reference to the various organs. These levels are indicated by the transverse lines 19-44. The vertebræ, intervertebral discs and ribs are designated as explained previously. No attempt has been made to use conventional colors in representing the various organs. The color scheme adopted has been solely for contrast. Certain structures are outlined only, while others have been omitted entirely. The skeleton is shown by broken black lines. The outline of the heart has been indicated by a heavy red line. The lesser curvature of the stomach by a heavy blue line. The first, or superior portion, and second, or descending portion, and third, or inferior portion, of the duodenum are indicated also by heavy blue lines. The terminal portion of the duodenum has been omitted, and all of the remainder of the small intestine excepting a small segment, to show the position of the ileocæcal valve. The appendix has been indicated in yellow to give it prominence. The diaphragm has been indicated as cut off anteriorly. The left kidney and suprarenal have been omitted. The left ureter has been omitted, excepting its terminal portion. The outline of the covered portion of the spleen is indicated by a heavy broken line.



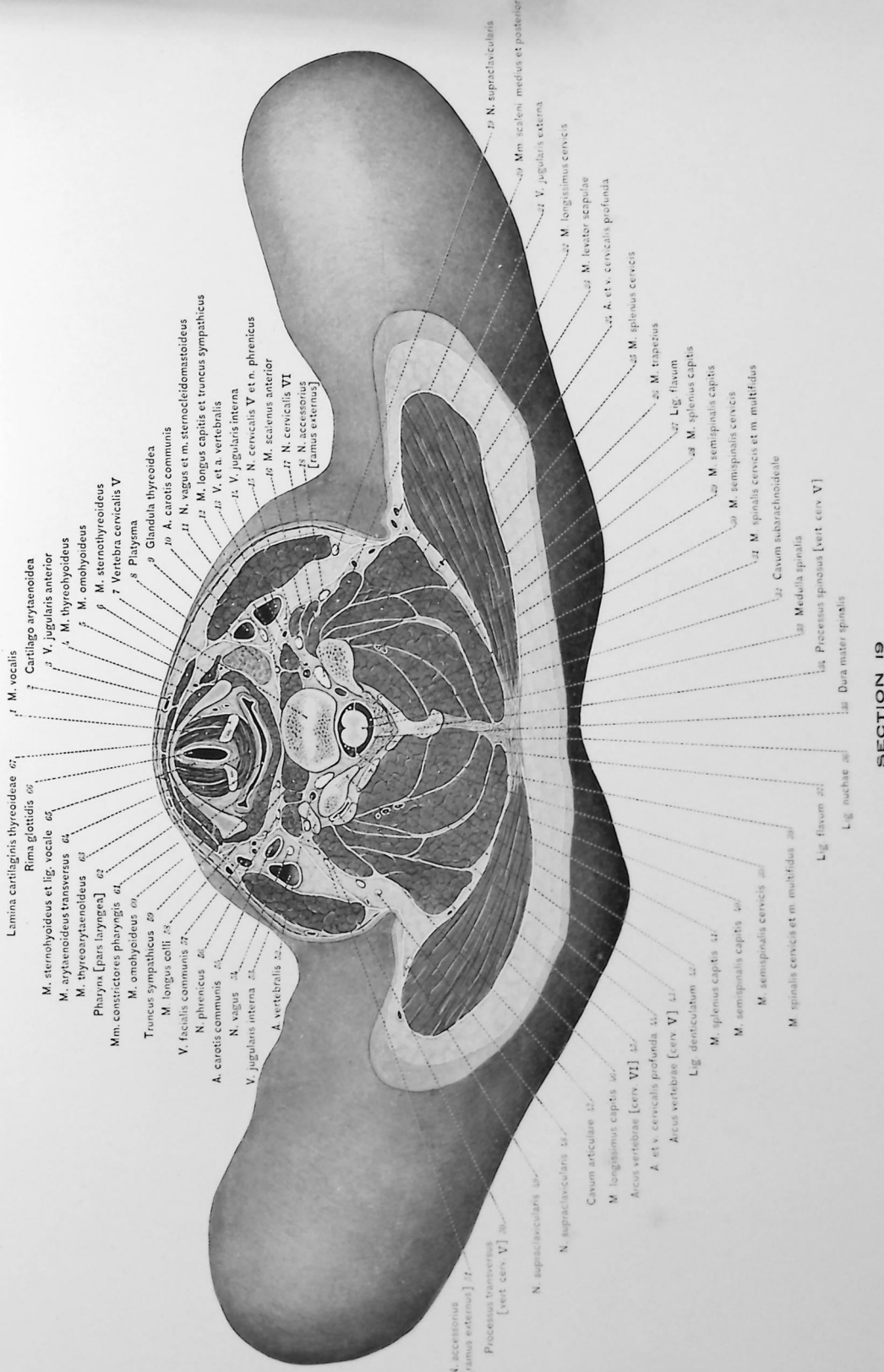
KEY-FIGURE VII

Section 19

Section 19

It should be recalled that the last section through the neck was at the level of the middle of the fourth cervical vertebra. Section 19 might well be considered as belonging to the neck. We have arbitrarily placed it with those of the trunk. Its level is indicated by line 19 in Key-figures IV, V, VI, VII. It will be noted that the anterior portions of this and the following section are somewhat asymmetrical as compared with their posterior portions. This probably is due to a slight rotation of the head at the time the subject was injected.

The section passes through the lower portion of the body of the fifth cervical vertebra (7), through the arch of the sixth (45), through the transverse processes of the fifth (50), and the spinous process of the same (34). The body of the sixth cervical vertebra lies entirely within the section. The upper portion of the acromion process and distal fourth of the clavicle lie in the lower portion of the section. The following muscles first appear: the thyroarytænoideus internus (*vocalis*) (1), scalenus posterior (20), thyroarytænoideus externus (63), and the arytænoideus transversus (64). The pharynx (62) extends downward to the lower third of this section, bringing its lower end opposite the sixth intervertebral disc, where it becomes continuous with the œsophagus. The section passes through the arytenoid cartilages (2), and about the middle of the thyroid cartilage (67). The cricoid cartilage lies almost wholly within this section. The upper half of the right lobe of the thyroid gland (9) is within this section; while the upper margin of the left lobe lies about at the middle of this section.



SECTION 19

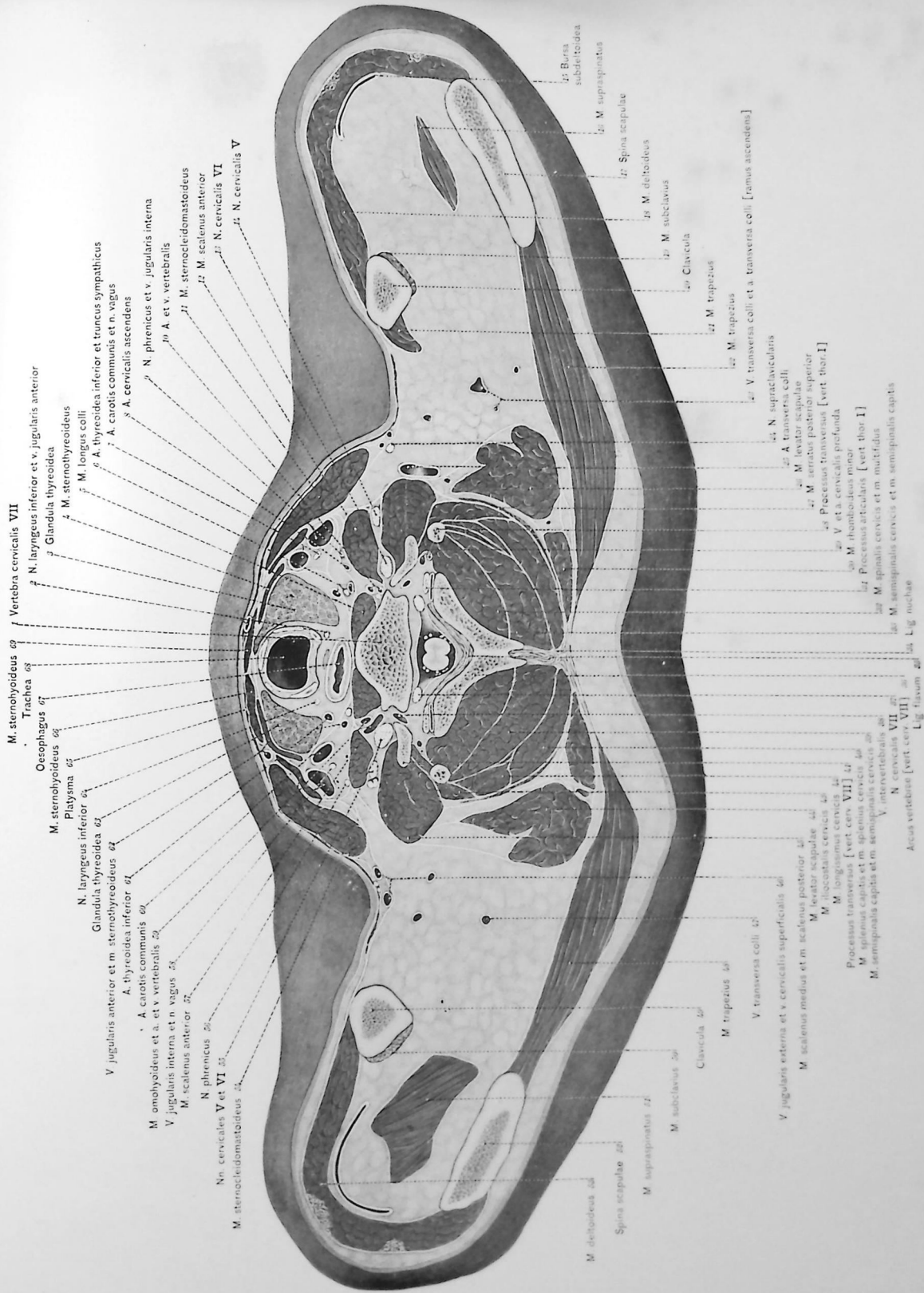
Section 20

Section 20

This section is about 26 mm. below the preceding section. Its level is indicated by line 20 in Key-figures IV, V, VI, VII.

The section passes through the upper margin of the body of the seventh cervical vertebra (1), the posterior arch (36), and the transverse process (41) of the same; through the superior articular processes (31) and the transverse processes (28) of the first thoracic vertebra; through the clavicles (20, 49) at about the level of the coracoid tubercles, and the spinous processes of the scapulae (17, 52), near the acromion processes. The greater portions of both the seventh cervical and the first thoracic vertebrae, the heads and necks of the first ribs, and the coracoid processes of the scapulae all lie in the body of this section. The following muscles are cut for the first time: the supraspinatus (16, 51), deltoideus (18, 53), subclavius (19, 50), clavicular portion of the trapezius (21), rhomboideus minor (30), and the iliocostalis cervicis (43). The subclavian artery curves upward into the lower portion of this section on either side, and gives origin to the thyreoid axis, the vertebral, and the superior intercostal arteries. The arches of the subclavian arteries in this subject extend to the level of the apices of the lungs. The inferior thyreoid artery (6, 61) on either side comes off from the thyreoid axis in the body of the section. It passes upward on either side into the lower portion of the preceding section, then curves backward again; it is thus cut twice. The vertebral artery (10, 59) also comes off from the subclavian in the lower portion of the body of this section. The thyreoid axis (*truncus thyreocervicalis*) arises from the subclavian in the lower portion of this section. The transverse cervical artery (25) (*a. transversa colli*) is cut on the right. It comes near the surface on the left, but is not shown. One of its ascending branches is cut across, and is not labeled but lies on line 46. The trachea (68) lies somewhat to the left of the mesial plane; it is cut at the level of the first tracheal ring. The second and third rings lie in the body of the section, while the fourth is cut by the next section. The isthmus of the thyreoid gland is wholly within the body of this section, and opposite the second and third tracheal rings. The right lobe (3) extends to the level of the third tracheal ring, while the left lobe (63) extends into the next section below. The lungs extend upward into the lower third of this section, reaching the level of the upper margin of the first thoracic vertebra. Their apices lie opposite the inferior margins of the necks of the first ribs. The œsophagus (67) lies somewhat to the left of the mesial plane.

Note.—We have labeled the *v. cervicalis superficialis* (46) following Toldt, Spalteholz and others, although it is not recognized in the BNA.



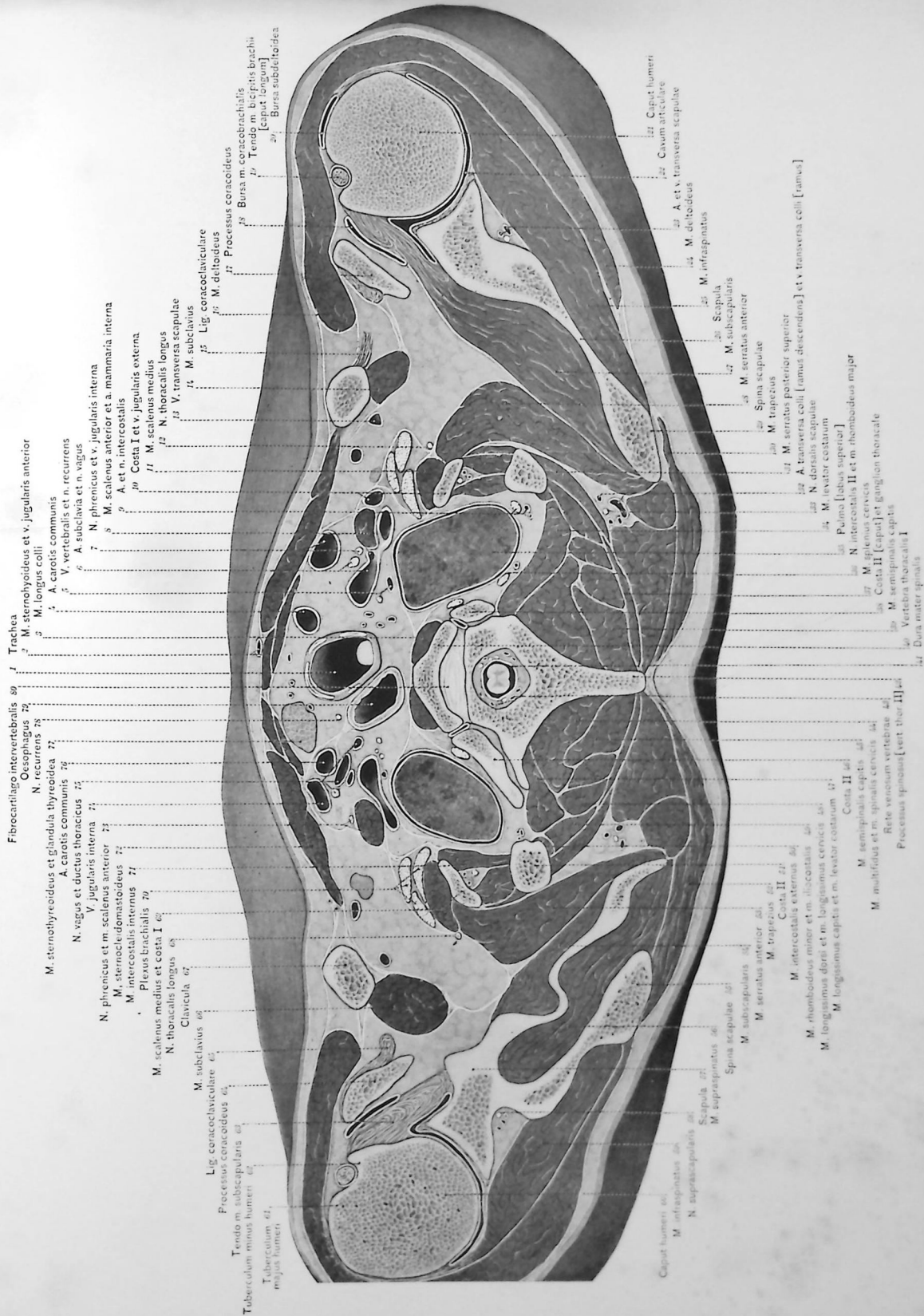
- M. sternohyoideus 40
 Trachea 43
 Oesophagus 47
 M. sternohyoideus 48
 Platysma 49
 M. laryngeus inferior 51
 Glandula thyroidea 52
 N. laryngeus inferior 53
 V. jugularis anterior et m. sternohyoideus 54
 A. thyroidea inferior 55
 V. jugularis anterior et m. sternohyoideus 56
 A. carotis communis 57
 V. jugularis interna et v. vertebralis 58
 M. scalenus anterior 59
 N. phrenicus 60
 Nn. cervicales V et VI 61
 M. sternocleidomastoideus 62
 V. jugularis inferior et v. jugularis interna 63
 N. laryngeus inferior et v. jugularis anterior 64
 Glandula thyroidea 65
 M. longus colli 66
 A. thyroidea inferior et truncus sympathicus 67
 A. carotis communis et n. vagus 68
 A. cervicalis ascendens 69
 N. phrenicus et v. jugularis interna 70
 A. et v. vertebralis 71
 M. sternocleidomastoideus 72
 M. scalenus anterior 73
 N. cervicilis VI 74
 N. cervicilis V 75
 Vertebra cervicilis VII 76
 M. deltoideus 40
 Spina scapulae 41
 M. supraspinatus 42
 M. subclavius 43
 Clavicula 44
 M. trapezius 45
 V. transversa coli 46
 V. jugularis externa et v. cervicalis superficialis 47
 M. scalenus medius et m. scalenus posterior 48
 M. levator scapulae 49
 M. pectoralis cervicis 50
 M. longus cervicis 51
 Processus transversarii [vert. cerv. VII] 52
 M. spinosus capitis et m. spinosus cervicis 53
 M. semispinalis capitis et m. semispinalis cervicis 54
 V. intervertebralis 55
 N. cervicilis VII 56
 Accus. vertebrae [vert. cerv. VII] 57
 Lig. flavum 58
 M. supraspinatus 42
 M. subclavius 43
 Clavicula 44
 M. trapezius 45
 V. transversa coli 46
 V. jugularis colli et a. transversa coli [arnus ascendens] 47
 N. suprascapularis 48
 A. transversa coli 49
 M. levator scapulae 50
 M. serratus posterior superior 51
 Processus transversarii [vert. thor. I] 52
 V. et a. cervicalis profunda 53
 M. rhomboideus 54
 Processus articularis [vert. thor. I] 55
 M. spinosus cervicis et m. multifidus 56
 M. semispinalis cervicis et m. semispinalis capitis 57
 Lig. flavum 58
 M. supraspinatus 42
 Spina scapulae 41
 M. subclavius 43
 Clavicula 44
 M. trapezius 45
 V. transversa coli 46
 V. jugularis externa et v. cervicalis superficialis 47
 M. scalenus medius et m. scalenus posterior 48
 M. levator scapulae 49
 M. pectoralis cervicis 50
 M. longus cervicis 51
 Processus transversarii [vert. cerv. VII] 52
 M. spinosus capitis et m. spinosus cervicis 53
 M. semispinalis capitis et m. semispinalis cervicis 54
 V. intervertebralis 55
 N. cervicilis VII 56
 Accus. vertebrae [vert. cerv. VII] 57
 Lig. flavum 58

Section 21

Section 21

This section is about 27 mm. below the preceding. Its level is indicated by line 21 in Key-figures IV, V, VI, VII. In order to bring this section within the plate, 2.5 cm. were cut from the left side of the original drawing.

The section passes through the lower portion of the body of the first thoracic vertebra (40), and its intervertebral disc (80). On the left side the section cuts both the transverse and spinous processes (42) of the second thoracic vertebra. On the right side the head of the second rib (38) is cut and on the left the head and neck (46) of the opposite rib. The shafts of the first pair of ribs (10, 69) are cut near their middle portions, and the second pair (51) through their angles. The section also passes through the middle of the clavicles (67), and the supraspinous fossa of the scapula on the left side. The following muscles first appear: the long head of the biceps (19), infraspinatus (25, 59), levator costarum (34, 47), and the rhomboideus major (36). The label on the rhomboideus major is obscure. It lies just posterior to the splenius cervicis (37). The variable innominate artery branches in this section giving rise to the right subclavian artery and the right (4) and left (76) common carotid arteries. The subclavian artery passes over into the axillary artery at the outer margin of the first rib, then passes downward into the succeeding section about opposite the surgical neck of the humerus. The right subclavian vein lies wholly in the section, and enters the innominate vein, in common with the internal jugular, in the lower portion of the section; the relations of these veins are practically the same on the left side. The axillary vein enters the lower surface of the section about opposite the outer margin of the second rib, and passes, in the lower portion of the section, to the outer margin of the first rib, where it becomes the subclavian vein. The thoracic duct is shown (75) where it arches over and enters the subclavian vein in the body of the section. The trachea (1) lies for the most part to the right of the mesial plane. The fourth tracheal ring is cut; the fifth, sixth, seventh, and eighth lie wholly in the section. The tenth ring is cut anteriorly, and the ninth posteriorly, by the next section. A small piece of the inferior portion of the left lobe of the thyroid gland (77) lies in this section. In close proximity to the lower margin of this lobe is the upper margin of the thymus gland. The upper portion of the fissure of the left lung is in the lower third of this section, where it lies opposite the middle of the second thoracic vertebra. The œsophagus (79) at this level is largely to the left of the mesial plane.



- Fibrocartilago intervertebralis 80
 Trachea
 1 M. sternothyroideus et v. jugularis anterior
 2 M. longus colli
 3 V. vertebralis et n. recurrens
 4 A. carotis communis
 5 V. vertebralis et n. recurrens
 6 A. subclavia et n. vagus
 7 N. phrenicus et v. jugularis interna
 8 M. scalenus anterior et a. mammae interna
 9 A. et n. intercostalis
 10 Costa I et v. jugularis externa
 11 M. scalenus medius
 12 N. thoracalis longus
 13 V. transversa scapulae
 14 M. subclavius
 15 Lig. coracoclaviculare
 16 M. deltoideus
 17 Processus coracoideus
 18 Bursa m. coracobrachialis
 19 Tendo m. bicipitis brachii [Caput longum]
 20 Bursa subdeltoidea

- 21 Caput humeri
 22 Cavum articulare
 23 A. et v. transversa scapulae
 24 M. deltoideus
 25 M. infraspinatus
 26 Scapula
 27 M. subscapularis
 28 M. serratus anterior
 29 Spina scapulae
 30 M. trapezius
 31 M. serratus posterior superior
 32 A. transversa colli [ramus descendens] et v. transversa colli [ramus]
 33 N. dorsalis scapulae
 34 M. levator costarum
 35 Palma [labrus superior]
 36 N. intercostalis II et m. rhomboideus major
 37 M. splenius cervicis
 38 Costa II [caput] et ganglion thoracale
 39 M. semispinalis capitis
 40 Vertebra thoracalis I
 41 Dura mater spinalis
 42 M. sternothyroideus et glandula thyroidea 71
 43 N. recurrens 73
 44 M. sternocleidomastoideus et glandula thyroidea 71
 45 N. vagus et ductus thoracicus 72
 46 A. carotis communis 76
 47 V. jugularis interna 71
 48 N. phrenicus et m. scalenus anterior 71
 49 M. sternocleidomastoideus 72
 50 M. intercostalis internus 77
 51 Plexus brachialis 79
 52 M. scalenus medius et costa I 62
 53 N. thoracalis longus 68
 54 Clavicula 67
 55 M. subclavius 66
 56 Lig. coracoclaviculare 67
 57 Processus coracoideus 65
 58 Tendo m. subscapularis 63
 59 Tuberculum majus humeri 61
 60 Tuberculum minus humeri 61
 61 M. infraspinatus 68
 62 N. suprascapularis 68
 63 Scapula 67
 64 M. serratus anterior 67
 65 M. trapezius 66
 66 Costa II 77
 67 M. intercostalis externa 66
 68 M. rhomboideus minor et m. iliocostalis 68
 69 M. longissimus dorsi et m. longissimus cervicis 68
 70 M. longissimus capitis et m. levator costarum 67
 71 Costa II 66
 72 M. semispinalis capitis 66
 73 M. multifidus et m. spinalis cervicis 66
 74 Rete venosum vertebrae 66
 75 Processus spinosus [vert. thor. I] 64

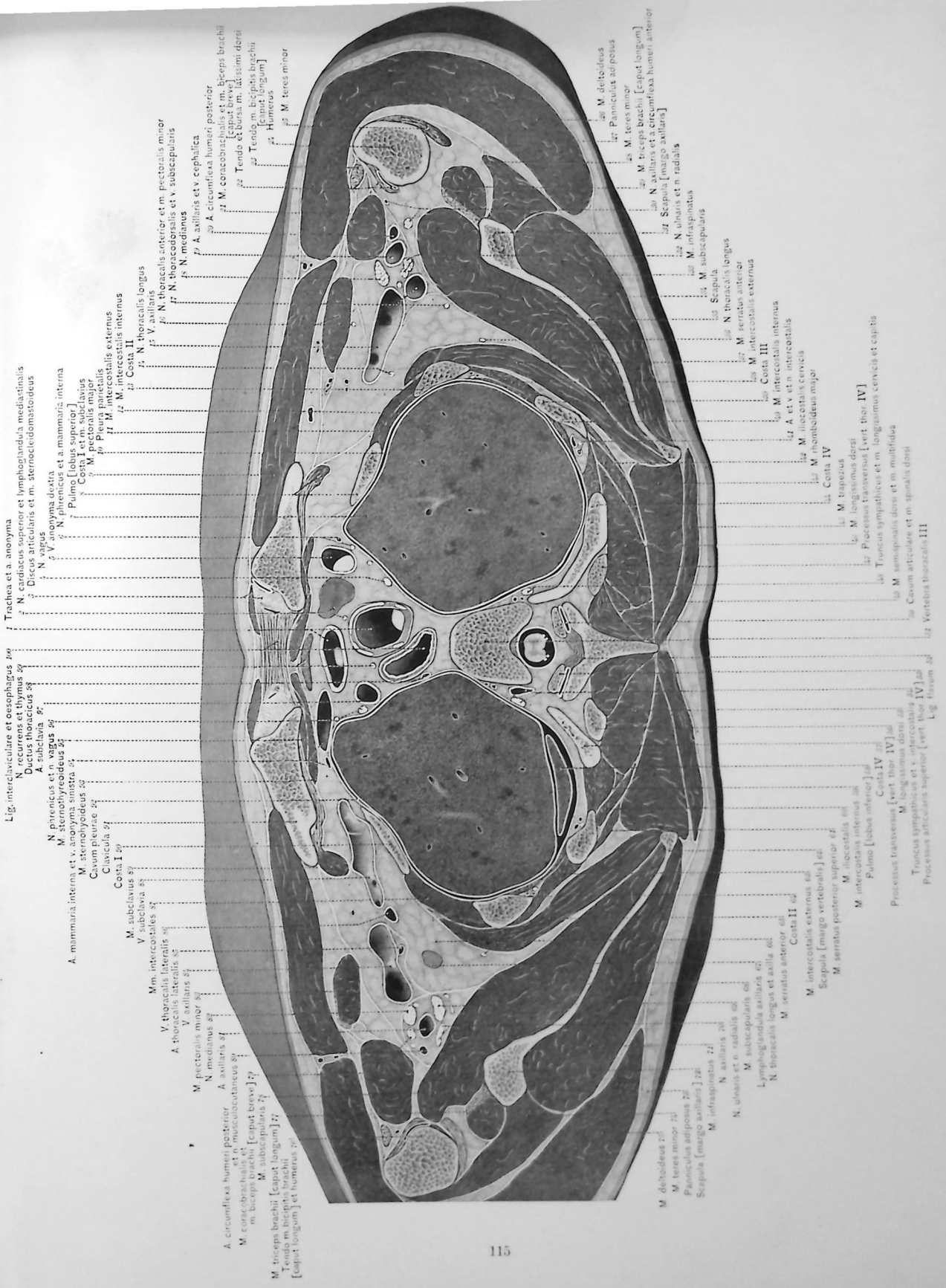Section 22

Section 22

This section is about 24 mm. below the preceding. Its level is indicated by line 22 in Key-figures IV, V, VI, VII. In order to bring this section within the plate, 4 cm. were cut from the left side of the original drawing.

The section passes through the upper margin of the body of the third thoracic vertebra (51), and the arch and spinous process of the same. It cuts the superior articular process of the fourth thoracic vertebra (53), and the transverse processes (47, 56) of the same. It passes through the following ribs: the first (8, 90), second (13, 64), and third (39), and the upper portion of the fourth (44, 57); through the sternal ends of the clavicles (91), slightly above the upper margin of the manubrium; through the scapula (35), about 1 cm. below the lower margin of the glenoid fossa, and through the surgical neck of the humerus (24, 76). The following muscles are cut for the first time: the pectoralis major (9), pectoralis minor (16, 83), coracobrachialis (21, 79), latissimus dorsi (22), teres minor (25, 28, 74), triceps (29, 77), and the short head of biceps (79). The highest point of the arch of the aorta lies in the upper third of the section, and at the level of the suprasternal notch. The variable innominate artery arises from the aortic arch in the upper third of the section. The axillary artery passes through this section about 2 cm. within the inner margin of the humerus. The innominate veins (5, 94) are shown; in the body of the section they unite opposite the upper portion of the third thoracic vertebra to form the superior vena cava. The highest point of the pericardial reflection on the aorta lies in the lower part of this section. The trachea (1) lies largely to the right of the mesial plane. The fissure of the left lung appears. In the body of this section an accessory fissure is found in the right lung, which is shown in Sections 23, 24, 25. The superior margin of the inferior lobe of the left lung lies in this section. The thymus (99) is a thin, transversely elongated body lying in the mesial plane. The oesophagus (100) lies largely to the left of the mesial plane.

Note.—We have labeled the v. subscapularis (17) following Toldt, Spalteholz and others, although it is not recognized in the BNA.



- 1 Lig. interchilare et oesophagus 14
 2 N. recurrens et thymus 29
 3 Pectus thoracicus 34
 4 A. axillaris 37
 5 N. phrenicus et n. vagus 38
 6 M. sternothyroideus 39
 7 A. mammaria interna et v. anonyma sinistra 44
 8 M. sternothyroideus 50
 9 Cavum pleurae 52
 10 Clavicula 57
 11 Costa I 59
 12 M. subclavius 87
 13 V. subclavia 87
 14 Mm. intercostales 87
 15 V. thoracalis lateralis 88
 16 A. thoracalis lateralis 88
 17 V. axillaris 87
 18 M. pectoralis minor 87
 19 N. medianus 87
 20 A. circumflexa humeri posterior et n. musculocutaneus 87
 21 M. coracobrachialis [caput breve] 77
 22 M. subscapularis 77
 23 M. triceps brachii [caput longum] 77
 24 Tendo m. bicipitis brachii [caput longum] et humerus 77
 25 A. circumflexa humeri anterior 29
 26 M. coracobrachialis et m. biceps brachii m. bicipitis brachii [caput breve] 77
 27 Tendo et bursa m. latissimi dorsi 27
 28 Tendo m. bicipitis brachii [caput longum] 77
 29 Humerus 77
 30 M. teres minor 77
 31 Trachea et a. anonyma 7
 32 N. cardiacus superior et lymphoglandula mediastinalis 7
 33 Discus articularis et m. sterniocondroideus 7
 34 N. vagus 7
 35 V. anonyma dextra 7
 36 N. phrenicus et a. mammaria interna 7
 37 Pulmo [lobus superior] 7
 38 Costa I et m. subclavius 7
 39 M. pectoralis major 7
 40 Fascia thoracalis 7
 41 M. intercostalis externus 12
 42 M. intercostalis internus 23
 43 Costa II 23
 44 N. thoracalis longus 23
 45 V. axillaris 23
 46 N. thoracalis anterior et m. pectoralis minor 23
 47 N. thoracodorsalis et v. subscapularis 23
 48 N. medianus 23
 49 A. axillaris et v. cephalica 29
 50 A. circumflexa humeri posterior 29
 51 M. coracobrachialis et m. biceps brachii 27
 52 Tendo et bursa m. latissimi dorsi 27
 53 Tendo m. bicipitis brachii [caput longum] 77
 54 Humerus 77
 55 M. teres minor 77
 56 M. deltoideus 77
 57 M. teres minor 77
 58 Panniculus adiposus 77
 59 Scapula [margo axillaris] 77
 60 M. infraspinatus 77
 61 N. ulnaris et n. radialis 61
 62 M. subscapularis 61
 63 Lymphoglandula axillaris 61
 64 N. thoracalis longus et axilla 61
 65 M. serratus anterior 61
 66 Costa II 61
 67 M. intercostalis externus 61
 68 Scapula [margo vertebralis] 61
 69 M. serratus posterior superior 61
 70 M. iliocostalis 61
 71 Pulmo [lobus inferior] 61
 72 Processus transversus [vert. thor. IV] 61
 73 Truncus sympathicus et v. intercostalis 61
 74 Processus articularis superior [vert. thor. IV] 61
 75 Lig. flavum 61
 76 Vertebra thoracalis III 61
 77 M. deltoideus 77
 78 M. teres minor 77
 79 Panniculus adiposus 77
 80 Scapula [margo axillaris] 77
 81 M. infraspinatus 77
 82 N. ulnaris et n. radialis 61
 83 M. subscapularis 61
 84 Lymphoglandula axillaris 61
 85 N. thoracalis longus et axilla 61
 86 M. serratus anterior 61
 87 Costa II 61
 88 M. intercostalis externus 61
 89 Scapula [margo vertebralis] 61
 90 M. serratus posterior superior 61
 91 M. iliocostalis 61
 92 Pulmo [lobus inferior] 61
 93 Processus transversus [vert. thor. IV] 61
 94 Truncus sympathicus et v. intercostalis 61
 95 Processus articularis superior [vert. thor. IV] 61
 96 Lig. flavum 61
 97 Vertebra thoracalis III 61
 98 M. serratus anterior 127
 99 N. thoracalis longus 127
 100 M. serratus anterior 127
 101 M. intercostalis externa 127
 102 Costa III 127
 103 M. intercostalis interna 127
 104 A et v. et n. intercostalis 127
 105 M. iliocostalis cervicis 127
 106 M. rhomboideus major 127
 107 Costa IV 127
 108 M. trapezius 127
 109 M. longissimus dorsi 127
 110 Processus transversus [vert. thor. IV] 127
 111 Truncus sympathicus et n. longissimus cervicis et capitis 127
 112 M. serratus dorsi et n. multifidus 127
 113 Cavum articulare et n. spinalis dorsi 127
 114 Vertebra thoracalis III 127

Section 23

Section 23

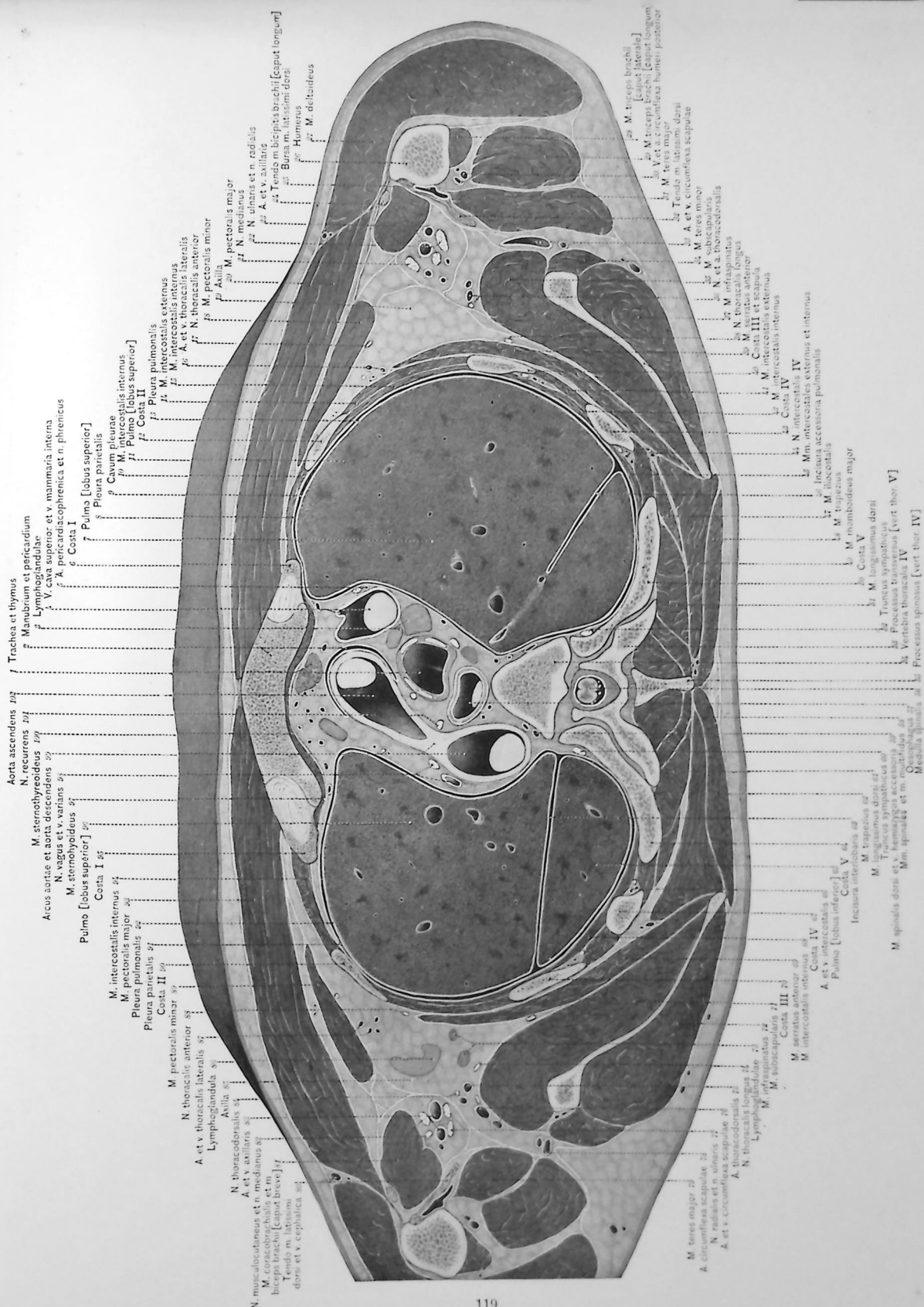
This section is about 25 mm. below the preceding section. Its level is indicated by line 23 in Key-figures IV, V, VI, VII. In order to bring this section within the plate, 3.2 cm. were cut off the original drawing on the left side.

The section passes through the middle of the fourth thoracic vertebra (54), and through the spinous process (55) of the same. It passes through the middle of the manubrium (2), and through the following ribs: the first (6, 95), the second (12, 90), the third (40, 70), the fourth (43, 67), and the vertebral ends of the fifth (50, 64). It passes near the middle of the scapula (40), and through the upper third of the humerus (26). The aortic arch (99) is cut along its lower border. The ascending (102) and descending (99) portions of the aorta are shown. The right and left pulmonary arteries take origin largely in the lower portion of this section. The superior vena cava and the point of entrance of the internal mammary vein, which usually enters the innominate vein, are shown at 4. The pericardium (2) is here reflected, and shows the upper portion of the pericardial cavity. The trachea (1) is largely to the right of the mesial plane; its bifurcation is indicated by the carina tracheæ, which is faintly shown and which lies opposite the fourth thoracic disc. The bronchi begin to subdivide in the body of this section. In the posterior portion of the right lung an accessory fissure (46) is shown. The inferior lobe of the right lung begins in the lower third of this section. Its upper margin lies at the level of the tip of the spinous process of the fourth thoracic vertebra, and also at the level of the middle of the neck of the sixth rib. The oblique fissure of the right lung begins at the neck of the fifth rib, opposite the lower portion of the fourth thoracic vertebra. Although the fissure begins somewhat lower in this subject than in the average, it is not infrequently found one vertebra lower in the right lung than in the left. The horizontal fissure is irregular; it lies in the lower portion of the section, opposite the second costal cartilage or the third intercostal space. The thymus gland (1) lies slightly to the right of the mesial plane, and is bilobed. The œsophagus (57) still lies slightly to the left of the mesial plane.

Note.—The *v. circumflexa scapulae* (33, 76) and *v. circumflexa humeri posterior* (30) are not given in the BNA. We have used these terms following Toldt, Spalteholtz and others.

There is present in this section a vein (*v. varians* 98) for which there is no name given in the BNA. It is designated by the English anatomists as the left superior intercostal vein. This vein is formed by the union of two or three of the upper intercostals. It crosses the arch of the aorta and opens into the left innominate vein within the body of the preceding section.

There is an accessory fissure in the right lung which we have labeled "*Incisura accessoria pulmonalis*" (46), although it is not given in the BNA.



Aorta ascendens 112
 N. recurrens 211
 M. sternohyoideus 179
 Acus aortae et aortae descendens 181
 N. vagus et v. varians 51
 M. sternohyoideus 51
 Pulmo [lobus superior] 52
 Costa I 52
 M. intercostalis internus 52
 M. pectoralis major 54
 Pleura pulmonalis 54
 Pleura parietalis 54
 Costa II 54
 M. pectoralis minor 54
 N. thoracalis anterior 54
 A. et v. thoracalis lateralis 54
 Lymphoglandula 54
 N. thoracodorsalis 54
 Axilla 54
 N. thoracodorsalis 54
 A. et v. ulnaris 54
 M. coracobrachialis et m. biceps brachii [caput breve] 54
 Tendo m. latissimi dorsi et v. cephalica 54
 M. teres major 54
 A. circumflexa scapulae 54
 N. radialis et n. ulnaris 54
 A. et v. circumflexa scapulae 54
 A. thoracodorsalis 54
 N. thoracalis longus 54
 Lympha 54
 M. infrascapularis 54
 M. teres minor 54
 Costa III 54
 M. serratus anterior 54
 M. intercostalis internus 54
 Costa IV 54
 A. et v. intercostalis 54
 Pulmo [lobus inferior] 54
 Costa V 54
 Incurva inferior 54
 M. latissimus 54
 M. longissimus dorsi 54
 Truncus sympathicus 54
 Mm. spinosus 54
 M. spinalis dorsi et v. hemiaxis anterior 54
 Mm. spinosus 54
 M. latissimus 54
 Medulla spinalis 54
 Processus spinosus [vert. thor. IV]

Trachea et thymus
 Manubrium et pericardium
 Lymphoglandulae et v. mammae interna
 V. v. pericardiocephalica et n. phrenicus
 Costa I
 Pulmo [lobus superior]
 Pleura parietalis
 Pleura pulmonalis
 Costa II
 Pulmo [lobus superior]
 M. pectoralis internus
 M. intercostalis internus
 M. intercostalis externus
 M. intercostalis lateralis
 A. et v. thoracalis anterior
 N. thoracalis anterior
 M. pectoralis minor
 Axilla
 M. pectoralis major
 N. medianus
 N. ulnaris et n. radialis
 A. et v. axillaris
 Tendo m. bicipitis brachii [caput longum]
 Bursa m. latissimi dorsi
 Humerus
 M. deltoideus

M. teres brachii [caput laterale]
 M. triceps brachii [caput longum]
 V. v. circumflexa humeri posterior
 M. teres major
 Tendo m. latissimi dorsi
 A. et v. circumflexa scapulae
 M. teres minor
 M. subscapularis
 M. infraspinatus
 M. teres major
 N. subscapularis
 N. thoracalis longus
 M. serratus anterior
 Costa III et scapula
 M. intercostalis internus
 Costa IV
 N. intercostalis IV
 Mm. intercostales externus et internus
 Incurva accessoria pulmonalis
 M. latissimus
 M. teres minor
 M. rhomboideus major
 Costa V
 M. longissimus dorsi
 Truncus sympathicus
 Processus spinosus [vert. thor. V]
 Vertebra thoracalis IV
 Quercubus
 Medulla spinalis
 Processus spinosus [vert. thor. IV]

M. teres major 54
 A. circumflexa scapulae 54
 N. radialis et n. ulnaris 54
 A. et v. circumflexa scapulae 54
 A. thoracodorsalis 54
 N. thoracalis longus 54
 Lympha 54
 M. infrascapularis 54
 M. teres minor 54
 Costa III 54
 M. serratus anterior 54
 M. intercostalis internus 54
 Costa IV 54
 A. et v. intercostalis 54
 Pulmo [lobus inferior] 54
 Costa V 54
 Incurva inferior 54
 M. latissimus 54
 M. longissimus dorsi 54
 Truncus sympathicus 54
 Mm. spinosus 54
 M. spinalis dorsi et v. hemiaxis anterior 54
 Mm. spinosus 54
 M. latissimus 54
 Medulla spinalis 54
 Processus spinosus [vert. thor. IV]

M. teres major 54
 A. circumflexa scapulae 54
 N. radialis et n. ulnaris 54
 A. et v. circumflexa scapulae 54
 A. thoracodorsalis 54
 N. thoracalis longus 54
 Lympha 54
 M. infrascapularis 54
 M. teres minor 54
 Costa III 54
 M. serratus anterior 54
 M. intercostalis internus 54
 Costa IV 54
 A. et v. intercostalis 54
 Pulmo [lobus inferior] 54
 Costa V 54
 Incurva inferior 54
 M. latissimus 54
 M. longissimus dorsi 54
 Truncus sympathicus 54
 Mm. spinosus 54
 M. spinalis dorsi et v. hemiaxis anterior 54
 Mm. spinosus 54
 M. latissimus 54
 Medulla spinalis 54
 Processus spinosus [vert. thor. IV]

M. teres major 54
 A. circumflexa scapulae 54
 N. radialis et n. ulnaris 54
 A. et v. circumflexa scapulae 54
 A. thoracodorsalis 54
 N. thoracalis longus 54
 Lympha 54
 M. infrascapularis 54
 M. teres minor 54
 Costa III 54
 M. serratus anterior 54
 M. intercostalis internus 54
 Costa IV 54
 A. et v. intercostalis 54
 Pulmo [lobus inferior] 54
 Costa V 54
 Incurva inferior 54
 M. latissimus 54
 M. longissimus dorsi 54
 Truncus sympathicus 54
 Mm. spinosus 54
 M. spinalis dorsi et v. hemiaxis anterior 54
 Mm. spinosus 54
 M. latissimus 54
 Medulla spinalis 54
 Processus spinosus [vert. thor. IV]

M. teres major 54
 A. circumflexa scapulae 54
 N. radialis et n. ulnaris 54
 A. et v. circumflexa scapulae 54
 A. thoracodorsalis 54
 N. thoracalis longus 54
 Lympha 54
 M. infrascapularis 54
 M. teres minor 54
 Costa III 54
 M. serratus anterior 54
 M. intercostalis internus 54
 Costa IV 54
 A. et v. intercostalis 54
 Pulmo [lobus inferior] 54
 Costa V 54
 Incurva inferior 54
 M. latissimus 54
 M. longissimus dorsi 54
 Truncus sympathicus 54
 Mm. spinosus 54
 M. spinalis dorsi et v. hemiaxis anterior 54
 Mm. spinosus 54
 M. latissimus 54
 Medulla spinalis 54
 Processus spinosus [vert. thor. IV]

M. teres major 54
 A. circumflexa scapulae 54
 N. radialis et n. ulnaris 54
 A. et v. circumflexa scapulae 54
 A. thoracodorsalis 54
 N. thoracalis longus 54
 Lympha 54
 M. infrascapularis 54
 M. teres minor 54
 Costa III 54
 M. serratus anterior 54
 M. intercostalis internus 54
 Costa IV 54
 A. et v. intercostalis 54
 Pulmo [lobus inferior] 54
 Costa V 54
 Incurva inferior 54
 M. latissimus 54
 M. longissimus dorsi 54
 Truncus sympathicus 54
 Mm. spinosus 54
 M. spinalis dorsi et v. hemiaxis anterior 54
 Mm. spinosus 54
 M. latissimus 54
 Medulla spinalis 54
 Processus spinosus [vert. thor. IV]

M. teres major 54
 A. circumflexa scapulae 54
 N. radialis et n. ulnaris 54
 A. et v. circumflexa scapulae 54
 A. thoracodorsalis 54
 N. thoracalis longus 54
 Lympha 54
 M. infrascapularis 54
 M. teres minor 54
 Costa III 54
 M. serratus anterior 54
 M. intercostalis internus 54
 Costa IV 54
 A. et v. intercostalis 54
 Pulmo [lobus inferior] 54
 Costa V 54
 Incurva inferior 54
 M. latissimus 54
 M. longissimus dorsi 54
 Truncus sympathicus 54
 Mm. spinosus 54
 M. spinalis dorsi et v. hemiaxis anterior 54
 Mm. spinosus 54
 M. latissimus 54
 Medulla spinalis 54
 Processus spinosus [vert. thor. IV]

M. teres major 54
 A. circumflexa scapulae 54
 N. radialis et n. ulnaris 54
 A. et v. circumflexa scapulae 54
 A. thoracodorsalis 54
 N. thoracalis longus 54
 Lympha 54
 M. infrascapularis 54
 M. teres minor 54
 Costa III 54
 M. serratus anterior 54
 M. intercostalis internus 54
 Costa IV 54
 A. et v. intercostalis 54
 Pulmo [lobus inferior] 54
 Costa V 54
 Incurva inferior 54
 M. latissimus 54
 M. longissimus dorsi 54
 Truncus sympathicus 54
 Mm. spinosus 54
 M. spinalis dorsi et v. hemiaxis anterior 54
 Mm. spinosus 54
 M. latissimus 54
 Medulla spinalis 54
 Processus spinosus [vert. thor. IV]

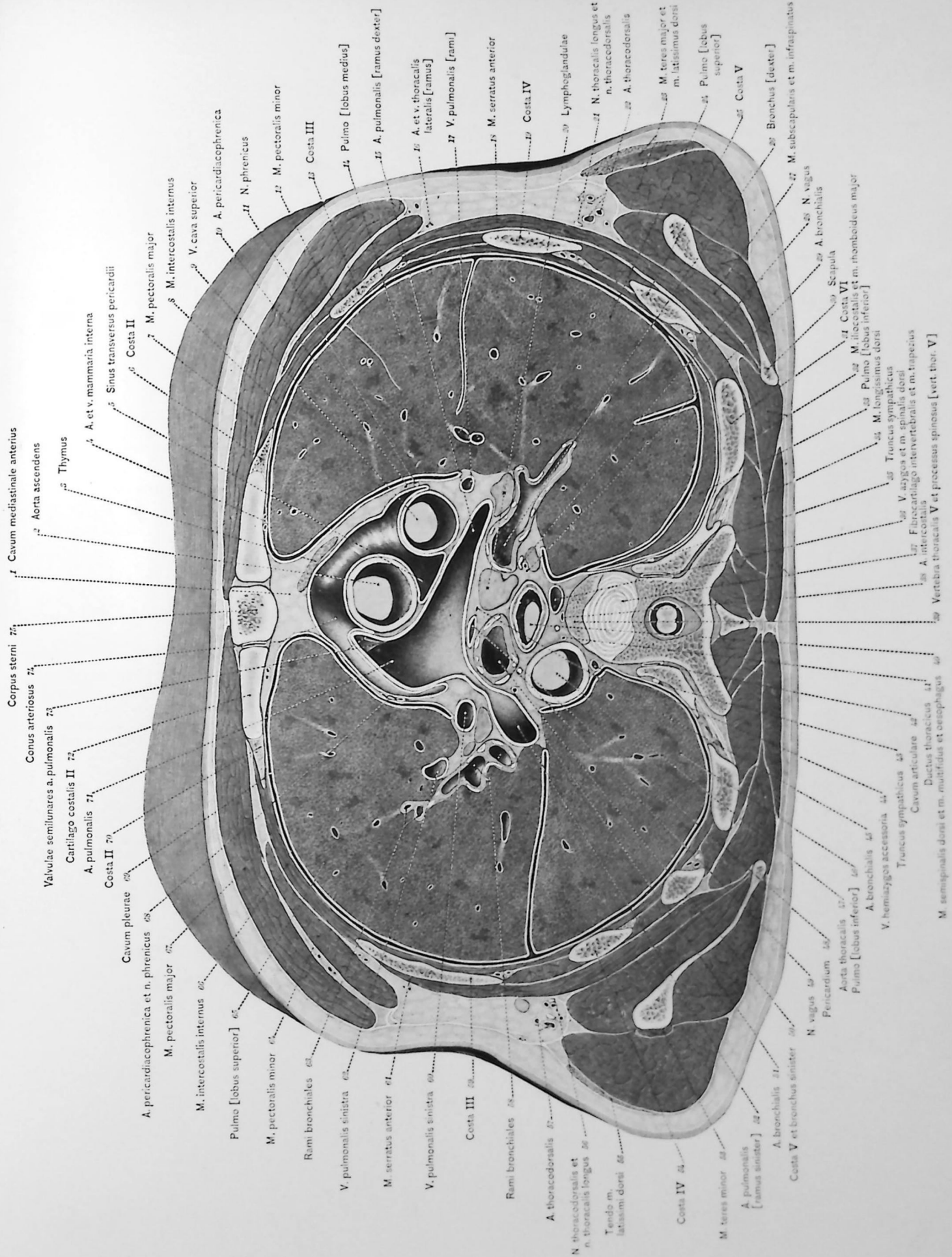
Section 24

Section 24

This section is about 24 mm. below the preceding section. Its level is indicated by line 24 in Key-figures IV, V, VI, VII.

The section passes just above the fifth thoracic disc (37), and cuts off a thin plate of bone from the lower margin of the fifth thoracic vertebra (39), and also cuts through the upper margin of the sixth thoracic vertebra. It passes just below the manubrio-gladiolar junction, through the sternal ends of the second ribs (6, 70) and costal cartilages (72) of the same. The infraspinatus muscle does not extend below this section, while the teres minor (53) disappears on the left in the body of the section. The ascending (2) and descending (47) portions of the aorta are shown. The thoracic aorta is that portion of the aorta which lies between the fourth thoracic vertebra and the diaphragm. The superior vena cava (9) enters the heart in the lower portion of this section and the upper portion of the next section. The pulmonary valves (73) are shown deep down in the pulmonary artery (71). The valves lie at the level of the lower portion of the sixth thoracic vertebra, opposite the second intercostal space, being somewhat higher than usual. The center of the pulmonary valve lies about 8 mm. to the left of the median plane and in a paraxial plane, passing through the left margin of the sternum. The auricular appendages lie almost wholly within the section. The upper portion of the left auricle lies in the lower portion of this section. The conus arteriosus (74) lies in this section. The trachea has bifurcated in the section above and the large bronchi (26, 50) are prominent. The accessory fissure in the posterior portion of the right lung disappears in the body of this section. The horizontal fissure is opposite the third intercostal space. The left lobe of the thymus gland does not extend into this section, but the right lobe (3) extends to the middle of this section. The œsophagus at this level lies precisely in the median line. A number of lymph glands (20) are shown.

Note.—The A. thoracodorsalis (22, 57) has an accompanying vein which we have shown but not labeled, since it is not given in the BNA



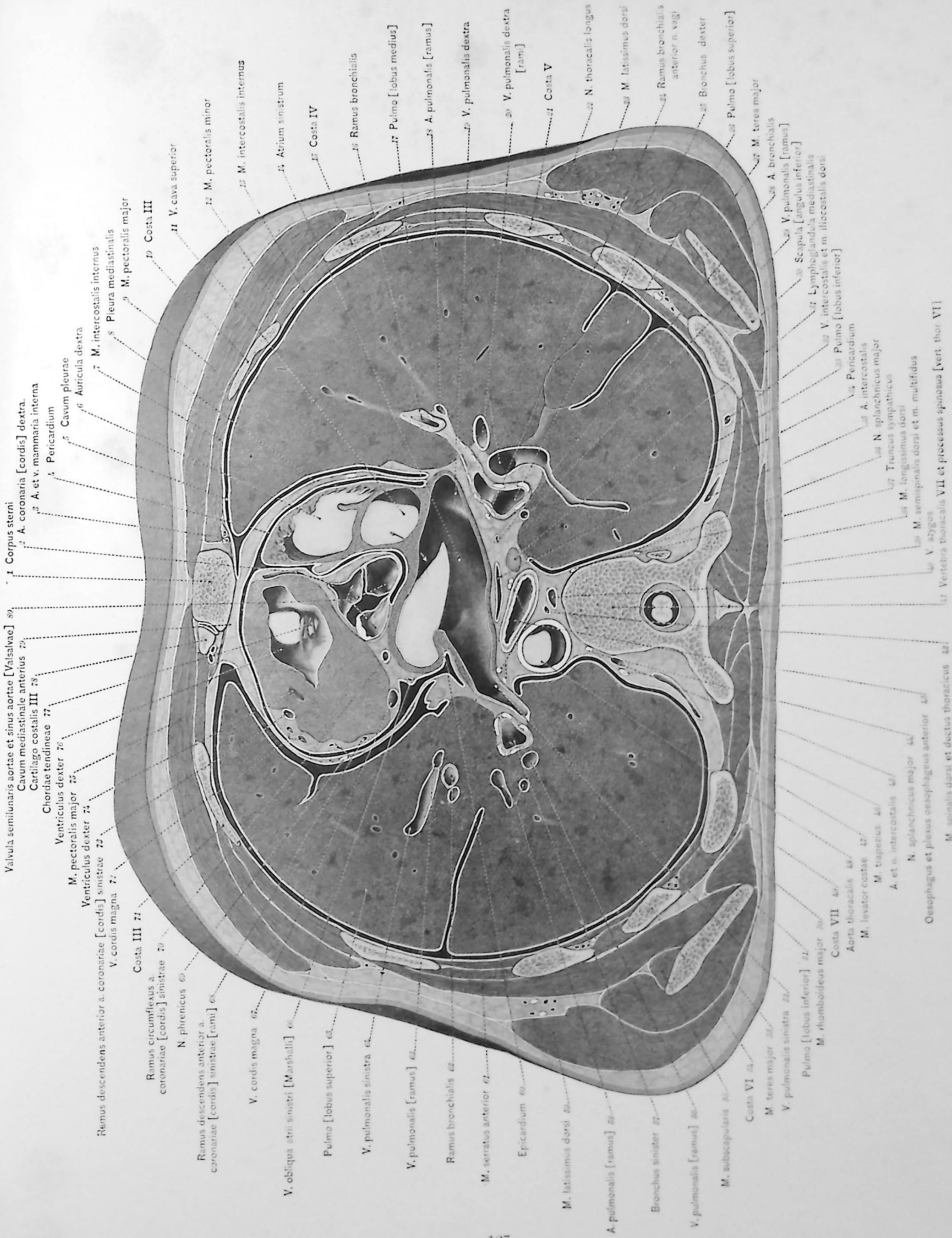
- 1 Cavum mediastinale anterius
- 2 Aorta ascendens
- 3 Thymus
- 4 A. et v. mammaria interna
- 5 Sinus transversus pericardii
- 6 Costa II
- 7 M. pectoralis major
- 8 M. intercostalis internus
- 9 V. cava superior
- 10 A. pericardiophrenica
- 11 N. phrenicus
- 12 M. pectoralis minor
- 13 Costa III
- 14 Pulmo [lobus medius]
- 15 A. pulmonalis [ramus dexter]
- 16 A. et v. thoracalis lateralis [ramus]
- 17 V. pulmonalis [rami]
- 18 M. serratus anterior
- 19 Costa IV
- 20 Lymphoglandulae
- 21 N. thoracalis longus et n. thoracodorsalis
- 22 A. thoracodorsalis
- 23 M. teres major et m. latissimus dorsi
- 24 Pulmo [lobus superior]
- 25 Costa V
- 26 Bronchus [dexter]
- 27 M. subscapularis et m. infraspinatus
- 28 N. vagus
- 29 A. bronchialis
- 30 Scapula
- 31 Costa VI
- 32 M. iliopectoralis et m. rhomboideus major
- 33 Pulmo [lobus inferior]
- 34 M. longissimus dorsi
- 35 Truncus sympathicus
- 36 V. azygos et m. spinalis dorsi
- 37 Fibrocartilago intervertebralis et m. trapezius
- 38 A. intercostalis V et processus spinosus [vert. thor. V]
- 39 Vertebra thoracalis V
- 40 M. semispinalis dorsi et m. multifidus et oesophagus
- 41 Ductus thoracicus
- 42 Cavum articulare
- 43 Truncus sympathicus
- 44 V. hemiazygos accessoria
- 45 A. bronchialis
- 46 A. bronchialis
- 47 Pulmo [lobus inferior]
- 48 Pericardium
- 49 N. vagus
- 50 A. bronchialis
- 51 A. bronchialis
- 52 Pulmo [lobus sinister]
- 53 A. bronchialis
- 54 Costa V et bronchus sinister
- 55 M. teres minor
- 56 Costa IV
- 57 Tendo m. latissimi dorsi
- 58 A. thoracodorsalis et n. thoracalis longus
- 59 Rami bronchiales
- 60 V. pulmonalis sinistra
- 61 M. serratus anterior
- 62 V. pulmonalis sinistra
- 63 Costa III
- 64 Rami bronchiales
- 65 Pulmo [lobus superior]
- 66 M. intercostalis internus
- 67 M. pectoralis major
- 68 A. pericardiophrenica et n. phrenicus
- 69 Cavum pleurae
- 70 Costa II
- 71 A. pulmonalis
- 72 Cartilago costalis II
- 73 Valvulae semilunares a. pulmonalis
- 74 Conus arteriosus
- 75 Corpus sterni
- 76 Cavum mediastinale anterius

Section 25

Section 25

This section is about 24 mm. below the preceding section. Its level is indicated by line 25 in Key-figures IV, V, VI, VII.

The section passes through the upper part of the seventh thoracic vertebra (41) and through the spinous process (41) of the sixth; through the upper margin of the sternal end of the third costal cartilage (78) on the left side; through the following ribs: the third (10), the fourth (15), the fifth (21), the sixth (54), and the seventh (49). It cuts the scapula (30) about 12 mm. above its inferior angle. The vertebral ends of the eighth ribs lie within the section. The following muscles do not extend below this section: the *teres major* (27, 53), the *rhomboideus major* (50), and the *subscapularis* (55). The right auricle (6) is shown at the level of the entrance of the superior vena cava (11). The left auricle (14) is cut just below the point of entrance of the right superior pulmonary vein (19). The right inferior pulmonary vein enters the auricle within the section. The left superior pulmonary vein (52) is cut at its point of entrance into the left auricle. The left inferior pulmonary vein enters the left auricle within the section. The foramen ovale is not completely closed, and is indicated by an arrow in the drawing. The anterior semilunar valve (80) of the aorta and sinuses of Valsalva (80) are shown. The aortic valve lies opposite the seventh thoracic vertebra, directly behind the sternum, and opposite the lower portion of the second interspace and the third costal cartilage. The right ventricle is cut (76), showing the tendinous cords (77) which are attached to the tricuspid valve (*valvula tricuspidalis*). The pulmonary valve lies for the most part above and to the left, but slightly overlaps the aortic valve. The mitral valve (*valvula bicuspidalis*) lies partly in this and partly in the succeeding section. It lies opposite the eighth thoracic vertebra. Its mesial margin lies in the mid-plane, while its lateral margin is 1.5 cm. to the left of the mid-plane. The right coronary artery (2) is shown in the section where it arises from the anterior portion of the aortic sinus in front of the anterior cusp of the semilunar valve. The upper lobe of the right lung (26) does not extend below this section. The horizontal fissure begins in the upper portion of this section at the level of the sixth rib in the axillary line.



Valvula semilunaris aortae et sinus aortae [Valsalvae] 89
 Cavum mediastinale anterius 74
 Cartilago costalis III 78
 Chordae tendineae 77
 Ventriculus dexter 76
 M. pectoralis major 75
 Ventriculus dexter 74
 Ventriculus [cordis] sinistrae 73
 V. cordis magna 72
 Costa III 71
 Ramus circumflexus a. coronariae [cordis] sinistrae 70
 N. phrenicus 69
 Ramus descendens anterior a. coronariae [cordis] sinistrae [ram.] 68
 V. cordis magna 67
 V. obliquus atri sinistri [Marshalli] 66
 Pulmo [lobus superior] 65
 V. pulmonalis sinistra 64
 V. pulmonalis [ramus] 63
 Ramus bronchialis 62
 M. serratus anterior 61
 Epicardium 60
 M. latissimus dorsi 59
 A. pulmonalis [ramus] 58
 Bronchus sinister 57
 V. pulmonalis [ramus] 56
 M. subcapularis 55
 Costa VI 54
 M. teres major 53
 V. pulmonalis sinistra 52
 Pulmo [lobus inferior] 51
 M. rhomboideus major 50
 Costa VII 49
 Aorta thoracalis 48
 M. levator costae 47
 M. trapezius 46
 A. et n. intercostalis 45
 N. splanchnicus major 44
 Oesophagus et plexus oesophageus anterior 43
 M. spinalis dorsi et dactus thoracicus 42

1 Corpus sterni
 2 A. coronaria [cordis] dextra.
 3 A. et v. mammaria interna
 4 Pericardium
 5 Cavum pleurae
 6 Auricula dextra
 7 M. intercostalis internus
 8 Pleura mediastinalis
 9 M. pectoralis major
 10 Costa III
 11 V. cava superior
 12 M. pectoralis minor
 13 M. intercostalis internus
 14 Atrium sinistrum
 15 Costa IV
 16 Ramus bronchialis
 17 Pulmo [lobus medius]
 18 A. pulmonalis [ramus]
 19 V. pulmonalis dextra
 20 V. pulmonalis dextra [ram.]
 21 Costa V
 22 N. thoracalis longus
 23 M. latissimus dorsi
 24 Ramus bronchialis anterior n. vagi
 25 Bronchus dexter
 26 Pulmo [lobus superior]
 27 M. teres major
 28 A. bronchialis
 29 V. pulmonalis [ramus]
 30 Scapula [angulus inferior]
 31 Lymphoglandula mediastinalis
 32 V. intercostalis et m. intercostalis dorsi
 33 Pulmo [lobus inferior]
 34 Pericardium
 35 A. intercostalis
 36 N. splanchnicus major
 37 Truncus sympathicus
 38 M. longissimus dorsi
 39 M. semispinalis dorsi et m. multifidus
 40 V. azygos
 41 Vertebra thoracalis VII. et processus spinosus [vert. thor. VI]

18 A. pulmonalis [ramus]
 19 V. pulmonalis dextra
 20 V. pulmonalis dextra [ram.]
 21 Costa V
 22 N. thoracalis longus
 23 M. latissimus dorsi
 24 Ramus bronchialis anterior n. vagi
 25 Bronchus dexter
 26 Pulmo [lobus superior]
 27 M. teres major
 28 A. bronchialis
 29 V. pulmonalis [ramus]
 30 Scapula [angulus inferior]
 31 Lymphoglandula mediastinalis
 32 V. intercostalis et m. intercostalis dorsi
 33 Pulmo [lobus inferior]
 34 Pericardium
 35 A. intercostalis
 36 N. splanchnicus major
 37 Truncus sympathicus
 38 M. longissimus dorsi
 39 M. semispinalis dorsi et m. multifidus
 40 V. azygos
 41 Vertebra thoracalis VII. et processus spinosus [vert. thor. VI]

18 A. pulmonalis [ramus]
 19 V. pulmonalis dextra
 20 V. pulmonalis dextra [ram.]
 21 Costa V
 22 N. thoracalis longus
 23 M. latissimus dorsi
 24 Ramus bronchialis anterior n. vagi
 25 Bronchus dexter
 26 Pulmo [lobus superior]
 27 M. teres major
 28 A. bronchialis
 29 V. pulmonalis [ramus]
 30 Scapula [angulus inferior]
 31 Lymphoglandula mediastinalis
 32 V. intercostalis et m. intercostalis dorsi
 33 Pulmo [lobus inferior]
 34 Pericardium
 35 A. intercostalis
 36 N. splanchnicus major
 37 Truncus sympathicus
 38 M. longissimus dorsi
 39 M. semispinalis dorsi et m. multifidus
 40 V. azygos
 41 Vertebra thoracalis VII. et processus spinosus [vert. thor. VI]

18 A. pulmonalis [ramus]
 19 V. pulmonalis dextra
 20 V. pulmonalis dextra [ram.]
 21 Costa V
 22 N. thoracalis longus
 23 M. latissimus dorsi
 24 Ramus bronchialis anterior n. vagi
 25 Bronchus dexter
 26 Pulmo [lobus superior]
 27 M. teres major
 28 A. bronchialis
 29 V. pulmonalis [ramus]
 30 Scapula [angulus inferior]
 31 Lymphoglandula mediastinalis
 32 V. intercostalis et m. intercostalis dorsi
 33 Pulmo [lobus inferior]
 34 Pericardium
 35 A. intercostalis
 36 N. splanchnicus major
 37 Truncus sympathicus
 38 M. longissimus dorsi
 39 M. semispinalis dorsi et m. multifidus
 40 V. azygos
 41 Vertebra thoracalis VII. et processus spinosus [vert. thor. VI]

18 A. pulmonalis [ramus]
 19 V. pulmonalis dextra
 20 V. pulmonalis dextra [ram.]
 21 Costa V
 22 N. thoracalis longus
 23 M. latissimus dorsi
 24 Ramus bronchialis anterior n. vagi
 25 Bronchus dexter
 26 Pulmo [lobus superior]
 27 M. teres major
 28 A. bronchialis
 29 V. pulmonalis [ramus]
 30 Scapula [angulus inferior]
 31 Lymphoglandula mediastinalis
 32 V. intercostalis et m. intercostalis dorsi
 33 Pulmo [lobus inferior]
 34 Pericardium
 35 A. intercostalis
 36 N. splanchnicus major
 37 Truncus sympathicus
 38 M. longissimus dorsi
 39 M. semispinalis dorsi et m. multifidus
 40 V. azygos
 41 Vertebra thoracalis VII. et processus spinosus [vert. thor. VI]

18 A. pulmonalis [ramus]
 19 V. pulmonalis dextra
 20 V. pulmonalis dextra [ram.]
 21 Costa V
 22 N. thoracalis longus
 23 M. latissimus dorsi
 24 Ramus bronchialis anterior n. vagi
 25 Bronchus dexter
 26 Pulmo [lobus superior]
 27 M. teres major
 28 A. bronchialis
 29 V. pulmonalis [ramus]
 30 Scapula [angulus inferior]
 31 Lymphoglandula mediastinalis
 32 V. intercostalis et m. intercostalis dorsi
 33 Pulmo [lobus inferior]
 34 Pericardium
 35 A. intercostalis
 36 N. splanchnicus major
 37 Truncus sympathicus
 38 M. longissimus dorsi
 39 M. semispinalis dorsi et m. multifidus
 40 V. azygos
 41 Vertebra thoracalis VII. et processus spinosus [vert. thor. VI]

18 A. pulmonalis [ramus]
 19 V. pulmonalis dextra
 20 V. pulmonalis dextra [ram.]
 21 Costa V
 22 N. thoracalis longus
 23 M. latissimus dorsi
 24 Ramus bronchialis anterior n. vagi
 25 Bronchus dexter
 26 Pulmo [lobus superior]
 27 M. teres major
 28 A. bronchialis
 29 V. pulmonalis [ramus]
 30 Scapula [angulus inferior]
 31 Lymphoglandula mediastinalis
 32 V. intercostalis et m. intercostalis dorsi
 33 Pulmo [lobus inferior]
 34 Pericardium
 35 A. intercostalis
 36 N. splanchnicus major
 37 Truncus sympathicus
 38 M. longissimus dorsi
 39 M. semispinalis dorsi et m. multifidus
 40 V. azygos
 41 Vertebra thoracalis VII. et processus spinosus [vert. thor. VI]

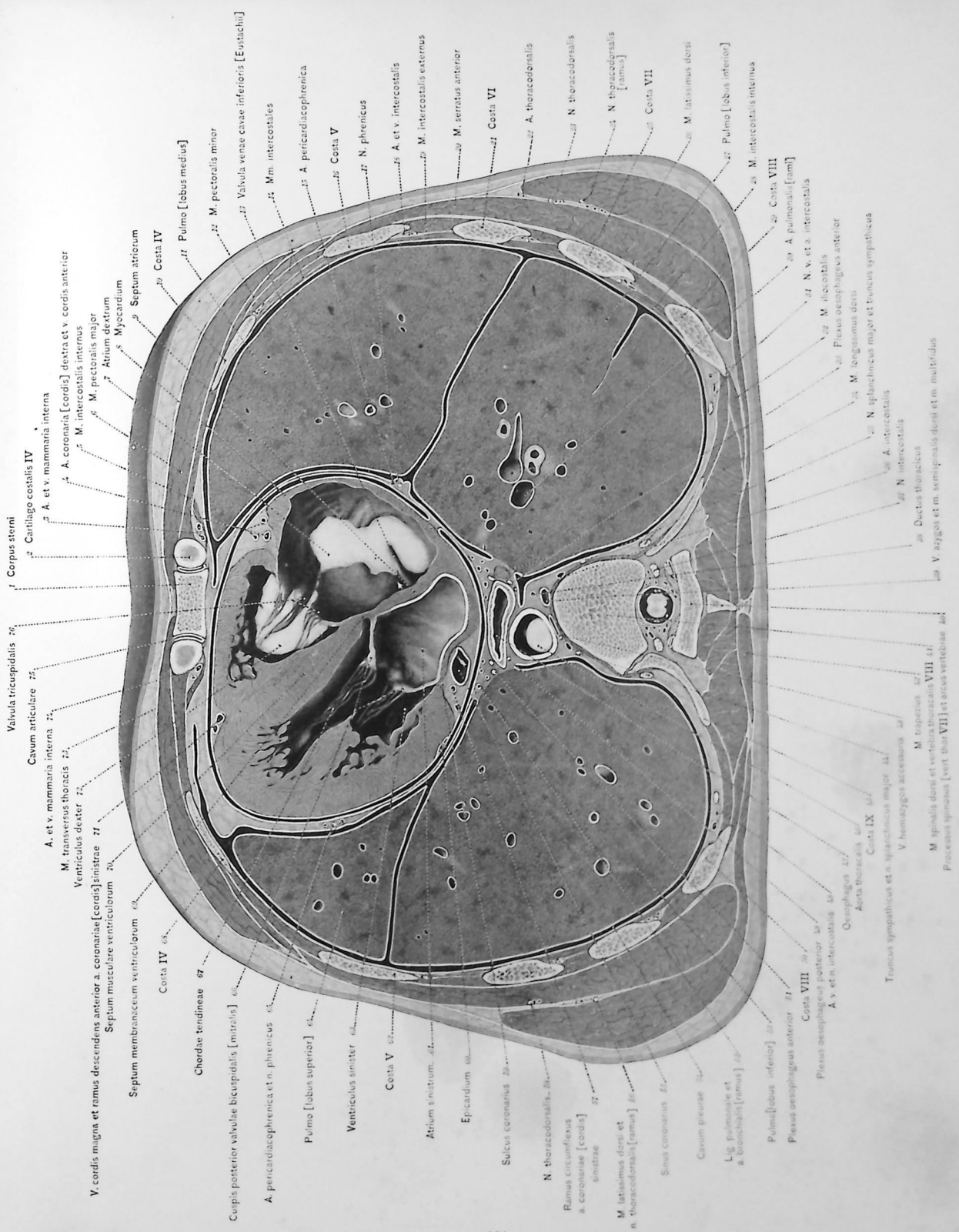18 A. pulmonalis [ramus]
 19 V. pulmonalis dextra
 20 V. pulmonalis dextra [ram.]
 21 Costa V
 22 N. thoracalis longus
 23 M. latissimus dorsi
 24 Ramus bronchialis anterior n. vagi
 25 Bronchus dexter
 26 Pulmo [lobus superior]
 27 M. teres major
 28 A. bronchialis
 29 V. pulmonalis [ramus]
 30 Scapula [angulus inferior]
 31 Lymphoglandula mediastinalis
 32 V. intercostalis et m. intercostalis dorsi
 33 Pulmo [lobus inferior]
 34 Pericardium
 35 A. intercostalis
 36 N. splanchnicus major
 37 Truncus sympathicus
 38 M. longissimus dorsi
 39 M. semispinalis dorsi et m. multifidus
 40 V. azygos
 41 Vertebra thoracalis VII. et processus spinosus [vert. thor. VI]

Section 26

Section 26

This section is about 26 mm. below the preceding section. Its level is indicated by line 26 in Key-figures IV, V, VI, VII.

The section passes through the middle of the eighth thoracic vertebra (41), the arch of the eighth (40) and the spinous process (40) of the seventh thoracic vertebra; through the fourth costal cartilage (2) at its sternal end; through the following ribs: the fourth (10, 68) near the costochondral junction; the fifth (16, 62), the sixth (21), the seventh (25), the eighth (29, 50), and the upper margin of the ninth (45) close to its vertebral end. The pectoralis minor (12) muscle does not extend below this section. The diaphragm extends into the lower portion of this section. The section passes through the heart, and shows the right (7) and left (61) auricles, also the right (72) and the left (63) ventricles. The opening of the inferior vena cava into the right auricle is in the lower portion of this section, opposite the lower portion of the ninth thoracic vertebra. The Eustachian valve (13) of the orifice of the inferior vena cava is fairly well developed in this subject. The tricuspid valve (76), between the right auricle and right ventricle, lies nearly opposite the lower portion of the eighth and the upper portion of the ninth thoracic vertebra. The mitral valve (66), between the left auricle and left ventricle, extends 2.5 cm. to the left of the median line, and is nearly at the level of the middle of the eighth thoracic vertebra. The coronary sinus (55), and its opening into the right auricle, are shown by the arrow. The œsophagus (47) lies slightly to the left of the median line. On either side the ligamentum pulmonale (53) is shown.



1. Corpus sterni
 2. Catilago costalis IV
 3. A. et v. mammaria interna
 4. A. coronaria [cordis] dextra et v. cordis anterior
 5. M. intercostalis internus
 6. M. pectoralis major
 7. Atrium dextrum
 8. Myocardium
 9. Septum atrierum
 10. Septum membranicum ventriculorum
 11. Pulmo [lobus medius]
 12. M. pectoralis minor
 13. Valvula venae cavae inferioris [Eustachii]
 14. Mm. intercostales
 15. A. pericardiophrenica
 16. Costa V
 17. N. phrenicus
 18. A. et v. intercostalis
 19. M. intercostalis externus
 20. M. serratus anterior
 21. Costa VI
 22. A. thoracodorsalis
 23. N. thoracodorsalis
 24. N. thoracodorsalis [ramus]
 25. Costa VII
 26. M. latissimus dorsi
 27. Pulmo [lobus inferior]
 28. M. intercostalis internus
 29. Costa VIII
 30. A. pulmonalis [ramus]
 31. N. v. et a. intercostalis
 32. M. ribocostalis
 33. Plexus oesophageus anterior
 34. M. longissimus dorsi
 35. M. splanchicus major et truncus sympathicus
 36. N. intercostalis
 37. A. intercostalis
 38. N. intercostalis
 39. Ductus thoracicus
 40. V. azygos et m. semispinalis dorsi et m. multifidus
 41. Truncus sympathicus et v. splanchicus major
 42. V. homazygos accessoria
 43. M. diaphragmatis
 44. M. spinalis dorsi et vertebrae thoracalis VIII
 45. Processus spinosus [vert. thor. VII] et arcus vertebrae
 46.

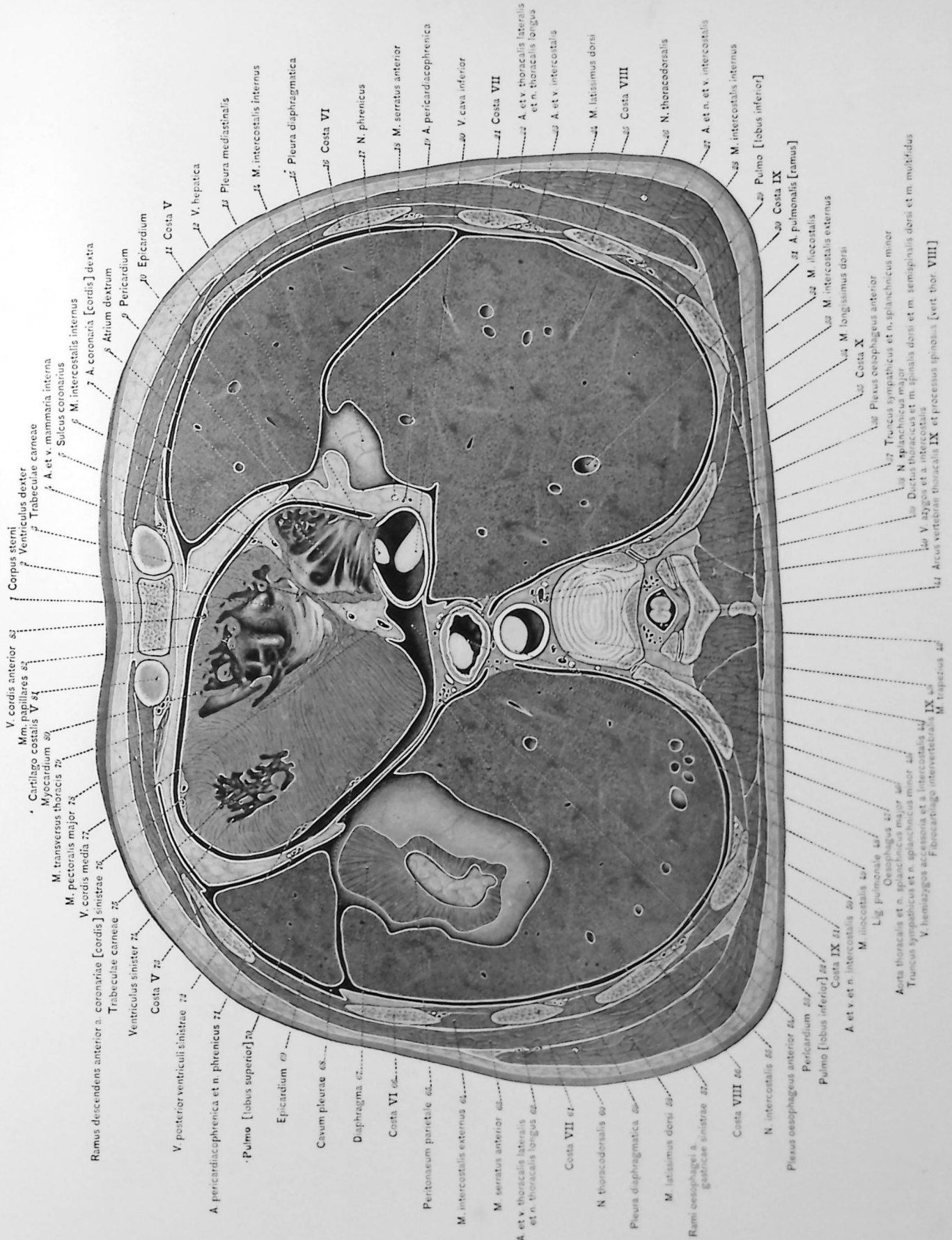
1. Valvula tricuspidalis
 2. Cavum articulare
 3. A. et v. mammaria interna
 4. M. transversus thoracis
 5. Ventriculus dexter
 6. V. cordis magna et ramus descendens anterior a. coronariae [cordis] sinistrae
 7. Septum musculare ventriculorum
 8. Septum membranicum ventriculorum
 9. Costa IV
 10. Chordae tendinae
 11. Curpa posterior valvulae bicupidalis [mitralis]
 12. A. pericardiophrenica et n. phrenicus
 13. Pulmo [lobus superior]
 14. Ventriculus sinister
 15. Costa V
 16. Atrium sinistrum
 17. Epicardium
 18. Sulcus coronarius
 19. N. thoracodorsalis
 20. Ramus circumflexus a. coronariae [cordis] sinistrae
 21. M. latissimus dorsi et n. thoracodorsalis [ramus]
 22. Sinus coronarius
 23. Cavum pleurae
 24. L.g. pulmonare et a. bronchialis [ramus]
 25. Pulmo [lobus inferior]
 26. Plexus oesophageus anterior
 27. Costa VIII
 28. Plexus oesophageus posterior
 29. A. v. et n. intercostalis
 30. Oesophagus
 31. Aorta thoracalis
 32. Costa IX
 33. Truncus sympathicus et v. splanchicus major
 34. V. homazygos accessoria
 35. M. diaphragmatis
 36. M. spinalis dorsi et vertebrae thoracalis VIII
 37. Processus spinosus [vert. thor. VII] et arcus vertebrae

Section 27

Section 27

This section is about 24 mm. below the preceding section. Its level is indicated by line 27 in Key-figures IV, V, VI, VII.

The section passes through the upper margin of the ninth intervertebral disc (43) and the arch of the ninth thoracic vertebra (41); through the superior articular processes of the tenth thoracic vertebra and the spinous process of the eighth thoracic vertebra (41). It passes through the sternal ends of the fifth costal cartilage (81); through the gladiolus (1) about 25 mm. above its inferior margin; through the fifth rib (11, 73) a short distance beyond the distal end of its costal cartilage; through the following ribs: the sixth (16, 66), the seventh (21, 61), the eighth (25, 56), the ninth (30, 51), and the vertebral ends of the tenth (35). On the right side the pleural surface of the diaphragm (15) is shown. On the left (67) the diaphragm is cut obliquely, showing its muscular fibers. Just below the parietal peritoneum (65) which covers the lower surface of the diaphragm there is exposed a considerable layer of fatty tissue. The right auricle (8) and the right (2) and left (74) ventricles are cut by this section. The auricle shows numerous muscoli pectinati, and the ventricles the muscoli papillares (82) and trabeculae carneae (3, 75). The pericardium (9), the epicardium (10), and the enclosed space (pericardial cavity) containing the pericardial fluid are shown. In the lower portion of the section the hepatic vein (12) enters the inferior vena cava (20). The apex of the heart is in the lower portion of this section. It lies in the mammillary line opposite the fifth intercostal space. The oesophagus lies to the left of the mesial plane. Its opening in the diaphragm lies in the lower part of this section and the upper part of the section below. The highest level of the fundus of the stomach is less than 1 cm. below the surface of this section, at the level of the ninth thoracic disc. The lesser peritoneal cavity extends into this section. The highest portion of the liver lies in this section opposite the upper third of the tenth thoracic vertebra. In the mammillary line it lies at the level of the upper margin of the fifth rib. In the parasternal line it is opposite the fourth intercostal space. The upper margin of the spleen lies some 4 mm. below the surface of this section at the level of the ninth intervertebral disc. In the scapular line its upper margin lies opposite the ninth rib.

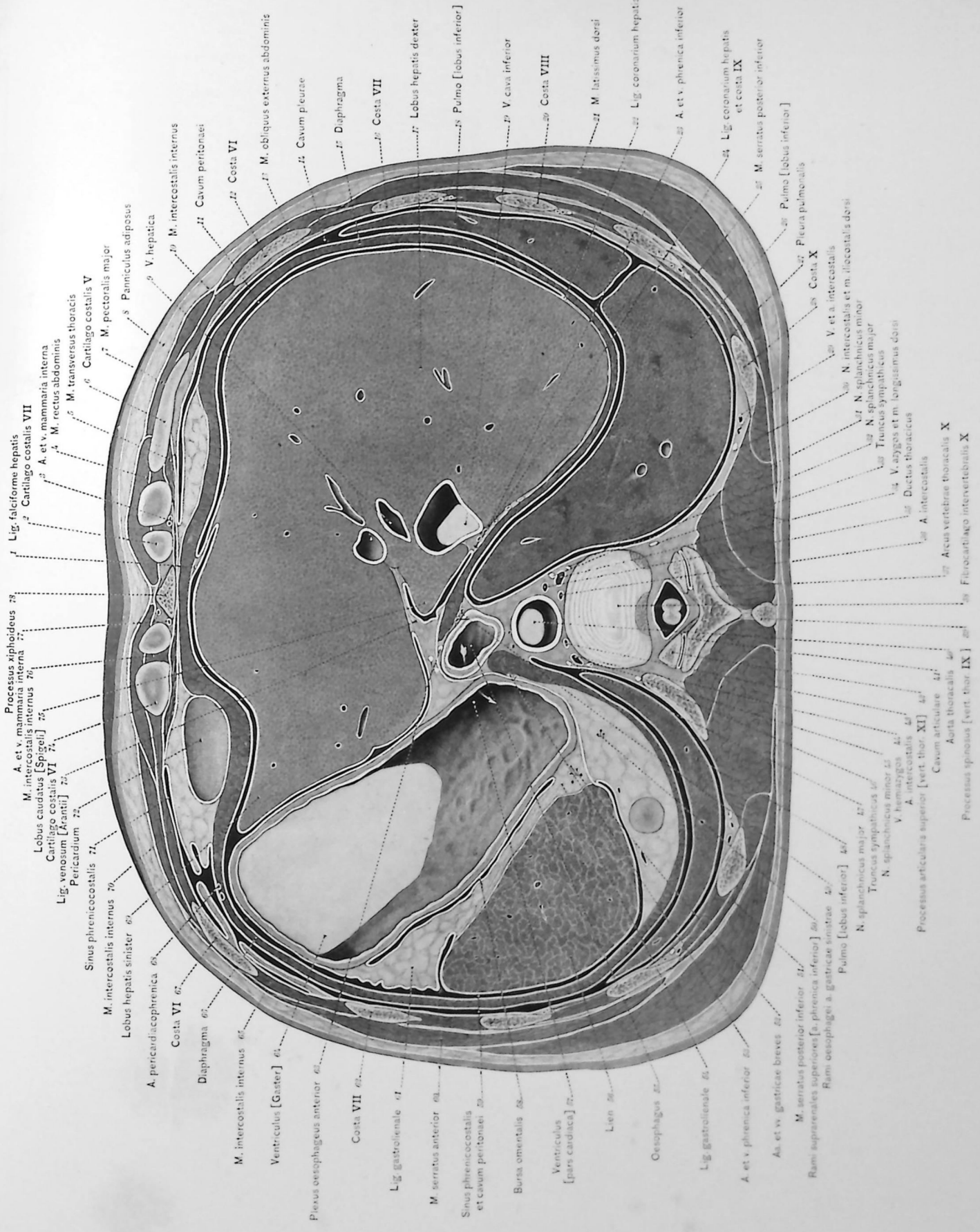

Section 28

Section 28

This section is about 27 mm. below the preceding section. Its level is indicated by line 28 in Key-figures IV, V, VI, VII.

The section passes through the tenth intervertebral disc (38), and cuts off a thin plate of the body of the tenth thoracic vertebra posteriorly. It passes through the arch of the tenth thoracic vertebra (37); through the superior articular processes of the eleventh (42) and the tip of the spinous process (39) of the ninth thoracic vertebra. Anteriorly it passes through the lower margin of the fifth costal cartilage (6); through the sixth (74) a short distance from the sternum, and through the sternal ends of the seventh (2). It cuts the following ribs: the sixth (12, 67), the seventh (16, 62), the eighth (20), the ninth (24), and the tenth (28). On the left it cuts the superior margin of the vertebral end of the eleventh rib, and on the right this end of the rib lies wholly within the section. The following muscles first appear in this section: the rectus abdominis (4), the obliquus externus (13), and the serratus posterior inferior (25). The pectoralis major muscle (7) does not extend beyond this section. The lowest portion of the pericardium (72) lies opposite the fifth intercostal space. The splenic artery enters the spleen within this section and the splenic vein emerges. The abdominal portion of the œsophagus lies entirely to the left of the mesial line and opens into the stomach through the cardiac orifice (shown by arrow). It is opposite the upper third of the eleventh thoracic vertebra. Its level anteriorly is about 2 cm. to the left and below the sternal end of the seventh costal cartilage and opposite the sixth intercostal space. The maximal extension of the liver on the left is to the mammillary line. The coronary ligament (22, 24), is cut at two points. The falciform ligament (1) extends into the section above. The upper border of the tail and adjacent portion of the body of the pancreas lie within this section, opposite the lower portion of the eleventh thoracic vertebra. The long axis of the spleen (56), posteriorly, coincides with the ninth rib. The upper extremity of the left kidney lies within this section at the level of the tenth thoracic disc. The section passes through a cyst lying in the upper portion of the kidney. This cyst is shown just behind the mesial portion of the spleen. The upper margin of the left suprarenal gland lies a little below the surface of the section, at the level of the upper third of the eleventh thoracic vertebra. The upper margin of the right suprarenal gland lies in this section at the level of the upper third of the eleventh thoracic vertebra.



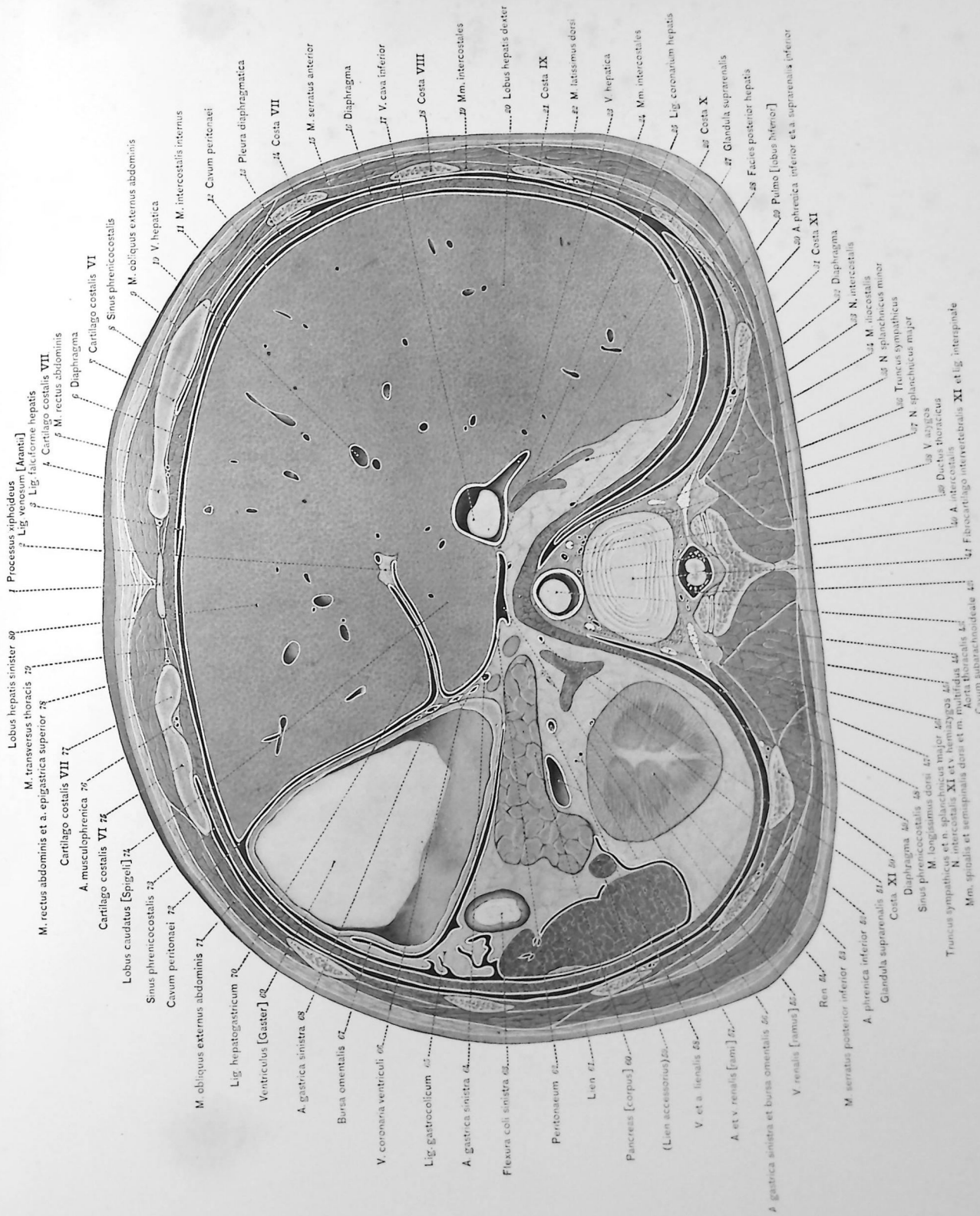
1 Lig. falciforme hepatis
 2 Cartilago costalis VII
 3 A. et v. mammaria interna
 4 M. rectus abdominis
 5 M. transversus thoracis
 6 Cartilago costalis V
 7 M. pectoralis major
 8 Panniculus adiposus
 9 V. hepatica
 10 M. intercostalis internus
 11 Cavum peritonaei
 12 Costa VI
 13 M. obliquus externus abdominis
 14 Cavum pleurae
 15 Diaphragma
 16 Costa VII
 17 Lobus hepatis dexter
 18 Pulmo [lobus inferior]
 19 V. cava inferior
 20 Costa VIII
 21 M. latissimus dorsi
 22 Lig. coronarium hepatis
 23 A. et v. phrenica inferior
 24 Lig. coronarium hepatis et costa IX
 25 M. serratus posterior inferior
 26 Pulmo [lobus inferior]
 27 Pleura pulmonalis
 28 Costa X
 29 V. et a. intercostalis
 30 N. intercostalis et m. ribcostalis dorsi
 31 N. splanchnicus minor
 32 N. splanchnicus major
 33 Truncus sympathicus
 34 V. azygos et m. longissimus dorsi
 35 Ductus thoracicus
 36 A. intercostalis
 37 Acus vertebrae thoracalis X
 38 Fibrocartilago intervertebralis X
 39 Processus spinosus [vert. thor IX]
 40 A. intercostalis
 41 Cavum articulare
 42 Aorta thoracalis
 43 Processus articularis superior [vert. thor. XI]
 44 A. intercostalis
 45 V. hemazygos
 46 N. splanchnicus minor
 47 Truncus sympathicus
 48 N. splanchnicus major
 49 Pulmo [lobus inferior]
 50 Rami suprales superiores [a. phrenica inferior]
 51 M. serratus posterior inferior
 52 Aa. et vv. gastricae breves
 53 Lig. gastrolentale
 54 A. et v. phrenica inferior
 55 Aa. et vv. gastricae breves
 56 M. serratus posterior inferior
 57 Rami suprales superiores [a. phrenica inferior]
 58 Rami oesophagi a gastricae sinistae
 59 Pulmo [lobus inferior]

78 Processus xiphoideus
 79 M. intercostalis internus
 80 Lobus caudatus [Spigelii]
 81 Cartilago costalis VI
 82 Lig. venosum [Kantii]
 83 Pericardium
 84 Sinus phrenicocostalis
 85 M. intercostalis internus
 86 M. intercostalis internus
 87 Lobus hepatis sinister
 88 A. pericardiophrenica
 89 Costa VI
 90 Diaphragma
 91 M. intercostalis internus
 92 Ventriculus [Gaster]
 93 Plexus oesophageus anterior
 94 Costa VII
 95 Lig. gastrolentale
 96 M. serratus anterior
 97 Sinus phrenicocostalis et cavum peritonaei
 98 Bursa omentalis
 99 Ventriculus [pars cardiaca]
 100 Lien

Section 29

This section is about 25 mm. below the preceding section. Its level is indicated by line 29 in Key-figures IV, V, VI, VII.

The section passes through the eleventh thoracic disc (41) and the superior articular processes of the twelfth thoracic vertebra. It cuts the sixth (7, 75) and seventh (4, 77) costal cartilages, and the following ribs: the seventh (14), eighth (18), ninth (21), tenth (26), and the eleventh (31, 50). The heads of the twelfth ribs lie within the section. Anteriorly the section passes through the middle of the xiphoid process (1). The trapezius muscle does not extend beyond this section. The inferior vena cava (17) shows one of the entering hepatic veins (23). The renal artery and vein (58) are prominent. The left branch of the portal vein arches upward in this section and enters the left lobe of the liver. The section passes through the upper third of the stomach (69), cutting the hepatogastric (70) and gastrocolic (65) ligaments. The lesser omental cavity (67) is shown behind the stomach. The upper margin of the splenic flexure (63) of the colon lies at the level of the eleventh intervertebral disc. The falciform (3) and coronary ligaments of the liver are still shown. The Spigelian lobe (*lobus caudatus*) of the liver, which was shown in the preceding section, is at this level notably wider. The tail and adjacent part of the body (60) of the pancreas appear. The spleen extends through the upper third of the section; its lower margin is opposite the upper third of the twelfth thoracic vertebra. Just internal to the spleen is a small accessory spleen (59). The upper extremity of the right kidney is in the middle of the section, and at the level of the middle of the twelfth thoracic vertebra. The right suprarenal gland is cut through its upper portion.

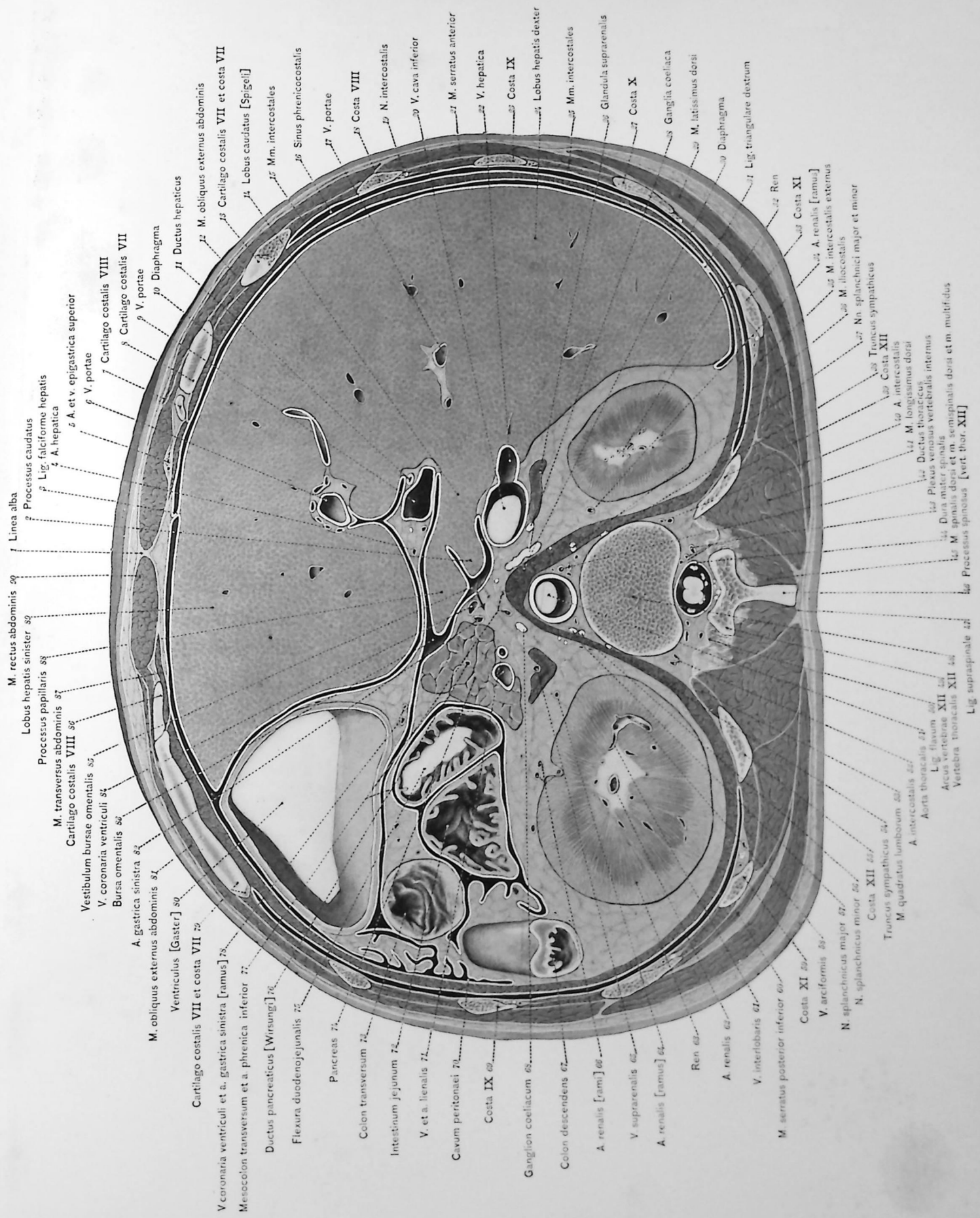


Section 30

Section 30

This section is about 26 mm. below the preceding section. Its level is indicated by line 30 in Key-figures IV, V, VI, VII.

The section passes through the twelfth thoracic vertebra (48) a little above the level of the twelfth intervertebral disc; through the arch of the twelfth thoracic vertebra (49) and the spinous process (46) of the same. The section cuts the seventh rib (13, 79), on either side, at the costochondral junction, also the united seventh and eighth costal cartilages on the left side (79, 86). The section passes through the following ribs: the eighth (18), ninth (23, 69), tenth (27), eleventh (33, 59), and twelfth (39, 55). The quadratus lumborum muscle (53) is first cut by this section. The coeliac axis arises in the middle of the section opposite the upper portion of the first lumbar vertebra. The right renal artery originates in the lower portion of this section and the upper portion of the next section. One of the hepatic veins (22) is shown as it enters the inferior vena cava (20). The section passes through the middle portion of the greater curvature of the stomach, and includes in its lower portion a part of the pyloric end of the stomach. A small part of the upper margin of the superior portion of the duodenum lies in the lower part of this section. The suspensory muscle (*m. suspensorius duodeni*), or ligament of Treitz, also lies in this section. The transverse colon (73) and the descending colon (67) are shown below the splenic flexure. It will be noted that the descending colon is retroperitoneal. The transverse mesocolon (77) is shown. The falciform ligament (3), right triangular ligament (31), and gastrohepatic omentum are all shown at this level. The papillary process (88) of the Spigelian lobe and the caudate lobe (14) are well defined. The section passes through the body of the pancreas (74), the right kidney (32), and the left kidney (63). The lower portions of both suprarenal glands lie in this section at the level of the middle third of the first lumbar vertebra.



Linea alba
 Processus caudatus
 Lig. faiciforme hepatis
 A. hepatica
 A. et v. epigastrica superior
 V. portae
 Cartilago costalis VIII
 Cartilago costalis VII
 V. portae
 Diaphragma
 Ductus hepaticus
 M. obliquus externus abdominis
 Cartilago costalis VII et costa VII
 Lobus caudatus [Spigel]
 Mm. intercostales
 Sinus phrenicocostalis
 V. portae
 Costa VIII
 N. intercostalis
 V. cava inferior
 M. serratus anterior
 V. hepatica
 Costa IX
 Lobus hepatis dexter
 Mm. intercostales
 Glandula suprarenalis
 Costa X
 Ganglia coeliaca
 M. latissimus dorsi
 Diaphragma
 Lig. triangulare dextrum
 Ren
 Costa XI
 A. renalis [ramus]
 M. intercostalis externus
 M. ilocostalis
 Nn. splanchnici major et minor
 Truncus sympathicus
 Costa XII
 A. intercostalis
 M. longissimus dorsi
 Ductus thoracicus
 Plexus venosus vertebralis internus
 Dura mater spinalis
 M. spinalis dorsi et m. semispinalis dorsi et m. multifidus
 Processus spinosus [vert. thor. XII]

M. rectus abdominis 59
 Lobus hepatis sinister 58
 Processus papillaris 58
 M. transversus abdominis 57
 Cartilago costalis VIII 56
 Vestibulum bursae omentalis 55
 V. coronaria ventriculi 54
 Bursa omentalis 53
 A. gastrica sinistra 52
 M. obliquus externus abdominis 51
 Ventriculus [Gaster] 50
 A. gastrica VII et costa VII 49
 Cartilago costalis VII et a. gastrica sinistra [ramus] 48
 Mesocolon transversum et a. phrenica inferior 47
 Ductus pancreaticus [Wirsung] 46
 Flexura duodenojejunalis 45
 Pancreas 44
 Colon transversum 43
 Intestinum jejunum 42
 V. et a. lienalis 41
 Cavum peritonei 40
 Costa IX 39
 Ganglion coeliacum 38
 Colon descendens 37
 A. renalis [ramus] 36
 V. suprarenalis 35
 A. renalis [ramus] 34
 Ren 33
 A. renalis 32
 V. interlobaris 31
 M. serratus posterior inferior 30
 Costa XI 29
 V. arciformis 28
 N. splanchnicus major 27
 N. splanchnicus minor 26
 Costa XII 25
 Truncus sympathicus 24
 M. quadratus lumborum 23
 A. intercostalis 22
 Aorta thoracalis 21
 Lig. flavum 20
 Arcus vertebrae XII XII 19
 Vertebra thoracalis XII XII 18
 Lig. supraspinale 17

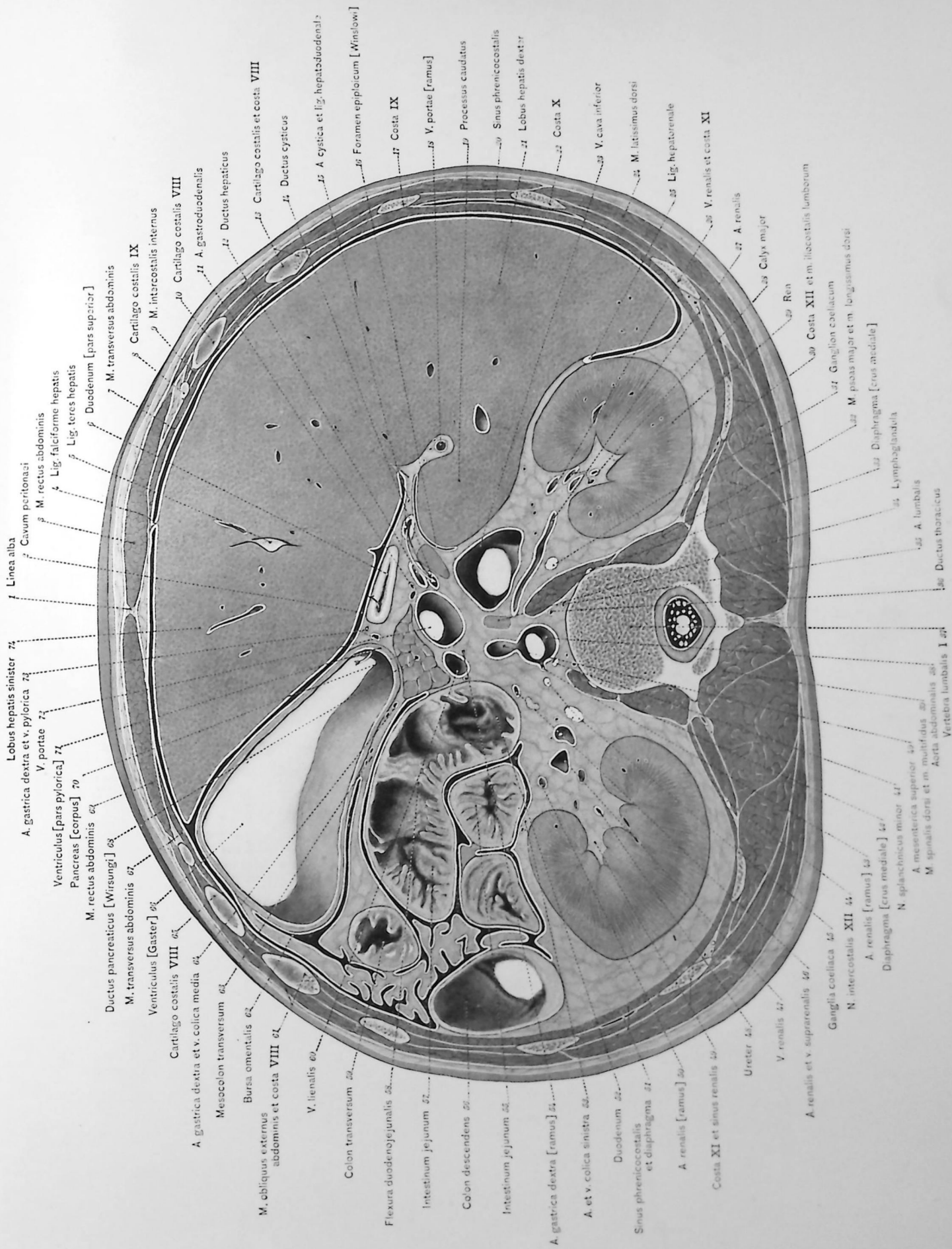
Section 31

Section 31

This section is about 26 mm. below the preceding section. Its level is indicated by line 31 in Key-figures IV, V, VI, VII.

The section passes through the lower third of the first lumbar vertebra (37) and the lower margin of its right transverse process. The left transverse process lies in the preceding section. The section cuts the eighth (10, 65) and ninth (8) costal cartilages, and the costochondral junction of the eighth rib (13, 61). It also cuts the following ribs: the ninth (17), the tenth (22), the eleventh (26, 49), and the twelfth (30). The psoas major muscle (32) is cut for the first time. The psoas minor muscle is not present in this subject. The mesial crura of the diaphragm (33, 42) are shown on either side. The right renal artery (27), which arises from the aorta in the preceding section, is here cut lengthwise. The left renal artery arises from the aorta in the body of this section. Both renal veins enter the inferior vena cava within this section. The portal vein (72) is formed in the upper portion of this section by the union of the splenic and superior mesenteric veins. The section passes through the lower portion of the stomach (66) on the left, and through the pyloric portion (71) near the median plane. The pyloric orifice lies in the body of this section, slightly to the left of the median plane and at the level of the first lumbar disc. The superior portion of the duodenum (6) is cut through its upper margin (an arrow passes through the pyloric orifice of the stomach into the duodenum). The duodenojejunal flexure (58) is cut through its lower portion. The descending (56) and transverse (59) portions of the colon are shown. The greater omentum is prominent. A small part of the nonperitoneal area of the liver is shown in front of the right kidney. The round ligament of the liver (5) is cut obliquely. The umbilical fissure which separates the right and left lobes of the liver first appears in the lower portion of this section. The neck of the gall-bladder lies about 5 mm. below the surface of this section, and between the quadrate and caudate lobes of the liver. The cystic duct (14) is cut in two places, which are connected by an arrow. The hepatic duct (12) lies just anterior to the cystic duct. The cystic and hepatic ducts unite in the lower third of this section to form the common bile duct. The pancreatic duct (68) is shown within the pancreas (70). The right kidney is cut about 1 cm. above its middle portion and the left kidney below its middle portion. The ureter (48) is shown on the left side, and one of the major calices (28) of the kidney on the right side.

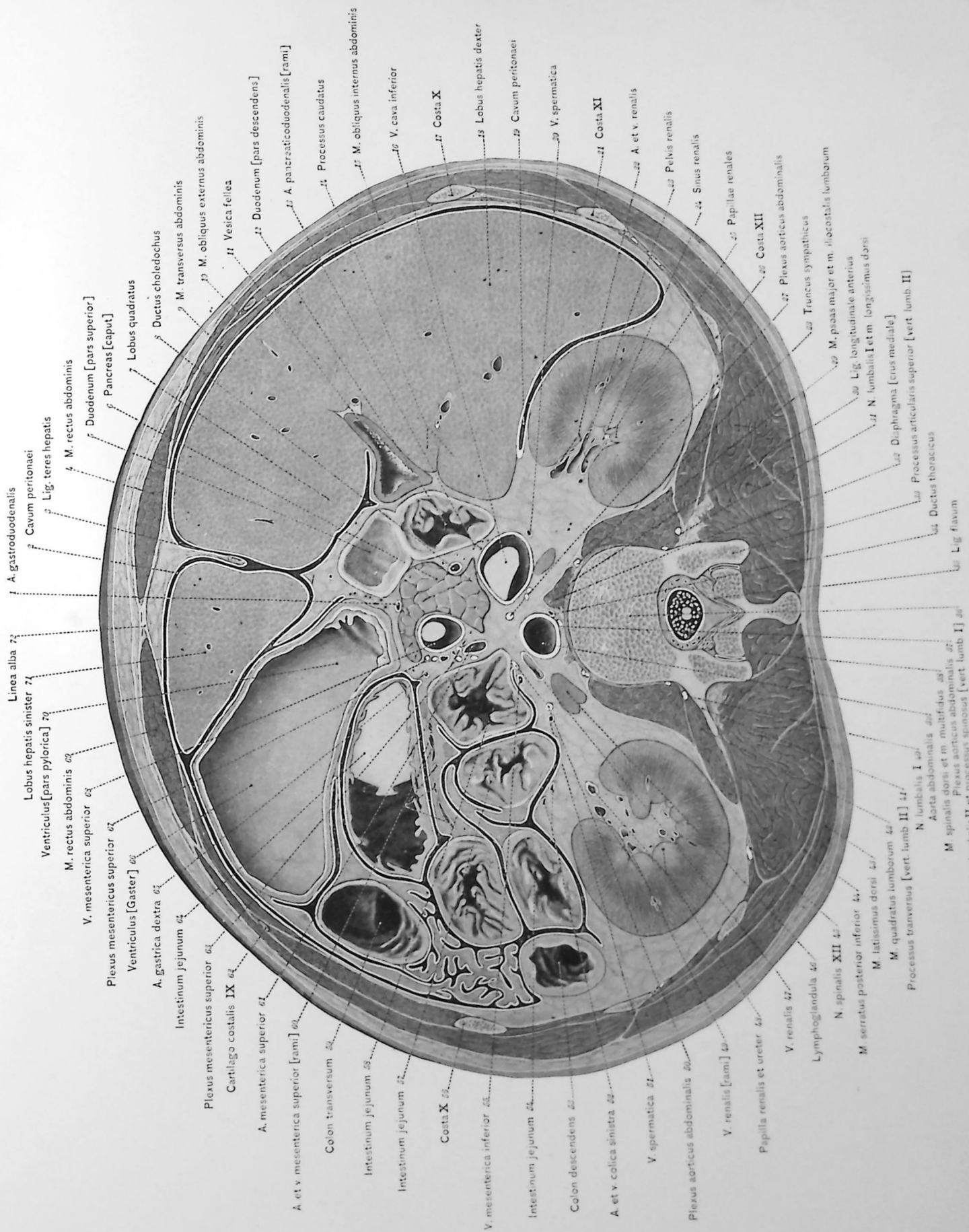
Note.—We have labeled the v. pylorica (73) following Spalteholz, although it is not given in the BNA. The sympathetic trunk on the right side is not labeled, but is crossed by leader 33.



Section 32

This section is about 25 mm. below the preceding section. Its level is indicated by line 32 in Key-figures IV, V, VI, VII.

The section passes through the middle of the second lumbar vertebra (36); through the left transverse process (41) and the superior articular processes (33) of the same; and through the spinous process of the first lumbar vertebra. It cuts the ninth costal cartilage (62), and the following ribs: the tenth (17, 56), the eleventh (21), and twelfth (26). The obliquus internus abdominis muscle (15) first appears. The serratus posterior inferior muscle (44) extends but a short distance within the section. The superior pancreatico-duodenal artery takes origin in the preceding section, and shows some of its branches at 13. The lower portion of the stomach (66, 70) lies entirely within this section; its lowest portion lies at the level of the second lumbar disc. The hepatic flexure of the colon lies in the lower portion of the section opposite the second lumbar disc. The lobes of the liver are here separated by the round ligament (3). The left lobe of the liver (71) does not extend below this section. The anterior margin of the liver, in the median line, lies opposite the second lumbar disc. The lowest point of the liver in the mid-line lies the width of one vertebra lower than the average. The lower margin of the pancreas (6) lies in this section, opposite the second lumbar disc. The filum terminale from this section downward to its termination has not been labeled.



A. gastroduodenalis

Linea alba 72

Lobus hepatis sinister 71

Ventriculus [pars pylorica] 70

M. rectus abdominis 68

V. mesenterica superior 63

Plexus mesentericus superior 62

Ventriculus [Gaster] 60

A. gastrica dextra 67

Intestinum jejunum 64

Plexus mesentericus superior 63

Cartilago costalis IX 62

Cavum peritoneae

Lig. teres hepatis

M. rectus abdominis

Duodenum [pars superior]

Pancreas [caput]

Lobus quadratus

Ductus choledochus

M. transversus abdominis

M. obliquus externus abdominis

Vesica fellea

Duodenum [pars descendens]

A. pancreaticoduodenalis [rami]

Processus caudatus

M. obliquus internus abdominis

V. cava inferior

Costa X

Lobus hepatis dexter

Cavum peritoneae

V. spermatica

Costa XI

A. et v. renalis

Pelvis renalis

Sinus renalis

Papillae renales

Costa XII

Plexus aorticus abdominalis

Truncus sympathicus

M. psoas major et m. iliocostalis lumborum

Lig. longitudinale arterius

N. lumbalis I et m. longissimus dorsi

Diaphragma [crus mediale]

Processus articularis superior [vert. lumb. II]

Ductus thoracicus

Lig. flaxum

M. latissimus dorsi 44

M. quadratus lumborum 44

N. spinalis XII 42

M. serratus posterior inferior 44

N. lumbalis I 40

Aorta abdominalis 40

M. spinalis dorsi et m. multifidus 40

Plexus aorticus abdominalis 47

Vertebra lumbalis II et processus spinosus [vert. lumb. I] 40

V. renalis 42

Lymphoglandula 40

V. renalis [ram] 40

Papilla renalis et ureter 43

M. quadratus lumborum 44

M. latissimus dorsi 44

M. serratus posterior inferior 44

N. lumbalis I 40

Aorta abdominalis 40

M. spinalis dorsi et m. multifidus 40

Plexus aorticus abdominalis 47

Vertebra lumbalis II et processus spinosus [vert. lumb. I] 40

V. renalis 42

Lymphoglandula 40

V. renalis [ram] 40

Papilla renalis et ureter 43

M. quadratus lumborum 44

M. latissimus dorsi 44

M. serratus posterior inferior 44

N. lumbalis I 40

Aorta abdominalis 40

M. spinalis dorsi et m. multifidus 40

Plexus aorticus abdominalis 47

Vertebra lumbalis II et processus spinosus [vert. lumb. I] 40

V. renalis 42

Lymphoglandula 40

V. renalis [ram] 40

Papilla renalis et ureter 43

M. quadratus lumborum 44

M. latissimus dorsi 44

M. serratus posterior inferior 44

N. lumbalis I 40

Aorta abdominalis 40

M. spinalis dorsi et m. multifidus 40

Plexus aorticus abdominalis 47

Vertebra lumbalis II et processus spinosus [vert. lumb. I] 40

V. renalis 42

Lymphoglandula 40

V. renalis [ram] 40

Papilla renalis et ureter 43

M. quadratus lumborum 44

M. latissimus dorsi 44

M. serratus posterior inferior 44

N. lumbalis I 40

Aorta abdominalis 40

M. spinalis dorsi et m. multifidus 40

Plexus aorticus abdominalis 47

Vertebra lumbalis II et processus spinosus [vert. lumb. I] 40

V. renalis 42

Lymphoglandula 40

V. renalis [ram] 40

Papilla renalis et ureter 43

M. quadratus lumborum 44

M. latissimus dorsi 44

M. serratus posterior inferior 44

N. lumbalis I 40

Aorta abdominalis 40

M. spinalis dorsi et m. multifidus 40

Plexus aorticus abdominalis 47

Vertebra lumbalis II et processus spinosus [vert. lumb. I] 40

V. renalis 42

Lymphoglandula 40

V. renalis [ram] 40

Papilla renalis et ureter 43

M. quadratus lumborum 44

M. latissimus dorsi 44

M. serratus posterior inferior 44

N. lumbalis I 40

Aorta abdominalis 40

M. spinalis dorsi et m. multifidus 40

Plexus aorticus abdominalis 47

Vertebra lumbalis II et processus spinosus [vert. lumb. I] 40

V. renalis 42

Lymphoglandula 40

V. renalis [ram] 40

Papilla renalis et ureter 43

M. quadratus lumborum 44

M. latissimus dorsi 44

M. serratus posterior inferior 44

N. lumbalis I 40

Aorta abdominalis 40

M. spinalis dorsi et m. multifidus 40

Plexus aorticus abdominalis 47

Vertebra lumbalis II et processus spinosus [vert. lumb. I] 40

V. renalis 42

Lymphoglandula 40

V. renalis [ram] 40

Papilla renalis et ureter 43

M. quadratus lumborum 44

M. latissimus dorsi 44

M. serratus posterior inferior 44

N. lumbalis I 40

Aorta abdominalis 40

M. spinalis dorsi et m. multifidus 40

Plexus aorticus abdominalis 47

Vertebra lumbalis II et processus spinosus [vert. lumb. I] 40

V. renalis 42

Lymphoglandula 40

V. renalis [ram] 40

Papilla renalis et ureter 43

M. quadratus lumborum 44

M. latissimus dorsi 44

M. serratus posterior inferior 44

N. lumbalis I 40

Aorta abdominalis 40

M. spinalis dorsi et m. multifidus 40

Plexus aorticus abdominalis 47

Vertebra lumbalis II et processus spinosus [vert. lumb. I] 40

V. renalis 42

Lymphoglandula 40

V. renalis [ram] 40

Papilla renalis et ureter 43

M. quadratus lumborum 44

M. latissimus dorsi 44

M. serratus posterior inferior 44

N. lumbalis I 40

Aorta abdominalis 40

M. spinalis dorsi et m. multifidus 40

Plexus aorticus abdominalis 47

Vertebra lumbalis II et processus spinosus [vert. lumb. I] 40

V. renalis 42

Lymphoglandula 40

V. renalis [ram] 40

Papilla renalis et ureter 43

M. quadratus lumborum 44

M. latissimus dorsi 44

M. serratus posterior inferior 44

N. lumbalis I 40

Aorta abdominalis 40

M. spinalis dorsi et m. multifidus 40

Plexus aorticus abdominalis 47

Vertebra lumbalis II et processus spinosus [vert. lumb. I] 40

V. renalis 42

Lymphoglandula 40

V. renalis [ram] 40

Papilla renalis et ureter 43

M. quadratus lumborum 44

M. latissimus dorsi 44

M. serratus posterior inferior 44

N. lumbalis I 40

Aorta abdominalis 40

M. spinalis dorsi et m. multifidus 40

Plexus aorticus abdominalis 47

Vertebra lumbalis II et processus spinosus [vert. lumb. I] 40

V. renalis 42

Lymphoglandula 40

V. renalis [ram] 40

Papilla renalis et ureter 43

M. quadratus lumborum 44

M. latissimus dorsi 44

M. serratus posterior inferior 44

N. lumbalis I 40

Aorta abdominalis 40

M. spinalis dorsi et m. multifidus 40

Plexus aorticus abdominalis 47

Vertebra lumbalis II et processus spinosus [vert. lumb. I] 40

V. renalis 42

Lymphoglandula 40

V. renalis [ram] 40

Papilla renalis et ureter 43

M. quadratus lumborum 44

M. latissimus dorsi 44

M. serratus posterior inferior 44

N. lumbalis I 40

Aorta abdominalis 40

M. spinalis dorsi et m. multifidus 40

Plexus aorticus abdominalis 47

Vertebra lumbalis II et processus spinosus [vert. lumb. I] 40

V. renalis 42

Lymphoglandula 40

V. renalis [ram] 40

Papilla renalis et ureter 43

M. quadratus lumborum 44

M. latissimus dorsi 44

M. serratus posterior inferior 44

N. lumbalis I 40

Aorta abdominalis 40

M. spinalis dorsi et m. multifidus 40

Plexus aorticus abdominalis 47

Vertebra lumbalis II et processus spinosus [vert. lumb. I] 40

V. renalis 42

Lymphoglandula 40

V. renalis [ram] 40

Papilla renalis et ureter 43

M. quadratus lumborum 44

M. latissimus dorsi 44

M. serratus posterior inferior 44

N. lumbalis I 40

Aorta abdominalis 40

M. spinalis dorsi et m. multifidus 40

Plexus aorticus abdominalis 47

Vertebra lumbalis II et processus spinosus [vert. lumb. I] 40

V. renalis 42

Lymphoglandula 40

V. renalis [ram] 40

Papilla renalis et ureter 43

M. quadratus lumborum 44

M. latissimus dorsi 44

M. serratus posterior inferior 44

N. lumbalis I 40

Aorta abdominalis 40

M. spinalis dorsi et m. multifidus 40

Plexus aorticus abdominalis 47

Vertebra lumbalis II et processus spinosus [vert. lumb. I] 40

V. renalis 42

Lymphoglandula 40

V. renalis [ram] 40

Papilla renalis et ureter 43

M. quadratus lumborum 44

M. latissimus dorsi 44

Section 33

Section 33

This section is about 24 mm. below the preceding section. Its level is indicated by line 33 in Key-figures IV, V, VI, VII.

The section passes through the third lumbar vertebra (36), just below the level of the second lumbar disc. It passes through the spinous process (36) of the second lumbar vertebra and the superior articular processes (39) of the third lumbar vertebra; through the tips of the eleventh (18) and twelfth (23) ribs on the right side, and the tip of the eleventh (54) on the left. The inferior mesenteric artery (38) is shown at the point where it originates from the abdominal aorta (33). In the median line a large intestinal vein is shown as it enters the left side of the superior mesenteric vein (70). The right colic vein joins the superior mesenteric vein in the body of the section. The greater omentum (57) lies largely on the left side. The descending portion of the duodenum (13) shows the bile papilla (11). The ascending part of the inferior portion of the duodenum (4) lies between the aorta (33) and the superior mesenteric artery and vein (63, 70). The fundus of the gall-bladder lies in the lower portion of this section, opposite the third lumbar disc. Both kidneys extend into this section.

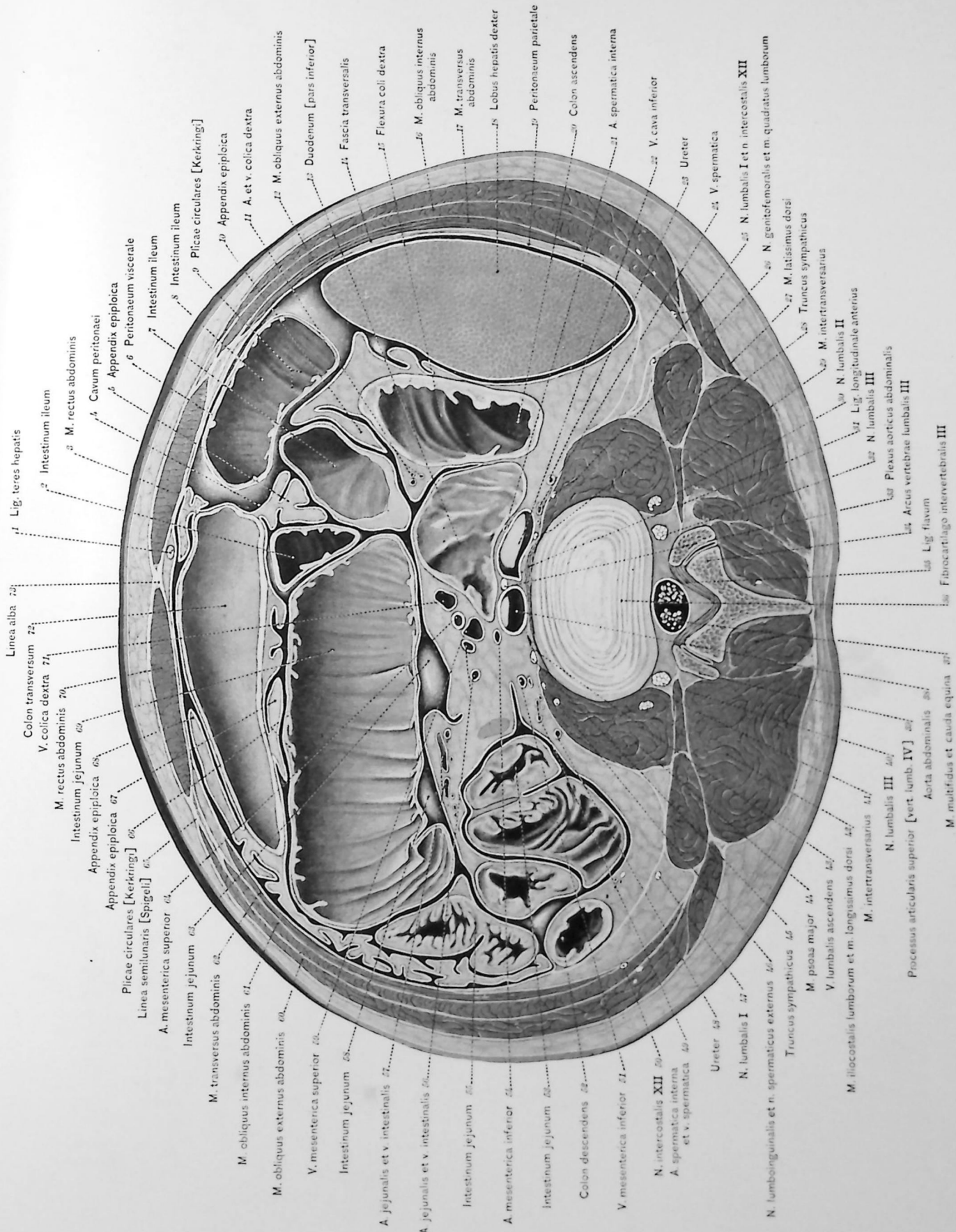
Section 34

Section 34

This section is about 27 mm. below the preceding section. Its level is indicated by line 34 in Key-figures IV, V, VI, VII.

The section passes through the third lumbar disc (36); through the arches and spinous process of the third lumbar vertebra, and the superior articular processes (39) of the fourth lumbar vertebra. The transverse processes of the fourth lumbar vertebra lie largely within the section, only their lower margins being cut by the next section. The intertransversarius muscles (29, 41) are well defined. A part of the origin of the latissimus dorsi muscle is in the body of this section. The lowest portion of the duodenum (13) is shown; it lies opposite the upper portion of the fourth lumbar vertebra. The section passes through several loops of the jejunum (53, 55, 58, 63, 69) on the left side and through three loops of the ileum (2, 7, 8) on the right side. It should be recalled that a sharp line of demarcation is not present between the jejunum and ileum. The hepatic flexure (15) of the colon lies opposite the second lumbar disc, and is considerably lower than the average. The lower portion of the transverse colon (72) is shown in this section. It lies about 25 mm. above the umbilicus, being possibly a little higher than the average. The lowest point of the liver, in this section, is at the level of the upper third of the fourth lumbar vertebra, being about one vertebra lower than the average.

Note.—The transverse portion of the duodenum (13) is given in the BNA, as the horizontal part of the inferior portion.



1 Lig. teres hepatis

2 Intestinum ileum

3 M. rectus abdominis

4 Cavum peritoneae

5 Appendix epiploica

6 Peritonaeum viscerale

7 Intestinum ileum

8 Intestinum ileum

9 Plicae circulares [Kerkringi]

10 Appendix epiploica

11 A. et v. colica dextra

12 M. obliquus externus abdominis

13 Duodenum [pars inferior]

14 Fascia transversalis

15 Flexura coli dextra

16 M. obliquus internus abdominis

17 M. transversus abdominis

18 Lobus hepatis dexter

19 Peritonaeum parietale

20 Colon ascendens

21 A. spermatica interna

22 V. cava inferior

23 Ureter

24 V. spermatica

25 N. lumbalis I et n. intercostalis XII

26 N. genitofemoralis et m. quadratus lumborum

27 M. latissimus dorsi

28 Truncus sympathicus

29 M. intertransversarius

30 N. lumbalis II

31 Lig. longitudinale anterius

32 N. lumbalis III

33 Flexus aorticus abdominalis

34 Arcus vertebrae lumbalis III

35 Lig. flavum

36 Fibrocartilago intervertebralis III

37 M. multifidus et cauda equina

38

39

40

41 Linea alba

42 Linea transversum

43 V. colica dextra

44 M. rectus abdominis

45 Intestinum jejunum

46 Appendix epiploica

47 Appendix epiploica

48 Plicae circulares [Kerkringi]

49 Linea semilunaris [Spigeli]

50 A. mesenterica superior

51 Intestinum jejunum

52 M. transversus abdominis

53 M. obliquus internus abdominis

54 M. obliquus externus abdominis

55 V. mesenterica superior

56 Intestinum jejunum

57 A. jejunalis et v. intestinalis

58 A. jejunalis et v. intestinalis

59 Intestinum jejunum

60 A. mesenterica inferior

61 Intestinum jejunum

62 Colon descendens

63 V. mesenterica inferior

64 N. intercostalis XII

65 A. spermatica interna et v. spermatica

66 Ureter

67 N. lumbalis I

68 Truncus sympathicus

69 M. psoas major

70 V. lumbalis ascendens

71 V. lumbalis lumborum et m. longissimus dorsi

72 M. intertransversarius

73 N. lumbalis III

74 Processus articularis superior [vert. lumb. IV]

75 Aorta abdominalis

76 M. multifidus et cauda equina

77

78

79

80

Section 35

Section 35

This section is about 25 mm. below the preceding section. Its level is indicated by line 35 in Key-figures IV, V, VI, VII.

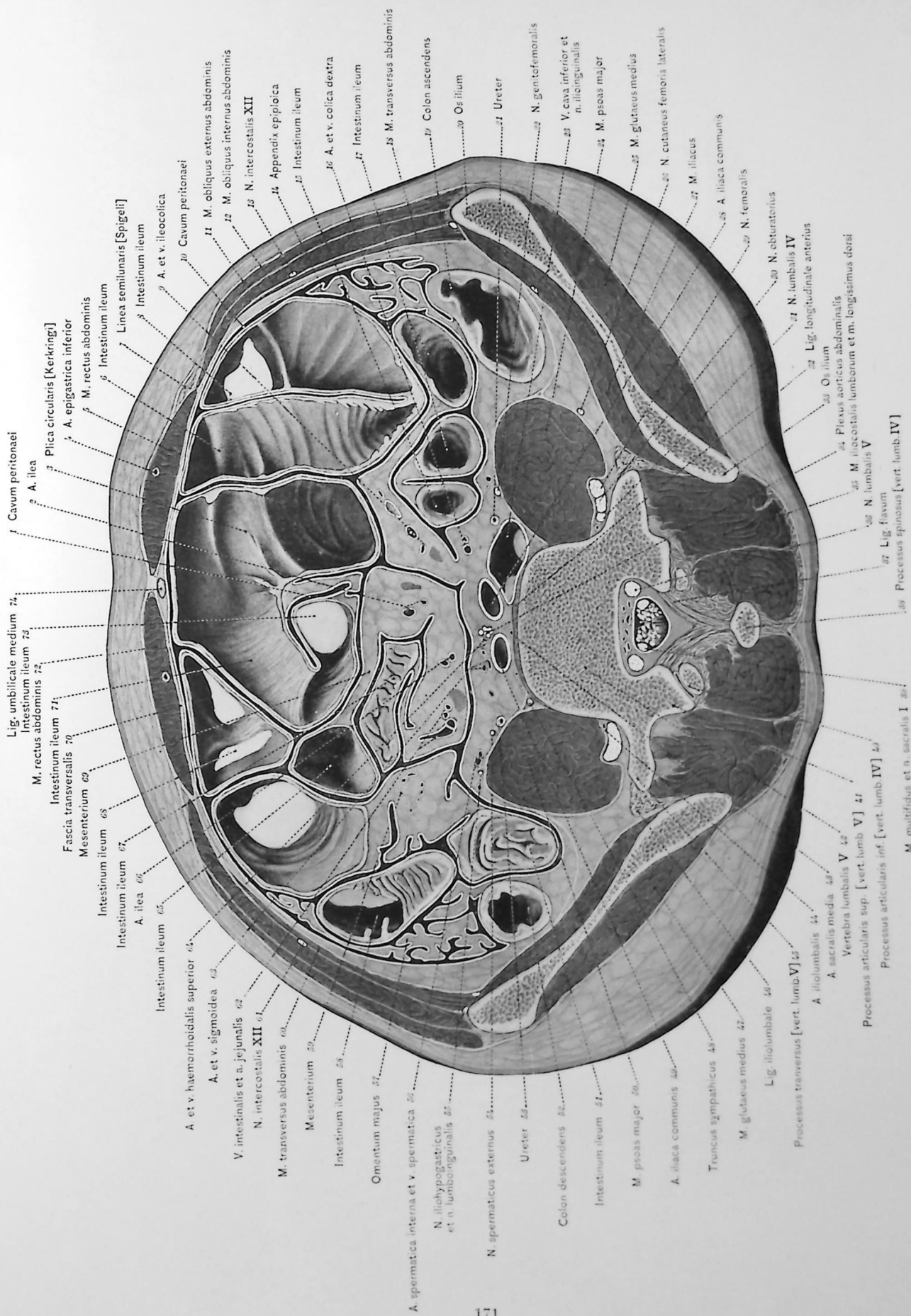
The section passes through the lower portion of the fourth lumbar vertebra (36); through the arch, the inferior margins of the transverse processes, and the upper portion of the spinous process of the same. The quadratus lumborum muscle (26) does not extend beyond this section. The aorta bifurcates in the lower third of the section, giving rise to the common iliaes (38). The coils of the small intestine are cut several times. Those cut on the left side are through the jejunal portion, while those on the right are through the ileal portion. The ascending colon (20) is shown. The descending colon (51) reaches the crest of the ilium just below the surface of the section. Below this level, authors are somewhat at variance in the application of terms. Some consider this level the beginning of the sigmoid colon. According to Porier and Charpy, Spalteholtz and others, only that portion of the colon below the place where it is in front of the iliac vessels and the left vas deferens should be called the sigmoid colon. This latter view has been adopted, and we label the colon above the point where it lies in front of the iliac vessels and left vas deferens "colon descendens." It should be noted that the greater omentum (55) is prominent on the left side in this and the preceding sections.

Section 36

Section 36

This section is about 25 mm. below the preceding section. Its level is indicated by line 36 in Key-figures IV, V, VI, VII.

The section passes through the upper third of the fifth lumbar vertebra (42), through the transverse processes (45) and superior articular processes (41) of the same; through the lower portion of the spinous process (38) of the fourth lumbar vertebra and the inferior articular processes of the same (40). It cuts the ilium through the upper portion of the iliac fossa, and passes just above the wings of the sacrum. The glutæus medius (25, 47) and iliacus (27) muscles are first cut by this section. The right common iliac (28) bifurcates in the lower portion of the section into the external iliac and internal iliac (hypogastrica) arteries. The common iliac veins are shown as they unite in the lower portion of the section, to form the inferior vena cava (23). Their junction is opposite the lower portion of the fifth lumbar vertebra. A small portion of the greater omentum (57) is shown in this section, but does not extend into the next section.



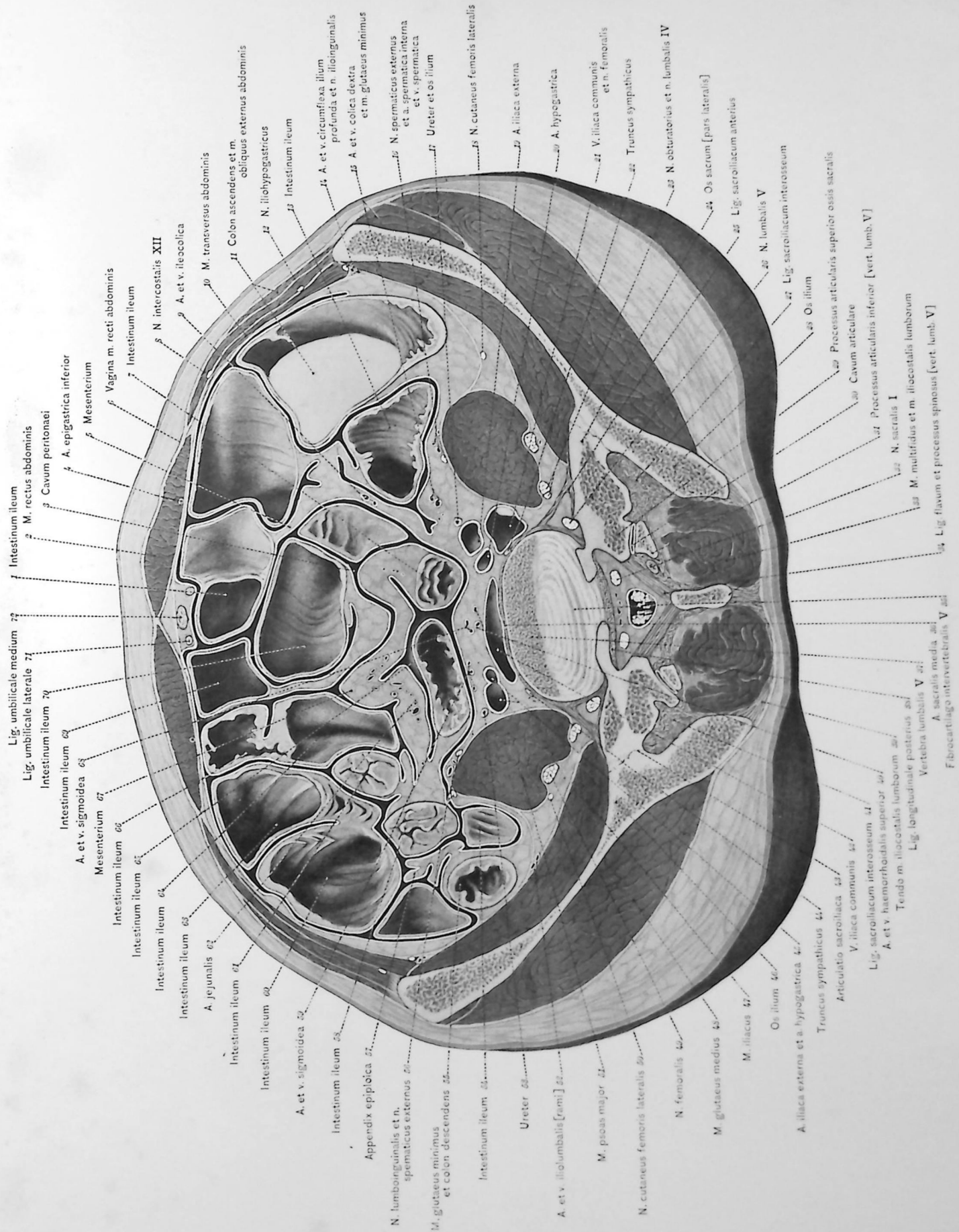
SECTION 36

Section 37

Section 37

This section is about 24 mm. below the preceding section. Its level is indicated by line 37 in Key-figures IV, V, VI, VII.

The section passes through both the lower margin of the fifth lumbar vertebra (37) and the fifth lumbar disc (35); through the inferior articular processes (31), and the spinous process (34) of the same; through the superior articular processes of the sacrum (29), and through the iliac bones (17, 28, 46) about 5 cm. below their superior margins. The glutæus minimus muscle (15) is first cut by this section. The right common iliac artery bifurcated in the section above, giving rise to the external iliac (19) and the internal iliac (20). The left common iliac artery branches just at the level of the upper surface of the section into the external iliac (45) and internal iliac (45). The common iliac veins (21, 42) are at this level close together, and unite in the section above. The jejunum is not cut at this level, but the ileum is cut in many places. The ascending colon (11) is greatly dilated. The mesentery does not extend beyond the upper portion of this section.

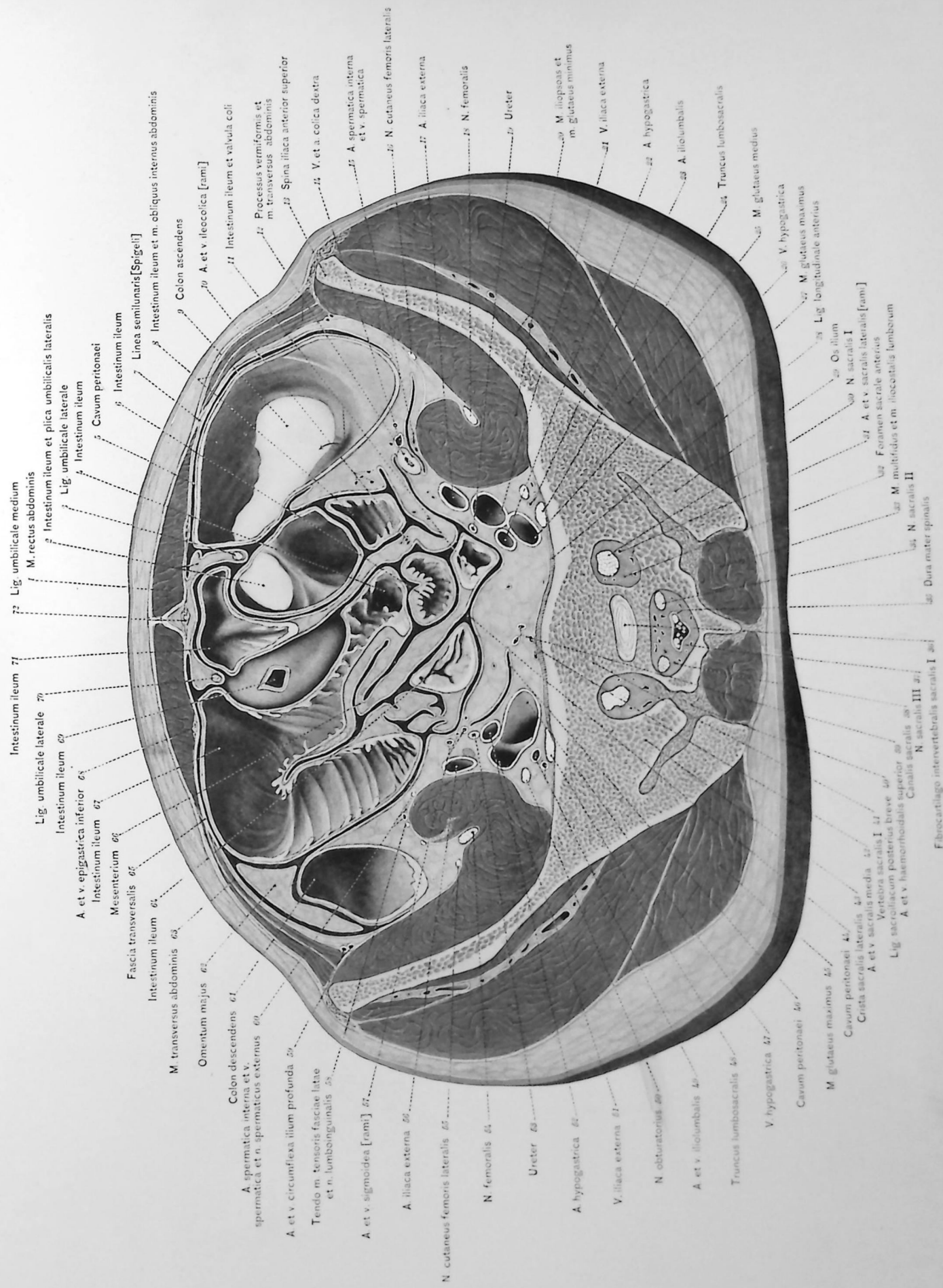


Section 38

Section 38

This section is about 23 mm. below the preceding section. Its level is indicated by line 38 in Key-figures IV, V, VI, VII.

The section passes through the sacrum just above the upper margin of the first pair of anterior sacral foramina (32); through the anterior superior spine of the ilium (13) on the right side. On the left side the lower margin of the spine lies in the middle of the section. The glutæus maximus muscle (27, 45) appears on either side. The aponeurosis of the external oblique muscle shows in this section and in Sections 39 and 40. The internal iliac veins (26, 47) have united with the external iliac veins (21, 51), on either side in the lower portion of the section above, to form the common iliac veins. The appendix (12) extends upward, then downward and inward. The section passes through its highest point. The body of the appendix lies in this section, but its union with the cæcum lies partly in the lower margin of this section and partly in the upper margin of the next section. The ileocæcal valve (11) is indicated by an arrow. It is somewhat lower in this subject than the average, although its position is exceedingly variable.



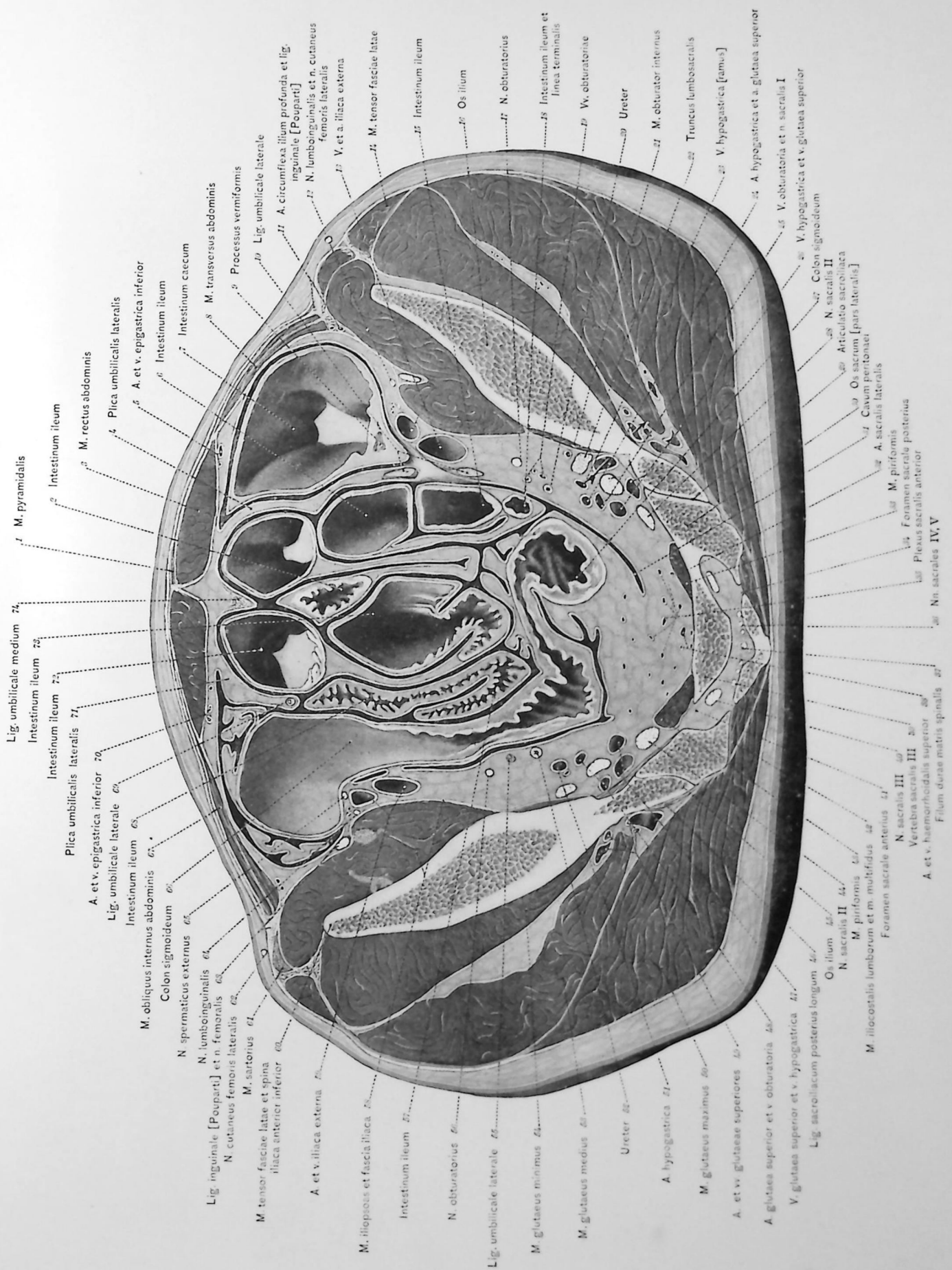
- 1 Lig. umbilicale medium
 2 M. rectus abdominis
 3 Intestinum ileum et plica umbilicalis lateralis
 4 Lig. umbilicale laterale
 5 Intestinum ileum
 6 Cavum peritoneaei
 7 Intestinum ileum
 8 Linea semilunaris [Spigelii]
 9 Intestinum ileum et m. obliquus internus abdominis
 10 Colon ascendens
 11 A. et v. ileocolica [rami]
 12 Intestinum ileum et valvula coli
 13 Processus vermiformis et m. transversus abdominis
 14 Spina iliaca anterior superior
 15 V. et a. colica dextra
 16 A. spermatica interna et v. spermatica
 17 N. cutaneus femoris lateralis
 18 A. iliaca externa
 19 N. femoralis
 20 Ureter
 21 M. iliopsoas et m. glutaeus minimus
 22 V. iliaca externa
 23 A. hypogastrica
 24 A. iliolumbalis
 25 Truncus lumbosacralis
 26 M. glutaeus medius
 27 V. hypogastrica
 28 M. glutaeus maximus
 29 Lig. longitudinale anterius
 30 Os ilium
 31 N. sacralis I
 32 A. et v. sacralis lateralis [rami]
 33 Foramen sacrale anterius
 34 M. multifidus et m. iliocostalis lumborum
 35 N. sacralis II
 36 Dura mater spinalis
 37 Fibrocartilago intervertebralis sacralis I
 38 N. sacralis III
 39 Canalis sacralis
 40 A. et v. haemorrhoidalis superior
 41 Vertebra sacralis I
 42 Crista sacralis lateralis
 43 Cavum peritoneaei
 44 M. glutaeus maximus
 45 M. glutaeus medius
 46 Cavum peritoneaei
 47 V. hypogastrica
 48 Truncus lumbosacralis
 49 A. et v. iliolumbalis
 50 N. obturatorius
 51 V. iliaca externa
 52 A. hypogastrica
 53 Ureter
 54 N. femoralis
 55 N. cutaneus femoris lateralis
 56 A. iliaca externa
 57 A. et v. sigmoidica [rami]
 58 Tendo m. tensoris fasciae latae et n. lumbosacralis
 59 A. et v. circumflexa ilium profunda
 60 M. transversus abdominis
 61 Omentum majus
 62 Fascia transversalis
 63 Mesenterium
 64 Intestinum ileum
 65 A. et v. epigastrica inferior
 66 Intestinum ileum
 67 Lig. umbilicale laterale
 68 Intestinum ileum
 69 M. rectus abdominis
 70 Lig. umbilicale medium
 71 Intestinum ileum
 72 Intestinum ileum et m. obliquus internus abdominis

Section 39

Section 39

This section is about 24 mm. below the preceding section. Its level is indicated by line 39 in Key-figures IV, V, VI, VII.

The section passes through the third sacral vertebra near the upper margins of the third anterior sacral foramina (41); through the lower margins of the third posterior sacral foramina (34). It also passes through the upper margins of the anterior inferior iliac spines (60). The fourth pair of sacral foramina lie within the section. The following muscles are first cut: the pyramidalis (1), the tensor vagina femoris (14, 60), obturator internus (21), piriformis (33, 43), and the sartorius (61). The external oblique is continued as an aponeurosis only. Poupart's ligaments (11, 63) begin in the section above. The deep epigastric artery (5, 70) takes origin in this section, passes downward, and at the upper surface of the next section gives rise to the obturator artery. The arrow on line 24 indicates the gluteal artery as it passes through the sciatic notch. The cæcum (7) is shown in this section. The point at which the appendix (9) joins the cæcum is well shown. This point is at the level of the third sacral vertebra, and in a horizontal plane, passing through the anterior inferior iliac spines. It is here somewhat lower than the average. The lowest portion of the descending colon passes over into the sigmoid colon (66), the line of demarcation being as stated under Section 35. The sigmoid colon (27) passes over into the rectum within the section.



- 1 M. pyramidalis
 2 Intestinum ileum
 3 M. rectus abdominis
 4 Plica umbilicalis lateralis
 5 A. et v. epigastrica inferior
 6 Intestinum ileum
 7 Intestinum caecum
 8 M. transversus abdominis
 9 Processus vermiformis
 10 Lig. umbilicale laterale
 11 A. circumflexa, ilium profunda et lig. inguinale [Poupart]
 12 N. lumbinguinalis et n. cutaneus femoris lateralis
 13 V. et a. iliaca externa
 14 M. tensor fasciae latae
 15 Intestinum ileum
 16 Os ilium
 17 N. obturatorius
 18 Intestinum ileum et linea terminalis
 19 Vv. obtratoriae
 20 Ureter
 21 M. obturator internus
 22 Truncus lumbosacralis
 23 V. hypogastrica [ramus]
 24 A. hypogastrica et a. glutea superior
 25 V. obturatoria et n. sacralis I
 26 V. hypogastrica et v. glutea superior
 27 Colon sigmoideum
 28 N. sacralis II
 29 Articulatio sacroiliaca
 30 Os sacrum [pars lateralis]
 31 Cavum peritoneae
 32 A. sacralis lateralis
 33 M. piriformis
 34 Foramen sacrale posterius
 35 Plexus sacralis anterior
 36 Nn. sacrales IV, V
 37 N. sacralis I
 38 N. sacralis II
 39 M. piriformis
 40 Foramen sacrale posterius
 41 Plexus sacralis anterior
 42 Nn. sacrales IV, V
 43 N. sacralis III
 44 Vertebra sacralis superior
 45 A. et v. haemorroidalis superior
 46 Filum derae matris spinalis
 47 Nn. sacrales IV, V
 48 N. sacralis III
 49 Vertebra sacralis superior
 50 A. et v. haemorroidalis superior
 51 Filum derae matris spinalis
 52 N. sacralis II
 53 M. piriformis
 54 Foramen sacrale posterius
 55 Plexus sacralis anterior
 56 N. sacralis I
 57 V. hypogastrica et v. glutea superior
 58 V. obturatoria et n. sacralis I
 59 A. hypogastrica et a. glutea superior
 60 Truncus lumbosacralis
 61 M. obturator internus
 62 Ureter
 63 M. gluteus medius
 64 M. gluteus minimus
 65 Lig. umbilicale laterale
 66 N. obturatorius
 67 Intestinum ileum
 68 M. iliopsoas et fascia iliaca
 69 A. et v. iliaca externa
 70 M. tensor fasciae latae et spina iliaca anterior inferior
 71 M. sartorius
 72 N. cutaneus femoris lateralis
 73 N. lumbinguinalis
 74 N. spermaticus externus
 75 Colon sigmoideum
 76 M. obliquus internus abdominis
 77 Intestinum ileum
 78 Lig. umbilicale laterale
 79 Plica umbilicalis inferior
 80 Intestinum ileum lateralis
 81 Intestinum ileum
 82 Lig. umbilicale medium
 83 Intestinum ileum
 84 M. pyramidalis

Section 40

Section 40

This section is about 23 mm. below the preceding section. Its level is indicated by line 40 in Key-figures IV, V, VI, VII.

The section passes through the sacrum slightly above the margins of the fifth anterior pair of sacral foramina; through the upper portion of the acetabulum (55) and the upper portion of the head of the femur (56). The following muscles are cut for the first time: the pectineus (63) and the interfoveolaris (67). The external iliac arteries (11, 63) pass beneath Poupart's ligament in this section, and become the femoral arteries. Likewise the femoral veins, as they pass Poupart's ligament, become the external iliac veins (11, 63). The profunda artery on the left side comes off from the femoral artery within the section. The deep epigastric artery (9, 64) on either side comes off from the external iliac (11, 63) in the lower portion of the preceding section. The variable obturators (9, 64) arise from the deep epigastrics in the lower portion of the preceding section. The fundus of the caecum (6) lies in this section. The rectum at this level lies about 1 cm. to the left of the median line. The lowest portion of the peritoneum is in this section. The urachus (72) is cut. The upper surface of the bladder (2) lies just below the surface of the section, and about 1.5 cm. above the upper margin of the pubic symphysis. The ureters enter the bladder within the section. The upper margins of the seminal vesicles lie in the middle of the section. The spermatic cord (8) is well defined.

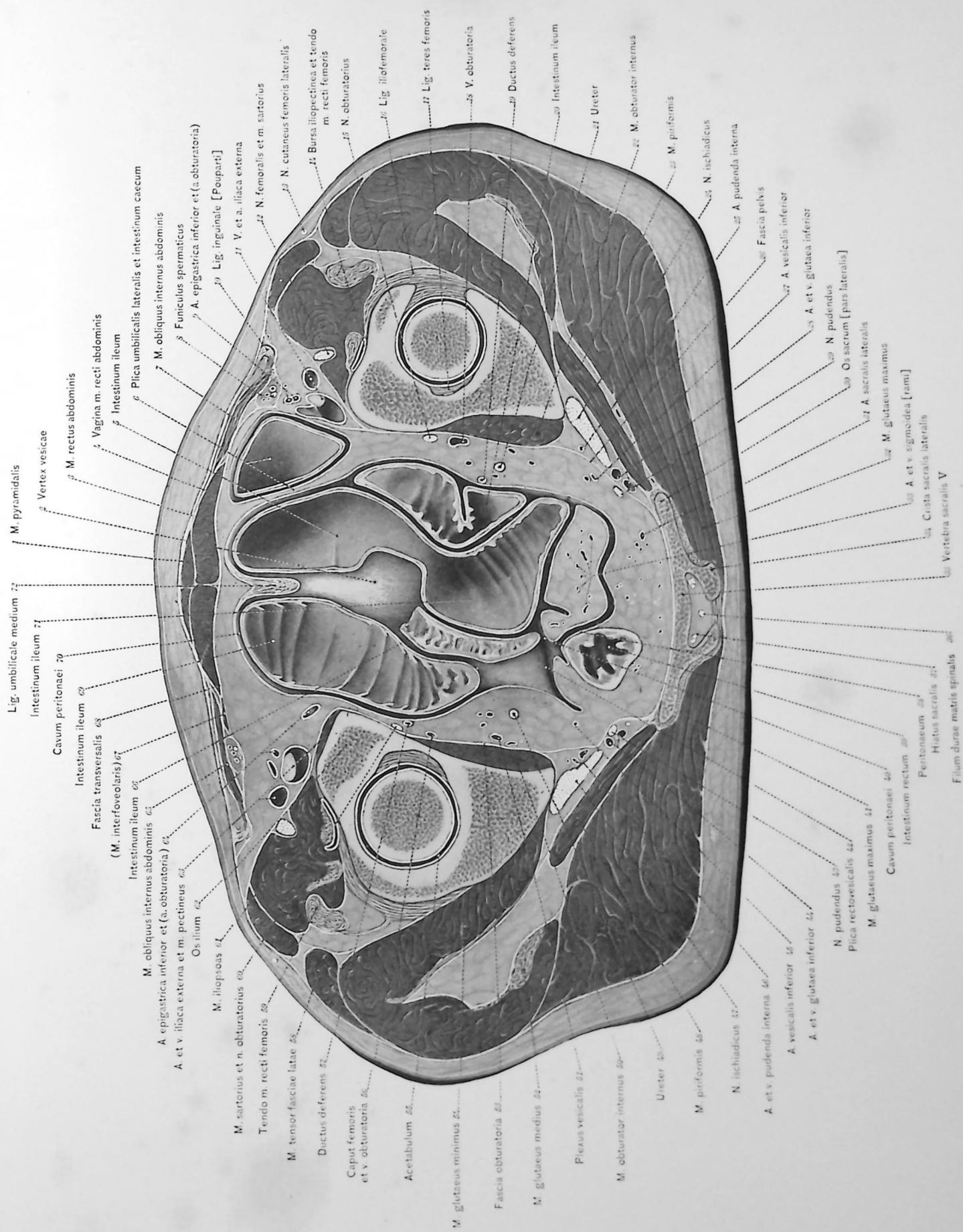
Note.—According to the observations of Bacarisse the sacrum here must be considered as composed of six vertebræ.

The m. interfoveolaris (67) which is variable has been labeled following Spalteholtz, although it is not given in the BNA.

The vesical veins (51) although described by Toldt, Spalteholtz and others, are not recognized in the BNA but are included under the plexus vesicalis.

The term plica rectovesicalis (42) is not given in the BNA, it being considered by the revision commission simply as a fold over the m. rectovesicalis. We have followed Spalteholtz in retaining the name.

We have labeled the v. pudenda interna (46) following Toldt, Spalteholtz, Krause, and others, although the term is not given in the BNA.



Lig. umbilicale medium 77
 Intestinum ileum 71
 Cavum peritoneae 70
 Intestinum ileum 69
 Fascia transversalis 68
 (M. interfoveolaris) 67
 Intestinum ileum 66
 (M. interfoveolaris) 65

M. obliquus internus abdominis 64
 A. epigastrica inferior et (a. obturatoria) 63
 A. et v. iliaca externa et m. pectineus 62
 Os ilium 61
 M. iliopsoas 60
 M. sartorius et n. obturatorius 59
 Tendo m. recti femoris 58
 M. tensor fasciae latae 57
 Ductus deferens 56
 Caput femoris et v. obturatoria 55
 Acetabulum 54
 M. gluteus minimus 53
 Fascia obturatoria 52
 M. gluteus medius 51
 Plexus vesicalis 50
 M. obturator internus 49
 Ureter 48
 M. piriformis 47
 N. ischiadicus 46
 A. et v. pudenda interna 45
 A. vesicalis inferior 44
 A. et v. glutaea inferior 43
 N. pudendus 42
 Plica rectovesicalis 41
 M. gluteus maximus 40
 Cavum peritoneae 39
 Intestinum rectum 38
 Peritoneum 37
 Hiatus sacralis 36
 Filum durnae matris spinalis 35

M. rectus abdominis 34
 Vagina m. recti abdominis 33
 Intestinum ileum 32
 Plica umbilicalis lateralis et intestinum caecum 31
 M. obliquus internus abdominis 30
 Funiculus spermaticus 29
 A. epigastrica inferior et (a. obturatoria) 28
 Lig. inguinale [Poupart] 27
 V. et a. iliaca externa 26
 N. femoralis et m. sartorius 25
 N. cutaneus femoris lateralis 24
 Bursa iliopectinea et tendo m. recti femoris 23
 N. obturatorius 22
 Lig. iliofemorale 21
 Lig. teres femoris 20
 V. obturatoria 19
 Ductus deferens 18
 Intestinum ileum 17
 Ureter 16
 M. obturator internus 15
 M. piriformis 14
 N. ischiadicus 13
 A. pudenda interna 12
 Fascia pelvis 11
 A. vesicalis inferior 10
 A. et v. glutaea inferior 9
 N. pudendus 8
 Os sacrum [pars lateralis] 7
 A. sacralis lateralis 6
 M. gluteus maximus 5
 A. et v. sigmoidea [ram.] 4
 Crista sacralis lateralis 3
 Vertebra sacralis V 2

M. pyramidalis 1
 Vertex vesicae 2

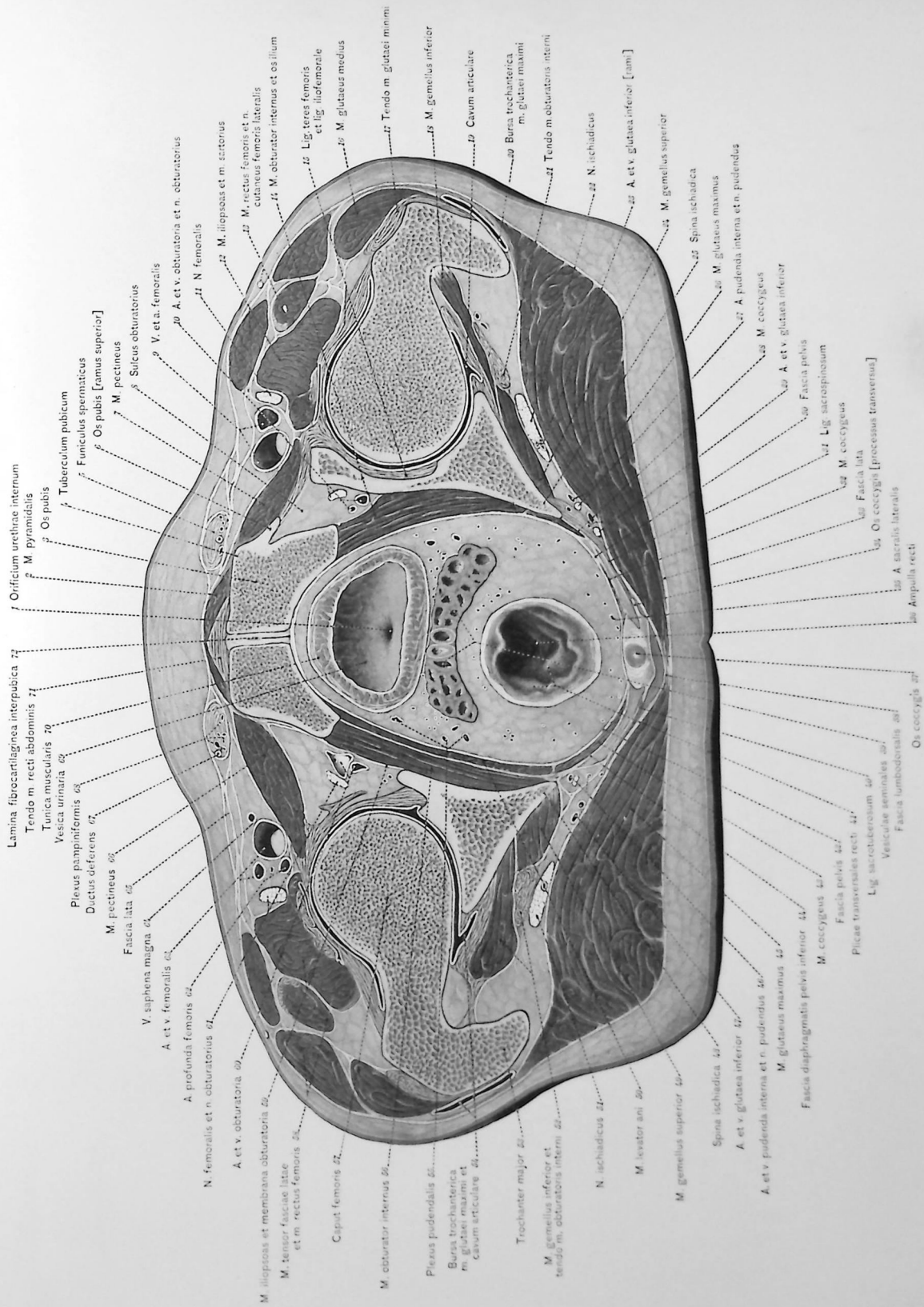
Section 41

Section 41

This section is about 22 mm. below the preceding section. Its level is indicated by line 41 in Key-figures IV, V, VI, VII.

The section passes through the coccyx (37), the spine of the ischium (25, 48), the lower portion of the acetabulum, the lower portion of the head of the femur (57), and the greater trochanter (53); through the upper portion of the pubic symphysis (72) and the upper margins of the obturator foramina. The following muscles are cut for the first time: the gemellus inferior (52), gemellus superior (24, 49), the coccygeus (28, 32, 43), and the levator ani (50). The profunda artery on the right side arises from the femoral artery (9) in the body of the section. The internal saphenous vein (64), on the left side, enters the femoral vein in the preceding section; on the right side it enters the femoral vein in the upper part of this section. The rectum (36) lies in the median line at this level; its diameter greatly exceeds that shown in the preceding section. The section passes through the trigonum of the bladder about 5 mm. below the ureteral orifices. The urethral orifice (1) is well shown. The seminal vesicles (39) are cut, together with the ampulla of the vasa deferentia, which lie between them. The seminal vesicles extend to the middle of this section. The common ejaculatory ducts enter the urethra in the lower portion of this section. The prostate gland lies for the most part within this section.

Note.—The white area at the end of leader 29 represents the inferior gluteal artery.



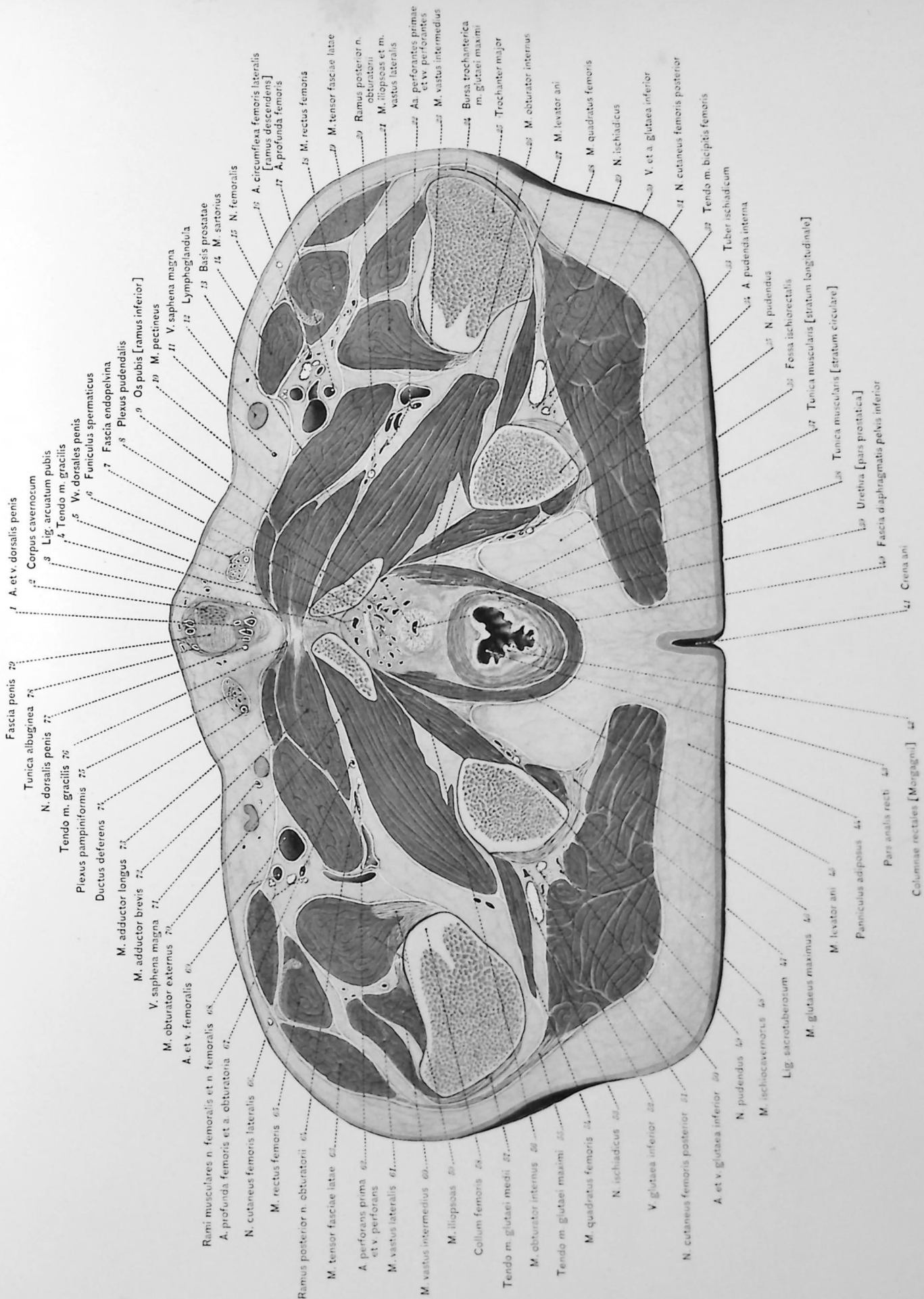
Lamina fibrocartilaginea interpubica 27
 Tendo m. recti abdominis 21
 Tunica muscularis 20
 Vesica urinaria 19
 Plexus pampiniformis 18
 Ductus deferens 17
 M. pectineus 16
 Fascia lata 15
 V. saphena magna 14
 A. et v. femoralis 13
 A. profunda femoris 12
 N. femoralis et n. obturatorius 11
 A. et v. obturatoria 10
 M. tensor fasciae latae et m. rectus femoris 9
 Caput femoris 8
 M. obductor internus 24
 Plexus pudendus 25
 Bursa trochanterica m. glutei maximi et cavum articulare 26
 Trochanter major 28
 M. gemellus inferior et tendo m. obturatoris interni 29
 N. ischiadicus 31
 M. levator ani 30
 M. gemellus superior 32
 Spina ischiadica 33
 A. et v. glutea inferior 34
 A. et v. pudenda interna et n. pudendus 36
 M. gluteus maximus 35
 Fascia diaphragmatis pelvis inferior 34
 M. coccygeus 37
 Fascia pelvis 38
 Plicae transversales recti 39
 Lig. sacrotuberorum 40
 Vesiculae seminales 41
 Fascia lumbodorsalis 42
 Os coccygis 27
 Anpilla recti 43
 Os sacrale lateralis 44
 Os coccygis 37
 Lig. sacrospinosum 45
 M. coccygeus 46
 Fascia lata 47
 M. coccygeus 48
 A. et v. glutea inferior 49
 Fascia pelvis 50
 M. coccygeus 51
 Lig. sacrospinosum 52
 A. et v. pudenda interna et n. pudendus 53
 M. gluteus maximus 54
 Spina ischiadica 55
 M. gemellus superior 56
 N. ischiadicus 57
 Bursa trochanterica m. glutei maximi 58
 Tendo m. obturatoris interni 59
 M. gemellus inferior 60
 Cavum articulare 61
 M. gluteus medius 62
 Lig. teres femoris et lig. iliofemorale 63
 M. obductor internus et os ilium 64
 M. rectus femoris et n. cutaneus femoris lateralis 65
 M. iliopsoas et m. sartorius 66
 N. femoralis 67
 A. et v. obturatoria et n. obturatorius 68
 V. et a. femoralis 69
 Sircus obturatorius 70
 M. pectineus 71
 Os pubis [ramus superior] 72
 Funiculus spermaticus 73
 Tuberculum pubicum 74
 Os pubis 75
 M. pyramidalis 76
 Orificium urethrae internum 77

Section 42

Section 42

This section is about 25 mm. below the preceding section. Its level is indicated by line 42 in Key-figures IV, V, VI, VII.

The section passes a little below the tip of the coccyx; through the subpubic ligament (3); through the upper portion of the tuberosity of the ischium (33) and the inferior ramus of the pubis (9); through the lower margin of the neck of the femur (58) and the lower portion of the greater trochanter (25). The following muscles are cut for the first time: the vastus externus (21, 61), the crureus (23, 60), ischio-cavernosus (48), adductor brevis (72), adductor longus (73), and the gracilis (4, 76). The obturator internus (26, 56) does not extend beyond this section. The rectum, at this level, shows a number of well-marked longitudinal folds, called the "columns of Morgagni" (42). The lower portion of the prostate gland (13) surrounds the prostatic portion of the urethra (39). The penis is cut at the angle, showing the corpus cavernosum (2). The fascial covering of the penis (79), the tunica albuginea (78), and the more important blood vessels and nerves are shown.

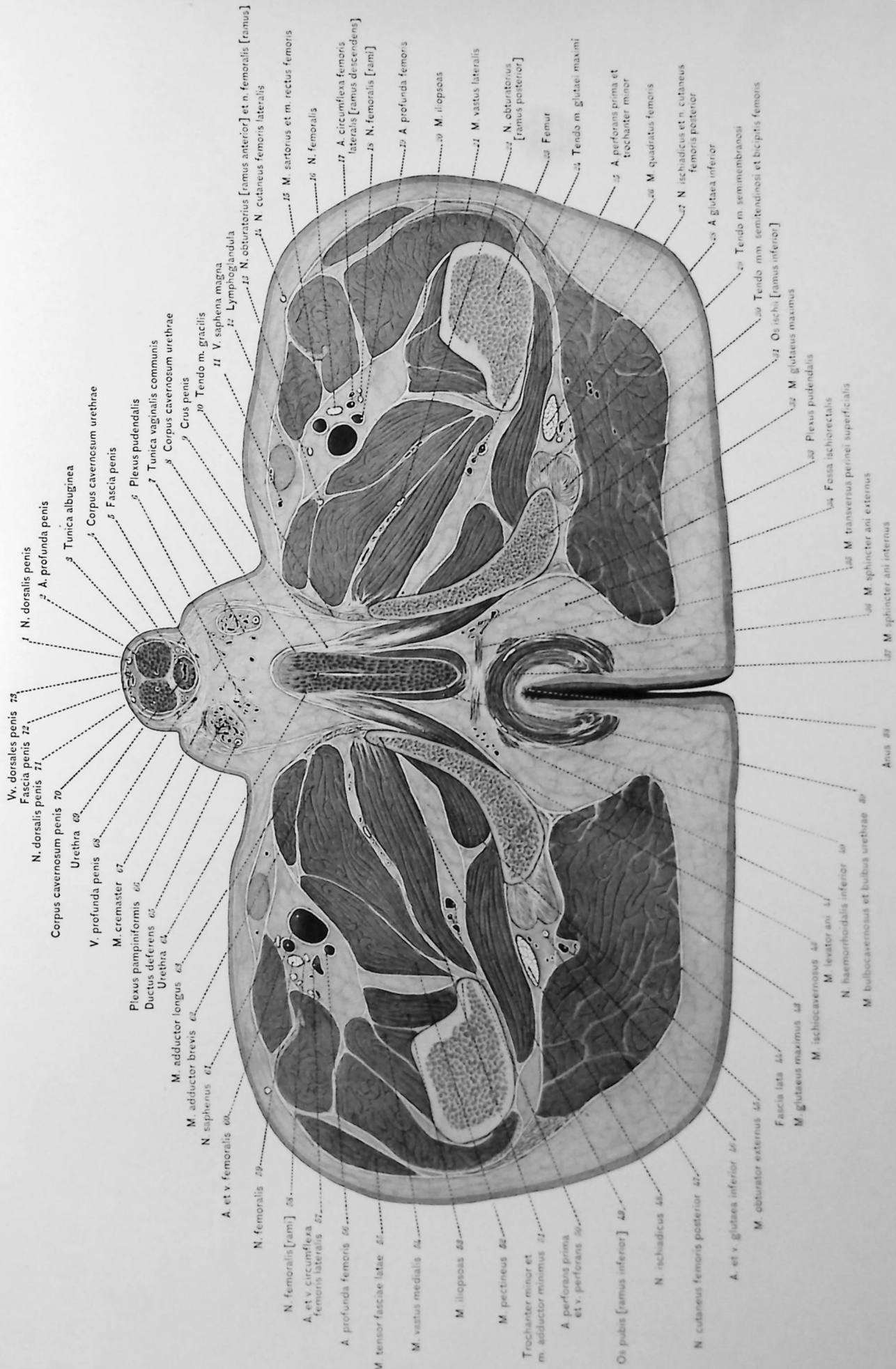


- 1 A. et v. dorsalis penis
- 2 Corpus cavernosum
- 3 Lig. arcuatum pubis
- 4 Tendo m. gracilis
- 5 Vv. dorsales penis
- 6 Funiculus spermaticus
- 7 Fascia endopelvina
- 8 Plexus pudendalis
- 9 Os pubis [ramus inferior]
- 10 M. pectineus
- 11 V. saphena magna
- 12 Lymphoglandula
- 13 Basis prostatae
- 14 M. sartorius
- 15 N. femoralis
- 16 A. circumflexa femoris lateralis [ramus descendens]
- 17 A. profunda femoris
- 18 M. rectus femoris
- 19 M. tensor fasciae latae
- 20 Ramus posterior n. obturatorii
- 21 M. iliopsoas et m. vastus lateralis
- 22 Aa. perforantes primae et iv. perforantes
- 23 M. vastus intermedius
- 24 Bursa trochanterica m. glutei maximi
- 25 Trochanter major
- 26 M. obturator internus
- 27 M. levator ani
- 28 M. quadratus femoris
- 29 N. ischiadicus
- 30 V. et a. gluteae inferior
- 31 N. cutaneus femoris posterior
- 32 Tendo m. bicipitis femoris
- 33 Tuber ischiadicum
- 34 A. pudenda interna
- 35 N. pudendus
- 36 Fossa ischiorectalis
- 37 Tunica muscularis [stratum longitudinale]
- 38 Tunica muscularis [stratum circulare]
- 39 Urethra [pars prostatica]
- 40 Fascia diaphragmatis pelvis inferior
- 41 Crena ani
- 42 Columnae rectales [Morgagni]
- 43 Pars analis recti
- 44 Panniculus adiposus
- 45 M. levator ani
- 46 M. gluteus maximus
- 47 Lig. sacrotuberorum
- 48 M. ischioavernosus
- 49 N. pudendus
- 50 A. et v. gluteae inferior
- 51 N. cutaneus femoris posterior
- 52 V. gluteae inferior
- 53 N. ischiadicus
- 54 M. quadratus femoris
- 55 Tendo m. glutei maximi
- 56 M. obturator internus
- 57 Tendo m. glutei medii
- 58 Collum femoris
- 59 M. iliopsoas
- 60 M. vastus intermedius
- 61 M. vastus lateralis
- 62 A. perforans prima et v. perforans
- 63 M. tensor fasciae latae
- 64 Ramus posterior n. obturatorii
- 65 M. rectus femoris
- 66 N. cutaneus femoris lateralis
- 67 A. et v. femoralis
- 68 M. obturator externus
- 69 V. saphena magna
- 70 M. adductor brevis
- 71 Ductus deferens
- 72 Plexus pampiniformis
- 73 Tendo m. gracilis
- 74 N. dorsalis penis
- 75 Tunica albuginea
- 76 Fascia penis
- 77 A. et v. dorsalis penis

Section 43

This section is about 25 mm. below the preceding section. Its level is indicated by line 43 in Key-figures IV, V, VI, VII.

The section passes through the inferior ramus of the pubis (49); through the ramus of the ischium (31); through the femur (23) at the level of the middle of the lesser trochanter (25, 51). The following muscles are cut for the first time: the semimembranosus (29), the semitendinosus (30), the biceps femoris (30), transversus perinei superficialis (35), sphincter ani externus (36), sphincter ani internus (37), the bulbocavernosus (39), and the cremaster (67). The following muscles do not extend beyond this section: the quadratus femoris (26), sphincter ani externus (36), sphincter ani internus (37), levator ani (41), the ischiocavernosus (42), obturator externus (45), and the iliopsoas (20, 53). The anus does not extend much beyond the upper surface of this section, its anterior margin (38) being the only portion shown. The section passes obliquely through the root of the penis (radix penis), and again through the proximal portion of the body of the penis.



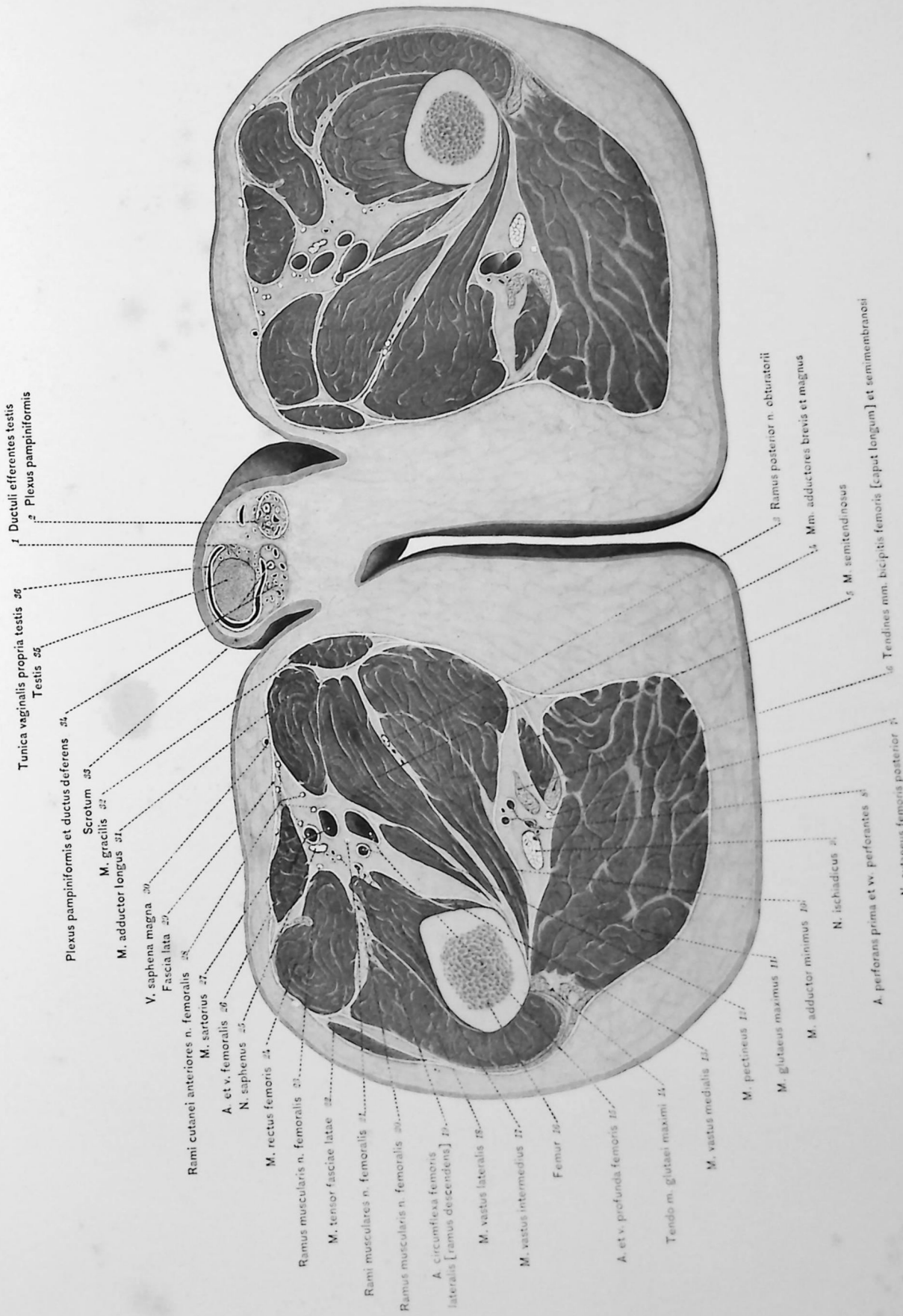
SECTION 43

Section 44

Section 44

This section is about 25 mm. below the preceding section. Its level is indicated by line 44 in Key-figures IV, V, VI, VII. The structures on the right side correspond so closely to those on the left side that a duplicate set of labels would be superfluous.

The section passes through the femur (16), through the scrotum (33), through the upper portion of the left testicle (35), and through the epididymis, showing the efferent tubules of the same (1). The cavity of the scrotum shows its lining membrane, the tunica vaginalis, the parietal layer of which is labeled at 36. The vas deferens (34) is shown on either side, but is labeled on the left side only. The vascular plexus (2, 34) is likewise shown on either side.



1 Ductuli efferentes testis
2 Plexus pampiniformis

Tunica vaginalis propria testis 36
Testis 35

Plexus pampiniformis et ductus deferens 34
Scrotum 33
M. gracilis 32
M. adductor longus 31

V. saphena magna 29
Fascia lata 28
M. adductor longus 31
M. sartorius 27

Rami cutanei anteriores n. femoralis
A. et v. femoralis 26
N. saphenus 25
M. rectus femoris 24

Ramus muscularis n. femoralis 31
M. tensor fasciae latae 32

Rami musculares n. femoralis 30
M. vastus lateralis 18
M. vastus intermedius 17
Femur 16

Ramus muscularis n. femoralis 30
A. circumflexa femoris lateralis [ramus descendens] 21
M. vastus lateralis 18
M. vastus intermedius 17
Femur 16

A. et v. profunda femoris 15
Tendo m. glutei maximi 14
M. vastus medialis 13

M. pectineus 12
M. gluteus maximus 11
M. adductor minimus 10
N. ischiadicus 9

A. perforans prima et vv. perforantes 8
N. cutaneus femoris posterior 7

3 Ramus posterior n. obturatorii
4 Mm. adductores brevis et magnus
5 M. semitendinosus

6 Tendines mm. bicipitis femoris [caput longum] et semimembranosi

SECTION 44

Key-figure VIII

Key-figure VIII

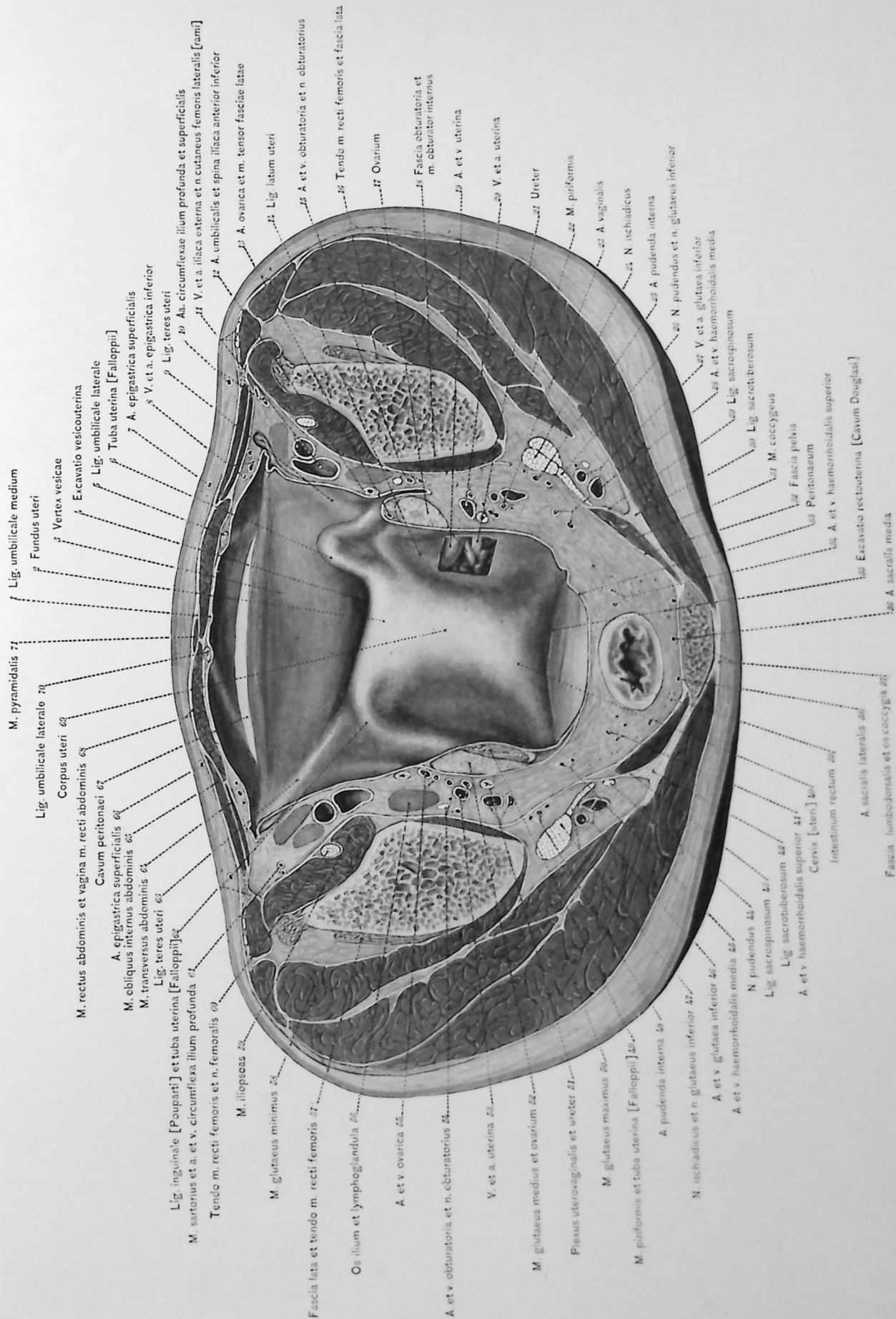
This Key-figure was made by replacing sections 45 to 49 in their normal relations and cutting them in the mesial sagittal plane. The sections included in this series show the more important structures of the female pelvis, although the entire pelvic region is not shown. Strictly speaking, the pelvis begins posteriorly at the promontory of the sacrum. Anteriorly a portion of the abdominal cavity is necessarily shown. From this it will be apparent that the designation "Female Pelvis" is only in general correct. Two cut portions of the small intestine, lying on the fundus of the bladder together with the free border of the omentum which was slightly adherent to the fundus of the uterus, have been removed. The uterus is somewhat elevated by the distended ampulla of the rectum and the full bladder.

Section 45

Section 45

This is the first section of the female pelvis. Its level is indicated by line 45 in Key-figure VIII.

The section passes just below the junction of the sacrum and coccyx; through the anterior inferior spine of the ilium (12) and the great sciatic notch. The greater (30, 42) and lesser (29, 43) sciatic ligaments are separated. The external oblique muscle is represented by its aponeurosis. Poupart's ligament (62) is shown. The internal oblique muscle (65) and the transversalis muscle (64) are closely associated with it. The obliterated hypogastric artery (5) shows a persistent lumen in its proximal portion (12). The deep epigastric (8) and deep circumflex iliac (10, 61) arteries arise within the section from the external iliac. The dissection on the right side of the uterus shows the uterine artery and vein (19) and the ureter (21). The pudic vessels (25, 48) leave the pelvic cavity within the section and curve around the spine of the ischium. The superior hemorrhoidal vessels (34, 41) are shown. The great sciatic nerve (24, 47), the inferior gluteal nerve (26), and the pudic nerve (26, 44) have passed out of the pelvic cavity. The lesser sciatic nerve lies just external to the inferior gluteal artery (27). The uterus (69) lies on the apex of the somewhat distended bladder (3). The round ligament (9, 63) curves over the deep epigastric artery (8) in the middle of the section. The ovaries (17, 52) are cut through their upper portions.

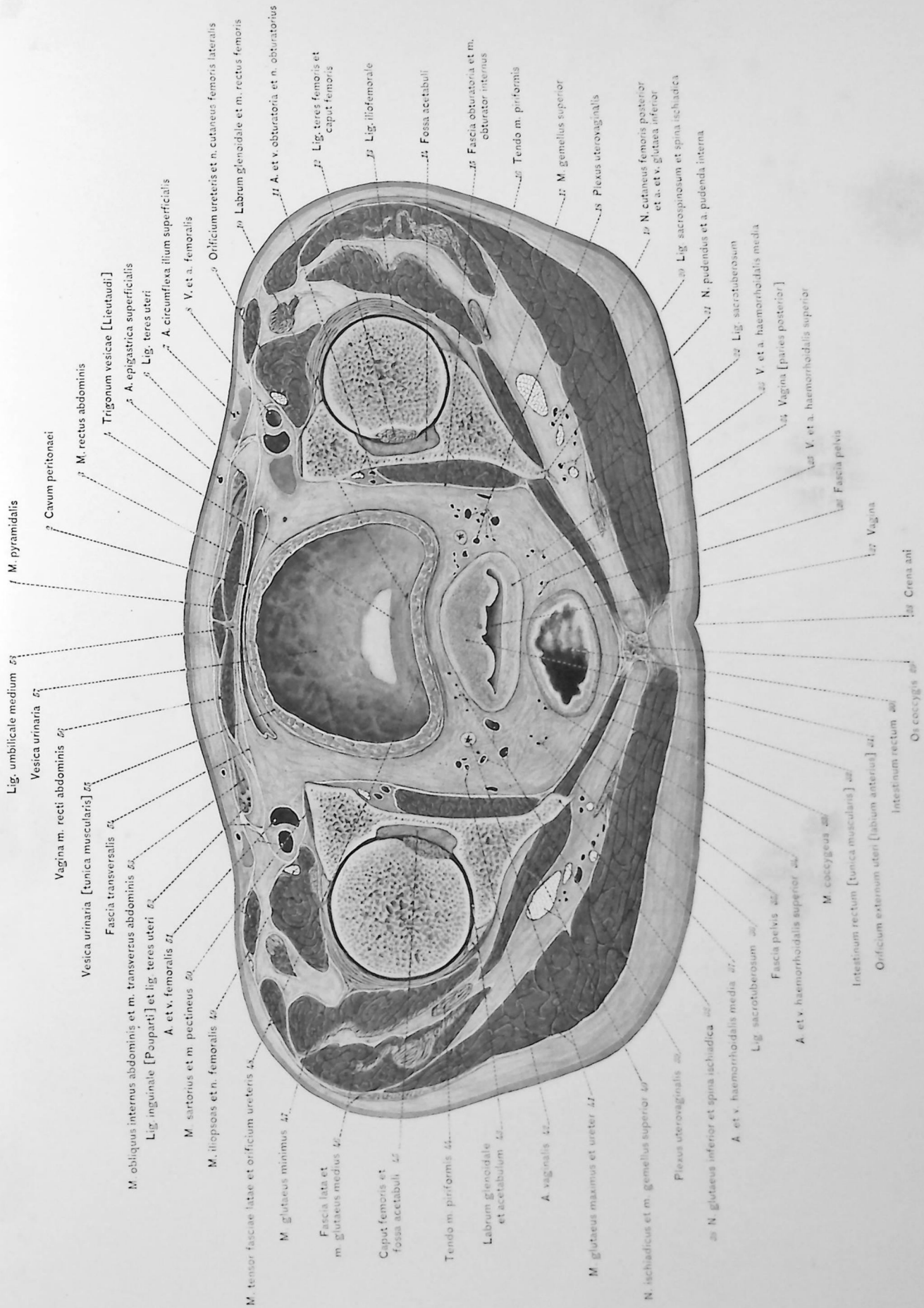


Section 46

Section 46

This section is about 26 mm. below the preceding section. Its level is indicated by line 46 in Key-figure VIII.

The section passes through the lower part of the coccyx (29) and the spine of the ischium (20, 38); through the middle of the acetabulum (43) and through the acetabular fossæ (14, 45), cutting the head of the femur (12, 45). The great sciatic ligament (22, 36) is distinctly shown, as is also the attachment of the lesser sciatic ligament to the spine of the ischium (20). The capsule of the hip-joint and the cotyloid ligaments (10, 43) are cut. The attachment of the ligamentum teres (12) is shown. The following muscles first appear: the superior gemelli muscles (17, 40) and the pectineus muscle (50). The coccygeus muscle (33) does not extend beyond this section. The tendons (16, 44) of the piriformis muscles insert in the middle third of the section. The glutæus maximus (41), glutæus medius (46), and the glutæus minimus (47) muscles all begin their insertions in the lower third of the section. The two heads of origin of the rectus femoris muscle (10) have united. The internal oblique and transversalis muscles (53) have united. The relation of Poupart's ligament (52) to the transversalis fascia (54) is shown. The external abdominal rings lie in the lower third of the section. The pudic artery and nerve (21) are at this level outside the pelvic cavity. The relation of the femoral vein and artery (8, 51) to the anterior crural nerve (49) is shown where these structures pass into Scarpa's triangle. Several veins (18, 39) of the utero-vaginal plexus are cut. The external os of the cervix is cut, and shows the anterior lip (31). The ureters pass obliquely inward, and empty into the bladder at 9 and 48. A small portion of the peritoneal cavity (2) is shown.



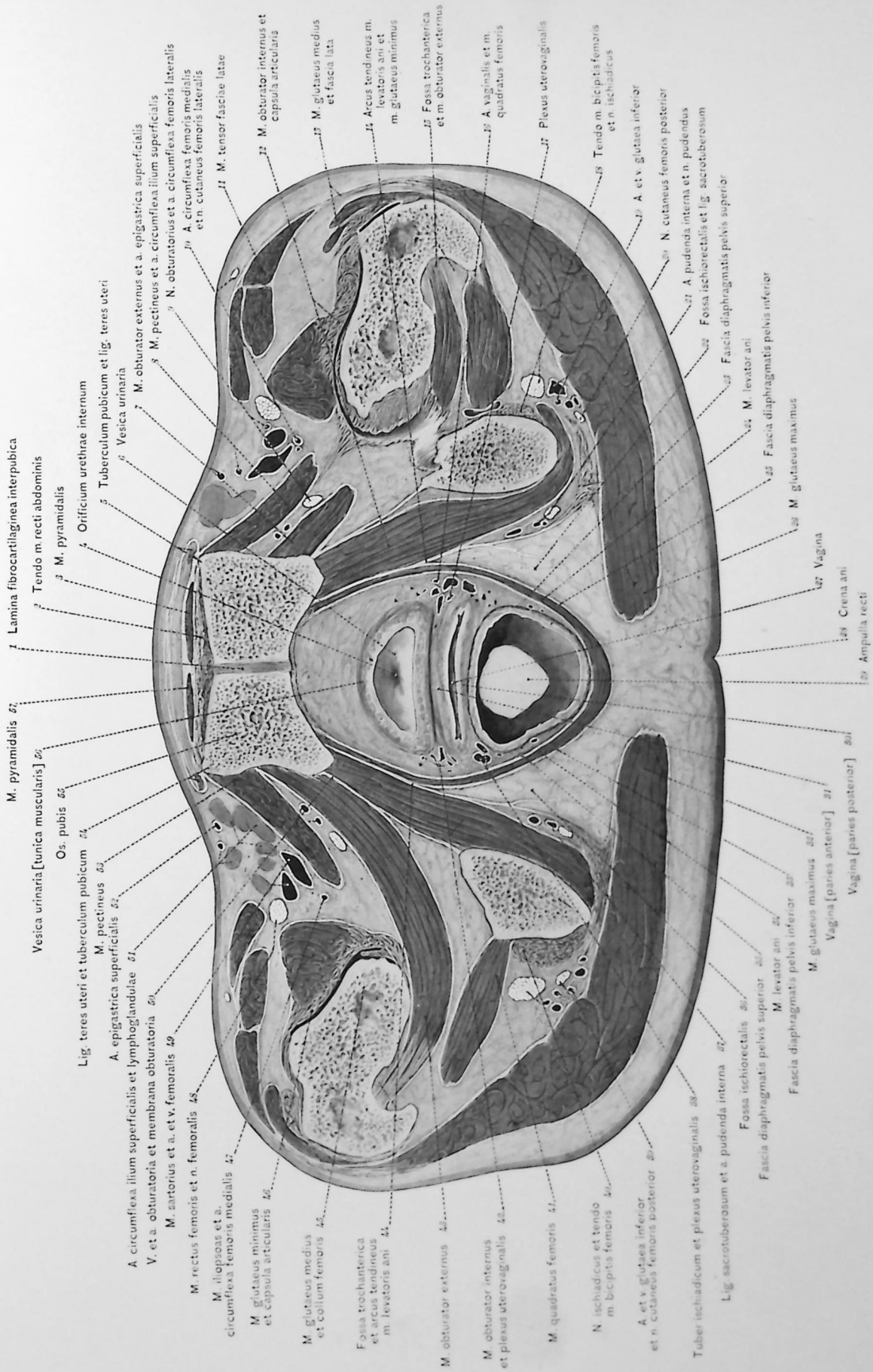
SECTION 46

Section 47

Section 47

This section is about 28 mm. anteriorly and 25 mm. posteriorly below the preceding section. Its level is indicated by line 47 in Key-figure VIII.

The section passes through the upper part of the pubic symphysis (1), cutting the pubic spines (5, 54); through the tuberosity of the ischium (38) on the left side, and through the lesser sciatic notch on the right side. The section cuts the neck of the femur (45) and the lower portion of the capsule (12, 46) of the hip-joint. The obturator membrane (50) extends across the obturator foramen. The following muscles are cut for the first time: the obturator externus (7, 15, 43), quadratus femoris (16), the biceps femoris (18, 40), and the levator ani (24, 34). The following muscles do not extend beyond this section: the rectus abdominis (2), pyramidalis (3, 57), obturator internus (12), glutæus medius (13), and glutæus minimus (46). The external (9) and internal (10) circumflex arteries on the right side and the internal circumflex artery (47) on the left side are cut just below their origins from the femoral artery. The superficial external iliac artery (8, 51) and the superficial epigastric arteries (7, 52) arise within the section. The internal saphenous vein on either side empties into the femoral in the middle of the section. The pudic vessels and nerves (21, 37) have returned to the pelvic cavity. The ampulla of the rectum (29), the bladder (6), with the internal orifice of the urethra (4), and the vagina (27), are all surrounded by the levator ani muscle (24, 34). Anteriorly, several lymph glands (51) are shown in the region of the saphenous opening.



SECTION 47

Section 48

Section 48

This section is about 25 mm. anteriorly and 23 mm. posteriorly below the preceding section. Its level is indicated by line 48 in Key-figure VIII.

The section passes through the tuberosity (20) and the inferior ramus (30) of the ischium. It cuts the femur just above the lesser trochanter. The following muscles are cut for the first time: the adductor longus (4, 44), adductor brevis (5, 45), adductor minimus (6, 35), vastus externus (12, 38), ischiocavernosus (17, 38), crureus (37), and the gracilis (46). The iliopsoas muscle (13, 36) does not extend beyond the section. The external circumflex artery (10) shows on the right side. The profunda artery (39), the hemorrhoidal vessels (21, 29), and the internal saphenous veins (7, 42) are first seen in this section. The internal circumflex vessels (14, 33) have passed to the postero-mesial side of the femur. The obturator nerves have divided into their anterior (41) and posterior (11) branches. The anterior crural nerve has divided into numerous branches (39). The internal (26) and external (23) sphincter ani muscles are shown. The vagina (43) is cut just above its vestibule, and the urethra (49) is seen in front of the vagina. The crura of the clitoris, with the erector muscle of the clitoris (17, 38), and the corpora cavernosa (2, 47) are shown. The round ligaments (3, 48) enter the labia majora in the upper portion of the section.

Section 49

Section 49

This section is about 21 mm. anteriorly and 23 mm. posteriorly below the preceding section. Its level is indicated by line 49 in Key-figure VIII.

The femur is cut just below the trochanter minor on the left side, and through the lower portion of the trochanter minor (13) on the right side. The vastus internus muscle (10, 32) first appears. The following muscles do not extend beyond the section: the iliopsoas (11), adductor minimus (14, 29), glutæus maximus (18, 24), pectineus (30), tensor of the fascia lata (31), adductor brevis (32). The great sciatic nerves (15, 27) lie anterior to the hamstring muscles (15, 16, 26, 27). The anus (21), with its two sphincter muscles (20, 23), is shown. Anteriorly are the prepuce (1) and the glans of the clitoris (39), with the labia majora (2) at either side.

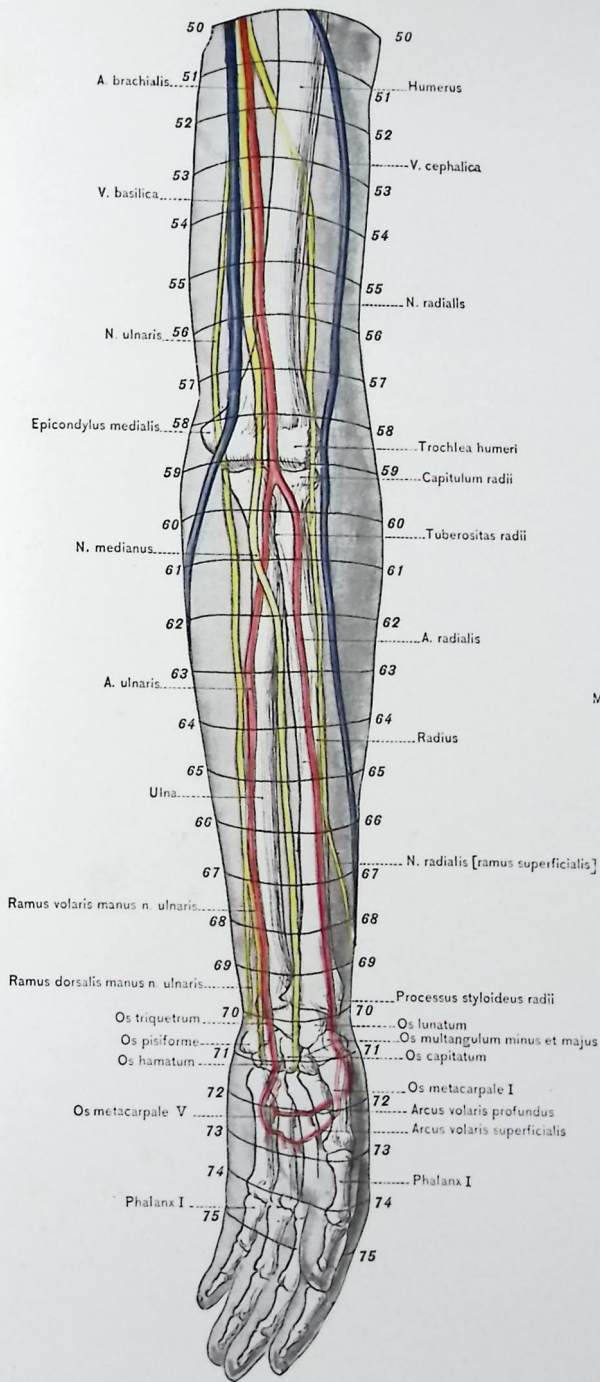
Key-figures IX and X

Key-figure IX

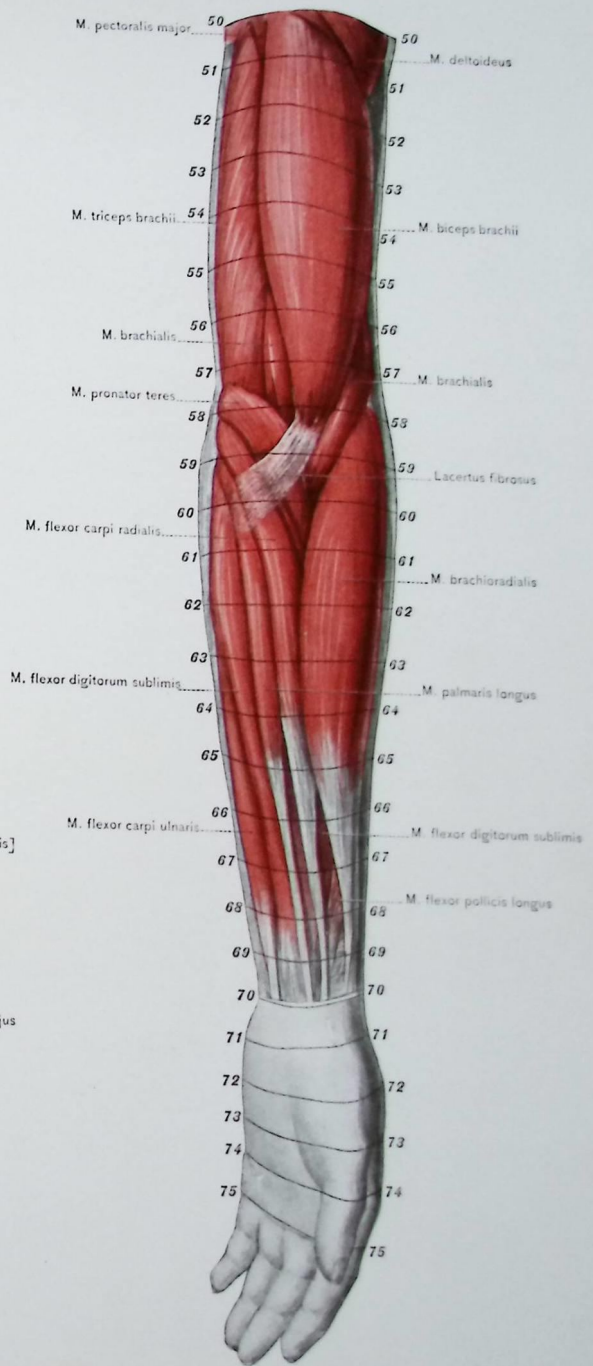
This Key-figure was made entirely by reconstruction. It represents a front view of the left arm, excepting that portion which has been shown in connection with the trunk. The bones, together with the principal arteries, veins, and nerves, are shown in conventional colors. The levels of the sections with reference to the various structures are indicated by the transverse lines 50-75.

Key-figure X

This Key-figure was made entirely by reconstruction. It represents a front view of the left arm, excepting that portion which has been shown in connection with the trunk. The levels of the sections with reference to the principal muscles are indicated by the transverse lines 50-75.



KEY-FIGURE IX



KEY-FIGURE X

Sections 50, 51, 52, 53

Section 50

This section is the first of those arbitrarily placed in the arm series. It should be recalled, however, that a considerable portion of the arm has been considered in connection with the trunk. The level of the section is indicated by line 50 in Key-figures IX, X.

The section passes through the upper third of the humerus (19). The pectoralis major muscle (21) and the tendon (13) of the latissimus dorsi muscle disappear in this section. The superior profunda artery (10) takes origin from the brachial just above this level, and is here shown for the first time. The cephalic vein (20) pierces the fascia in the section. The basilic vein (6) has not united with the brachial (9) at this level. The following nerves are shown: the musculocutaneous (2), the internal cutaneous (5), the median (7), the ulnar (8), the lesser internal cutaneous (11), and the radial (12).

Section 51

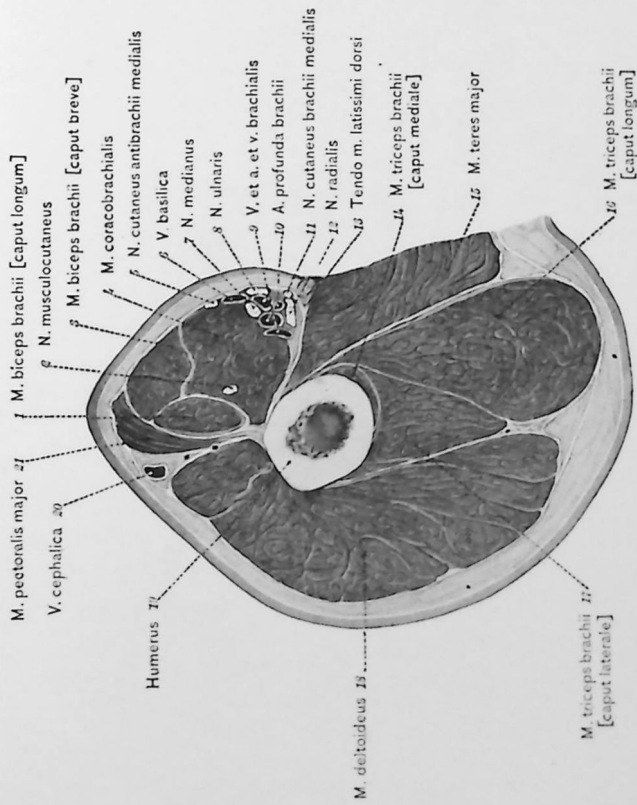
This section is about 27 mm. below the preceding section. Its level is indicated by line 51 in Key-figures IX, X. The intermuscular septa (4, 16) are first observed at this level.

Section 52

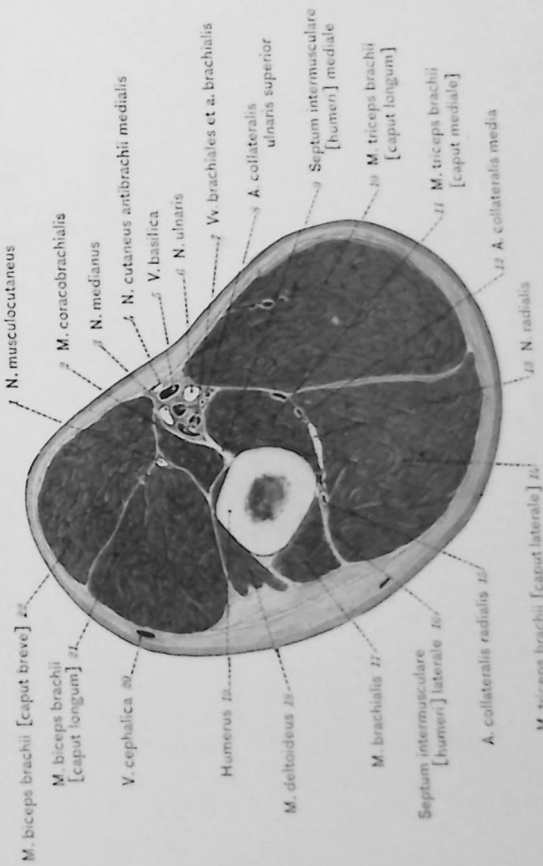
This section is about 24 mm. below the preceding section. Its level is indicated by line 52 in Key-figures IX, X. The brachialis anticus muscle (17) is first seen at this level. The coracobrachialis muscle (2) and the deltoid muscle (18) disappear in this section. The two heads of the biceps (21, 22) fuse within this section. The inferior profunda artery (8) takes origin from the brachial artery in the section above.

Section 53

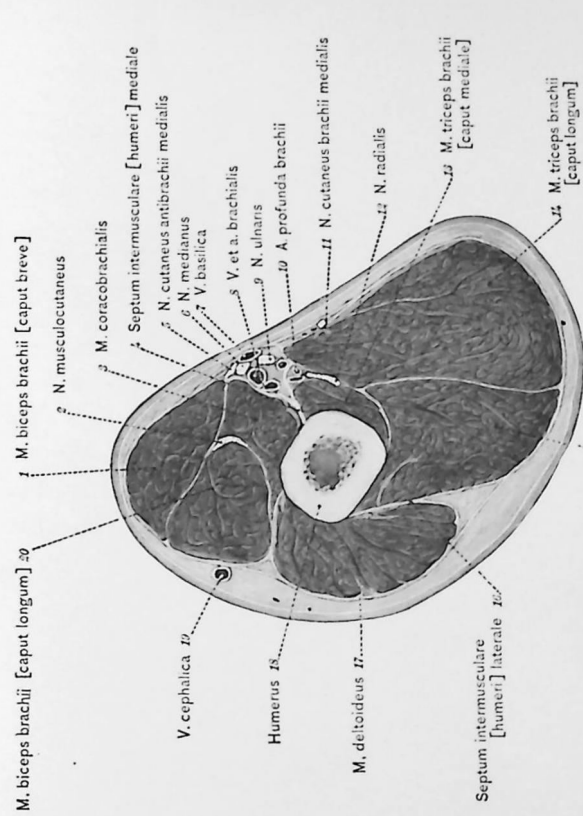
This section is about 25 mm. below the preceding section. Its level is indicated by line 53 in Key-figures IX, X. The external cutaneous branch (17) of the musculospiral nerve (14) first appears in this section. The musculocutaneous nerve (1), after giving off its last muscular branches at this level, is designated as the n. cutaneus antibrachii lateralis.



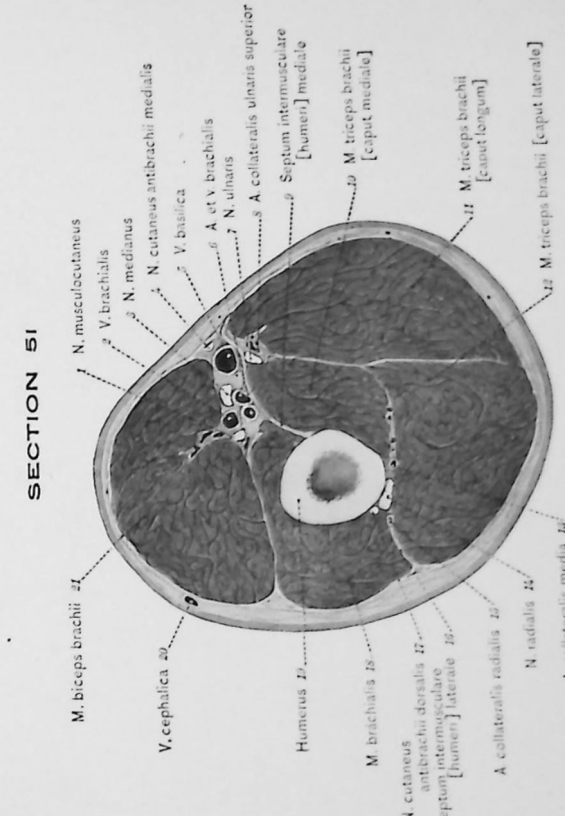
SECTION 50



SECTION 52



SECTION 51



SECTION 53

Sections 54, 55, 56, 57

Section 54

This section is about 27 mm. below the preceding section. Its level is indicated by line 54 in Key-figures IX, X. The three heads of the triceps brachii muscle (10) are fused at this level.

Section 55

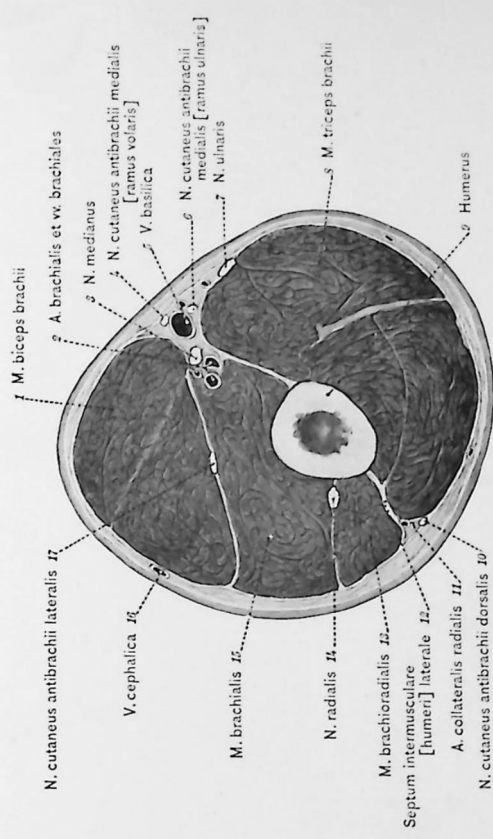
This section is about 27 mm. below the preceding section. Its level is indicated by line 55 in Key-figures IX, X. The brachioradialis muscle (13) first appears. The internal cutaneous nerve divides into the volar (4) and ulnar (6) branches.

Section 56

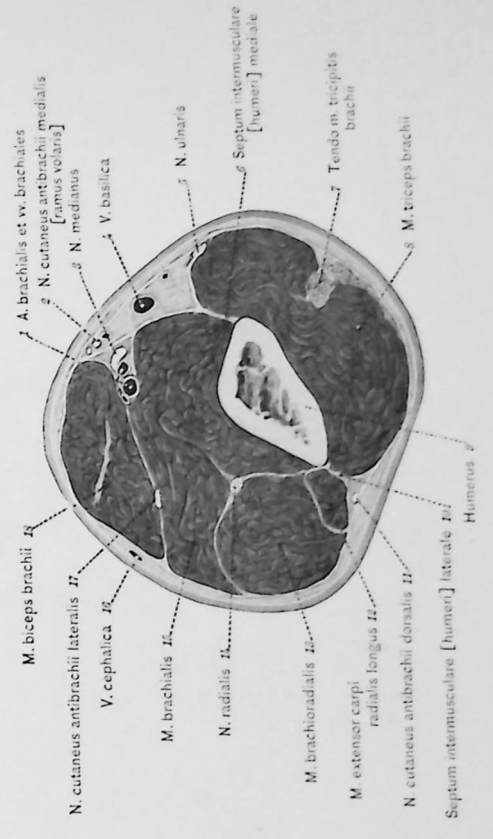
This section is about 27 mm. below the preceding section. Its level is indicated by line 56 in Key-figures IX, X.

Section 57

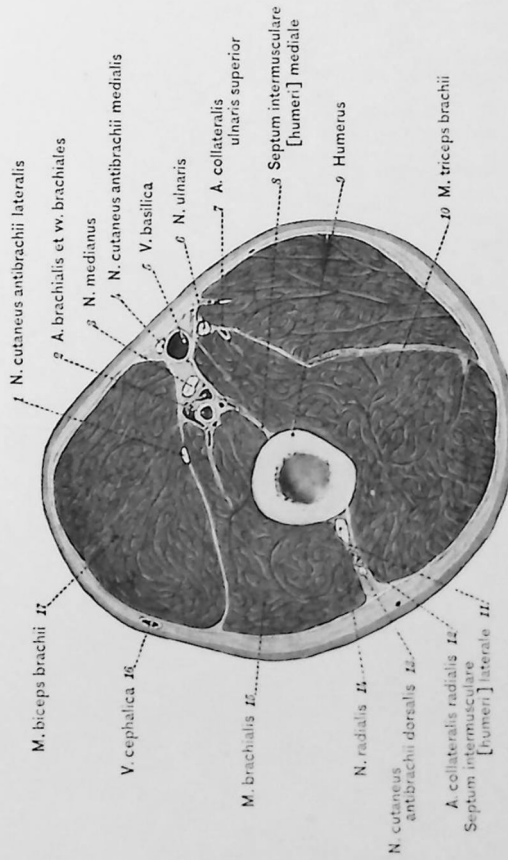
This section is about 28 mm. below the preceding section. Its level is indicated by line 57 in Key-figures IX, X. The extensor carpi radialis longus muscle (12) is cut for the first time.



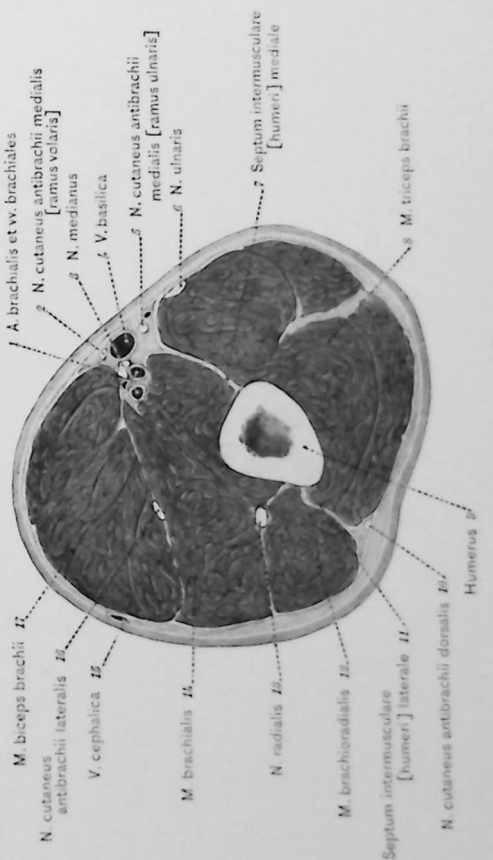
SECTION 55



SECTION 57



SECTION 54



SECTION 56

Sections 58, 59, 60, 61

Section 58

This section is about 23 mm. below the preceding section. Its level is indicated by line 58 in Key-figures IX, X.

The section passes through the medial (7) and lateral epicondyles (14), also through the following fossæ: the coronoid (4), the olecranon (10), and the radial (17). The articular capsule of the joint (11) is well defined.

Section 59

The section is about 24 mm. below the preceding section. Its level is indicated by line 59 in Key-figures IX, X.

The section passes through the lower portion of the condyles of the humerus, the cut-off portions having been removed to show the articular surface of the radius (22) and the greater sigmoid cavity of the ulna (8). The following muscles first appear: the flexor carpi radialis (6), palmaris longus (9), flexor digitorum profundus (15), anconæus (17), extensor digiti quinti proprius (19), extensor carpi radialis longus (21), and the extensor carpi radialis brevis (21). The orbicular ligament (18, 23) and the bicipital fascia (31) are shown. The anastomotica magna artery (1) is shown.

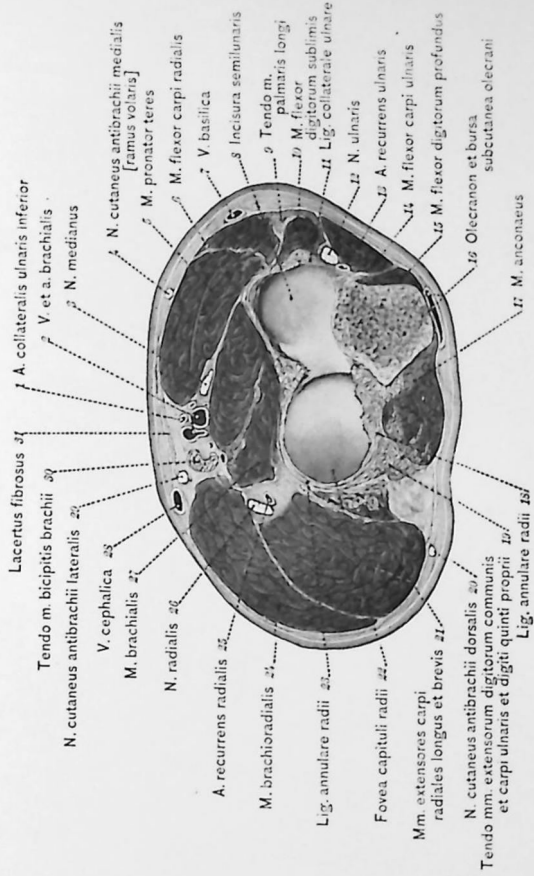
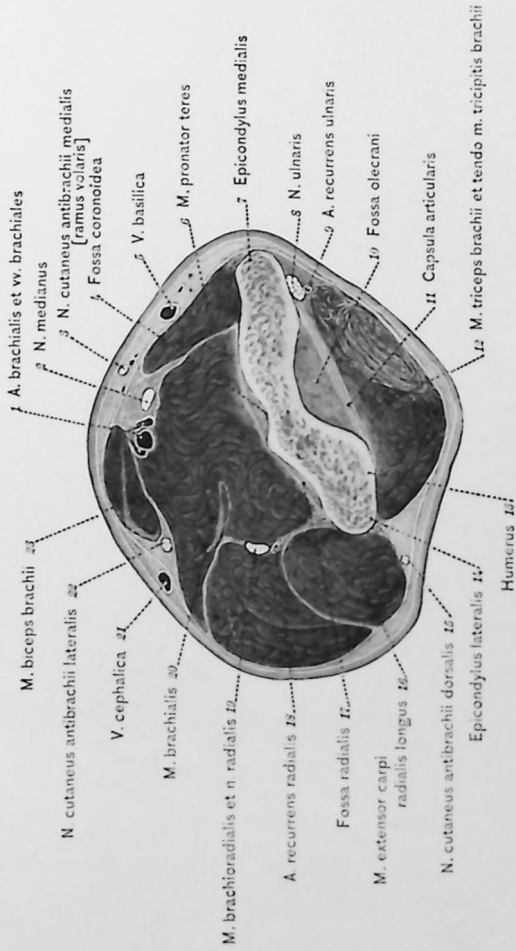
Section 60

This section is about 25 mm. below the preceding section. Its level is indicated by line 60 in Key-figures IX, X.

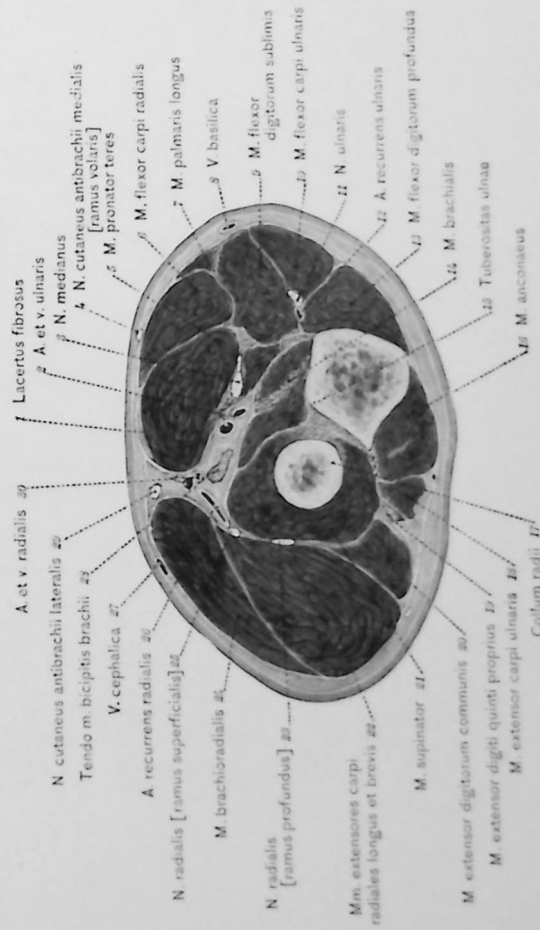
The section passes through the tuberosity (15) of the ulna and through the neck of the radius (17). The crista for the supinator muscle shows on the radial surface of the ulna. The supinator muscle (21) first appears in this section. The brachialis muscle (14) does not extend beyond this section. The brachial artery has divided in the upper part of the preceding section into the ulnar (2) and the radial (30) arteries. The radial and ulnar recurrent arteries arise in this section. The musculospiral nerve (n. radialis) gives rise in the section above to the radial (25) and the posterior interosseous (23).

Section 61

This section is about 25 mm. below the preceding section. Its level is indicated by line 61 in Key-figures IX, X. The tendon of the biceps muscle (2) does not extend beyond this section. The interosseous membrane (14) begins in the preceding section.

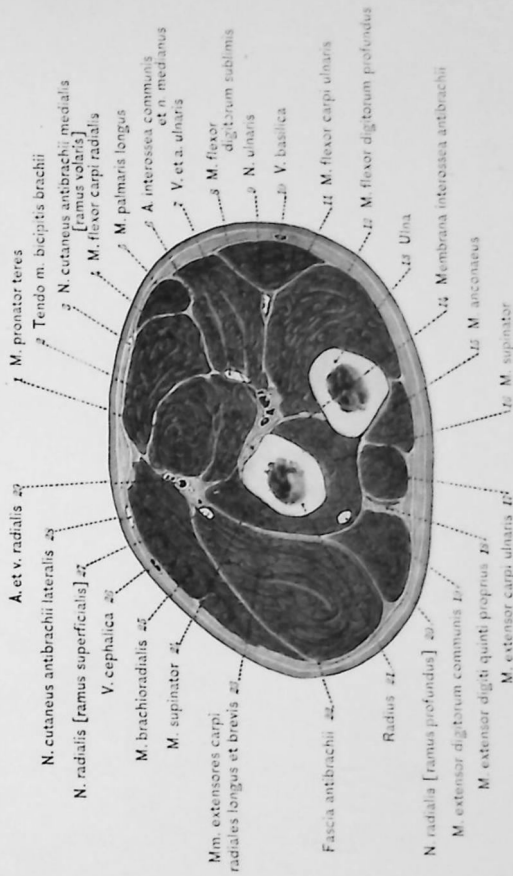


SECTION 58



SECTION 60

SECTION 59



SECTION 61

Sections 62, 63, 64, 65

Section 62

This section is about 28 mm. below the preceding section. Its level is indicated by line 62 in Key-figures IX, X. The extensor pollicis longus muscle (13) and the flexor pollicis longus muscle (24) first appear. The anconeus muscle (14) does not extend beyond this section. The common interosseous artery has given rise in the preceding section to the anterior interosseous artery (2) and the posterior interosseous artery (16). The anterior interosseous nerve appears (2).

Section 63

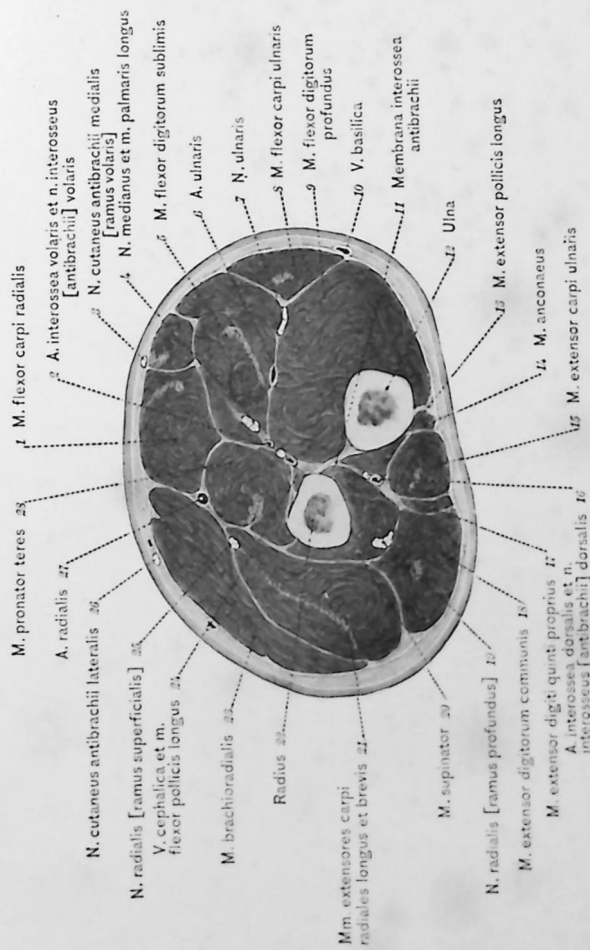
This section is about 29 mm. below the preceding section. Its level is indicated by line 63 in Key-figures IX, X. The supinator muscle (18) does not extend beyond this section. The deep branch of the radial nerve, shown at 19 in the preceding section, has given rise to the muscular and the posterior interosseous (14) branches.

Section 64

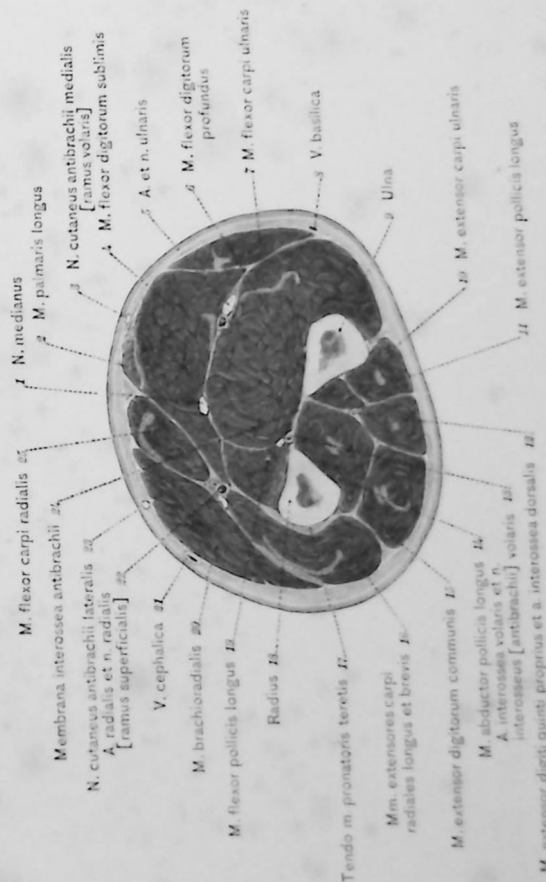
This section is about 27 mm. below the preceding section. Its level is indicated by line 64 in Key-figures IX, X. The pronator teres muscle (17) does not extend beyond this section.

Section 65

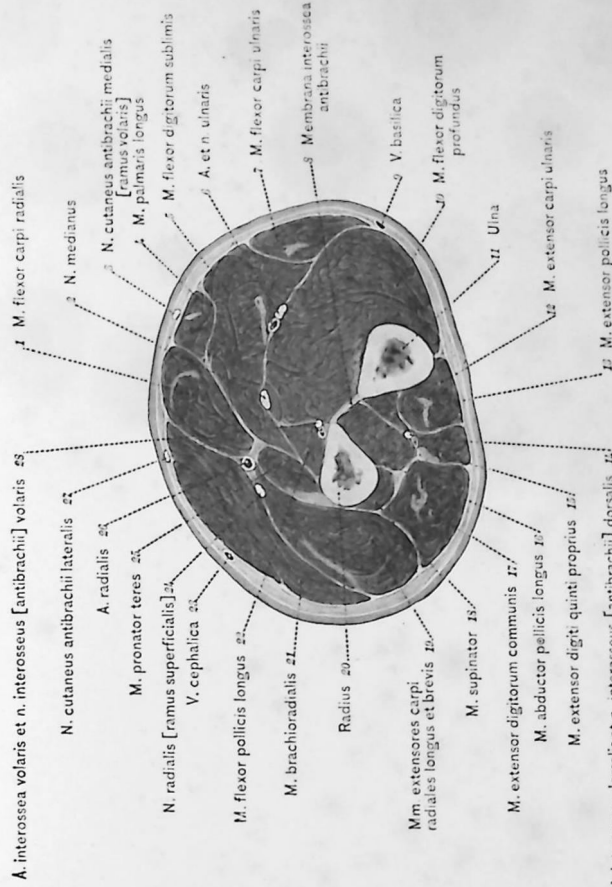
This section is about 27 mm. below the preceding section. Its level is indicated by line 65 in Key-figures IX, X. The extensor indicis proprius muscle (11) and the abductor pollicis longus muscle (14) first appear.



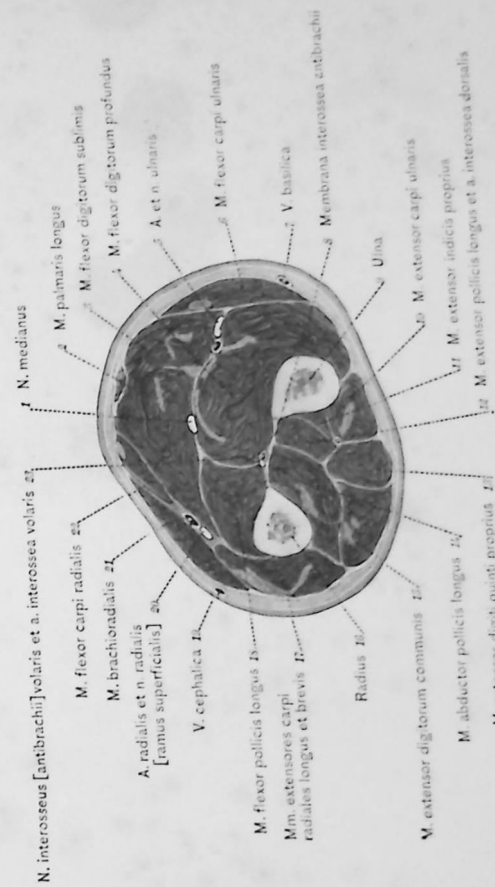
SECTION 62



SECTION 64



SECTION 63



SECTION 65

Sections 66, 67, 68, 69

Section 66

This section is about 25 mm. below the preceding section. Its level is indicated by line 66 in Key-figures IX, X. The extensor pollicis brevis muscle (16) first appears. The interosseous arteries (12, 14) are not shown below this level. The cephalic vein (20) and its component branches are not labeled below this level.

Section 67

This section is about 27 mm. below the preceding section. Its level is indicated by line 67 in Key-figures IX, X. The pronator quadratus muscle (6) first appears. The radial artery (22) becomes superficial.

Section 68

This section is about 25 mm. below the preceding section. Its level is indicated by line 68 in Key-figures IX, X. The ulnar nerve shown in the preceding section is here represented by the ramus volaris (4) and the ramus dorsalis (6).

Section 69

This section is about 25 mm. below the preceding section. Its level is indicated by line 69 in Key-figures IX, X. The expansion of the distal end of the radius (20) is apparent. The pronator quadratus muscle (7) and the brachioradialis muscle (18) both end in this section.

Sections 70, 71, 72, 73

Section 70

This section is about 23 mm. below the level of the preceding section. Its level is indicated by line 70 in Key-figures IX, X.

The section passes through the semilunar bone (6); through the upper portion of the cuneiform bone (12); through the scaphoid bone (21); through the styloid process (23) of the radius, and the articular cartilage (7). The pisiform bone lies entirely within the section. The articular cavity (10) is cut. The tendon sheaths, dorsally and ventrally, are shown. The flexor carpi ulnaris muscle (5) does not extend beyond this section.

Section 71

This section is about 20 mm. below the preceding section. Its level is indicated by line 71 in Key-figures IX, X.

The section passes through all of the distal carpal bones, viz.: the unciform (11), the os magnum (16), the trapezoid (18), the trapezium (22), and through the base of the first metacarpal bone (25). The anterior annular ligament (32) extends over the sulcus carpi, inclosing the flexor tendons (3, 14, 31) and the median nerve (1). The following muscles are cut for the first time: the palmaris brevis (4), abductor digiti quinti (7), opponens pollicis (27), and the abductor pollicis brevis (28). The following muscles do not extend beyond this section: the extensor carpi ulnaris (9), extensor carpi radialis brevis (17), extensor carpi radialis longus (19), and the flexor carpi ulnaris (29).

Section 72

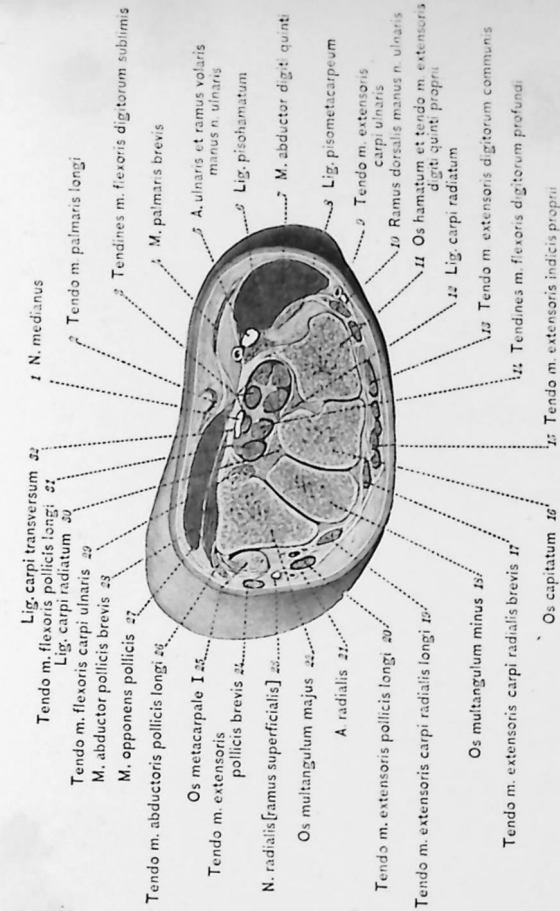
This section is about 24 mm. below the preceding section. Its level is indicated by line 72 in Key-figures IX, X.

The section passes through the five metacarpal bones. The following muscles are cut for the first time: the lumbricales (6), interosseus volaris (20), interosseus dorsalis (22), adductor pollicis (24), flexor pollicis brevis (31), and the flexor digiti quinti (8). The following muscles end in this section: the palmaris brevis (5), extensor pollicis brevis (26), opponens pollicis (28), and the abductor pollicis brevis (29). The sheaths of the tendons of the flexor pollicis longus muscle (30) and the flexor tendons of the fifth digit are continued into the following section. The median nerve (1) is divided into two branches. The ulnar nerve is likewise divided into two branches, shown at 4 and 9.

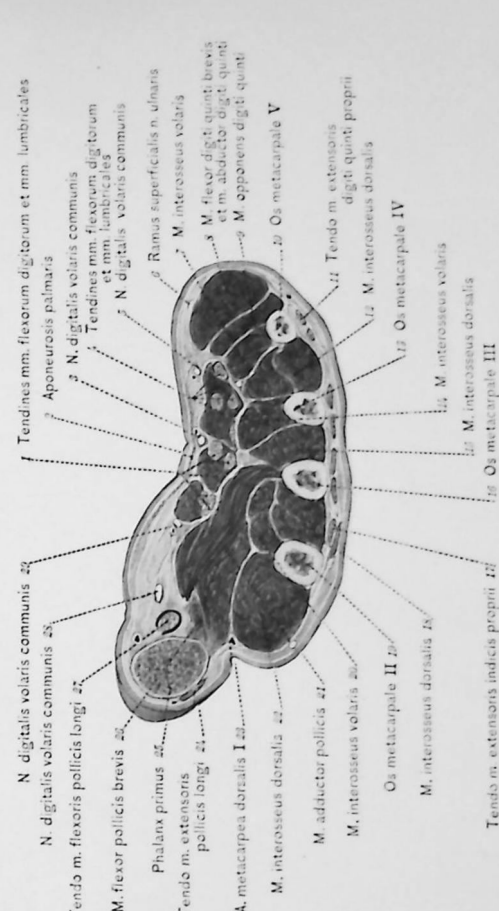
Section 73

This section is about 23 mm. below the preceding section. Its level is indicated by line 73 in Key-figures IX, X.

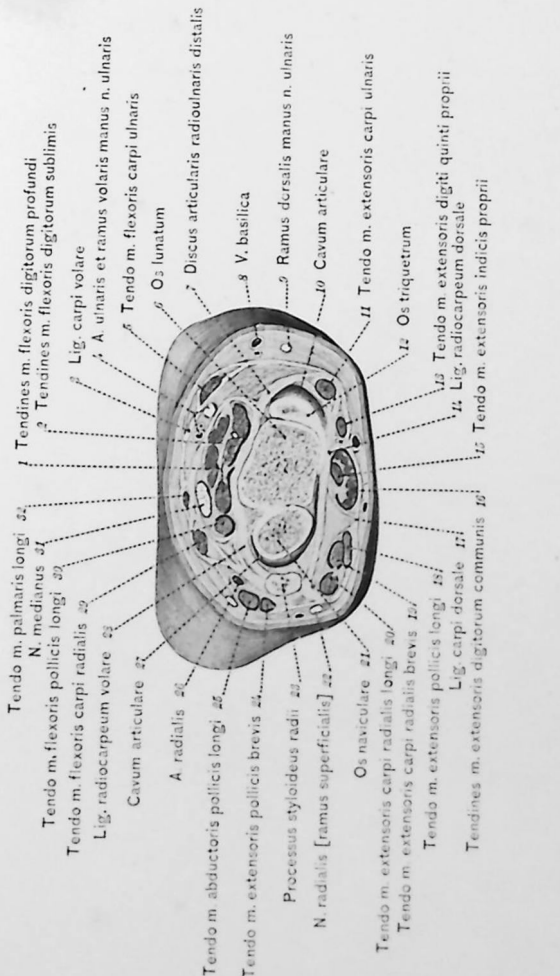
The section passes through the first phalanx of the thumb (25), and through the following metacarpals: II (19), III (16), IV (13), V (10). The following muscles end within the section: the flexor digiti quinti brevis (8), opponens digiti quinti (9), adductor pollicis (21), and the flexor pollicis brevis (26). The palmar fascia (2) is well shown.



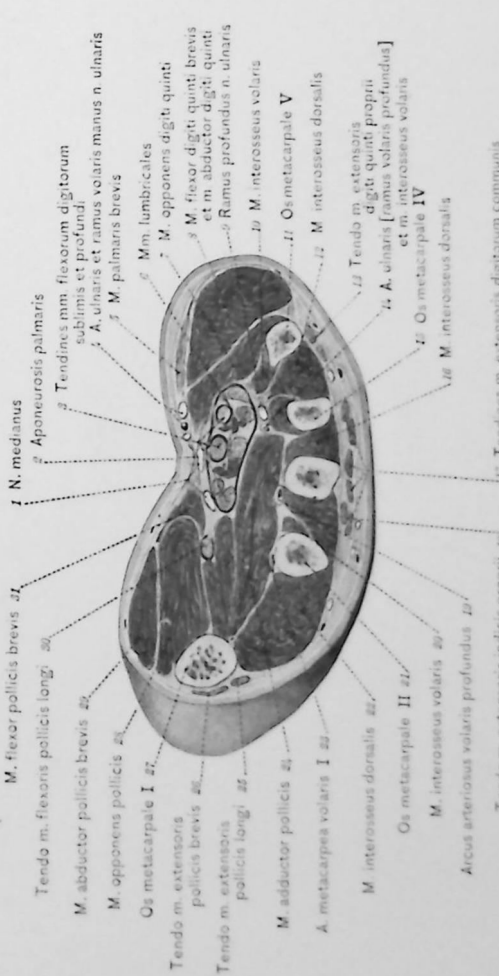
SECTION 71



SECTION 73



SECTION 70



SECTION 72

Sections 74 and 75

Section 74

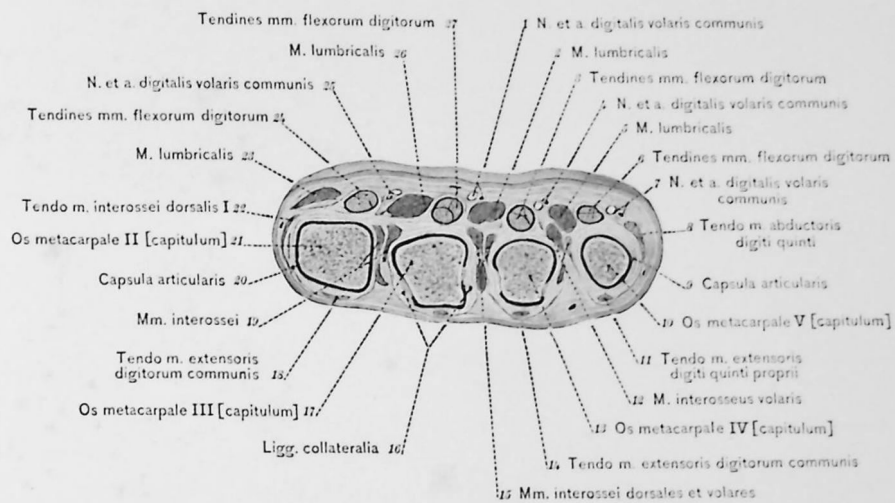
This section is about 21 mm. below the preceding section. Its level is indicated by line 74 in Key-figures IX, X.

The section passes through the heads of all the metacarpal bones, excepting the first one, which is not shown. All the articular capsules are shown, but only two (9, 20) are labeled. The sheaths of the flexor tendons are prominent.

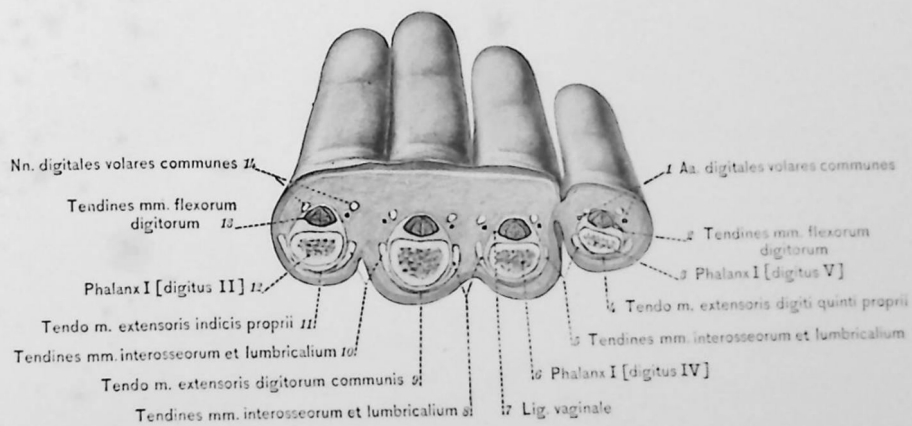
Section 75

This section is about 23 mm. below the preceding section. Its level is indicated by line 75 in Key-figures IX, X.

The section passes through the first phalanx of the II, III, IV, V digits, showing the aponeurotic expansions of the extensor tendons (5, 8, 10), into which the interosseous and lumbricales muscles are inserted.



SECTION 74



SECTION 75

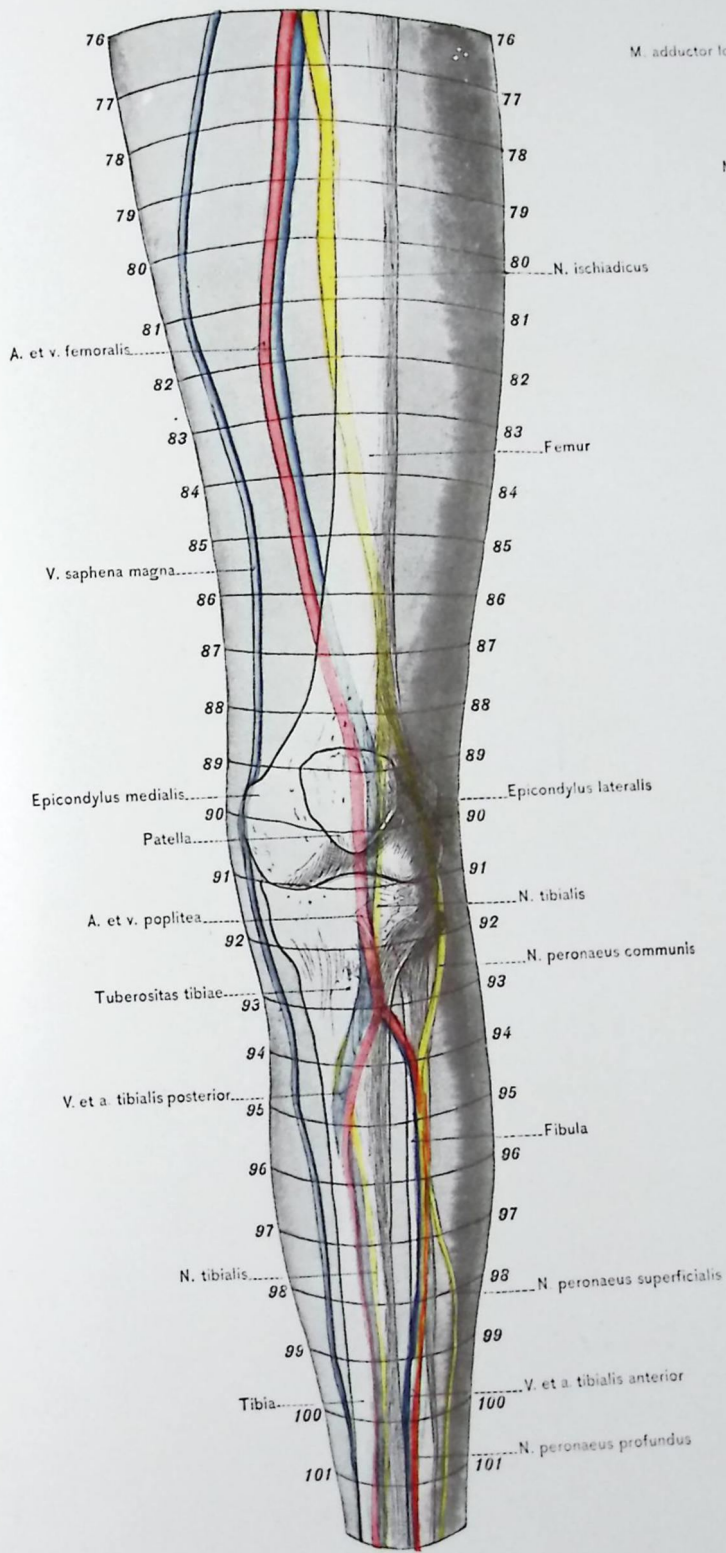
Key-figures XI and XII

Key-figure XI

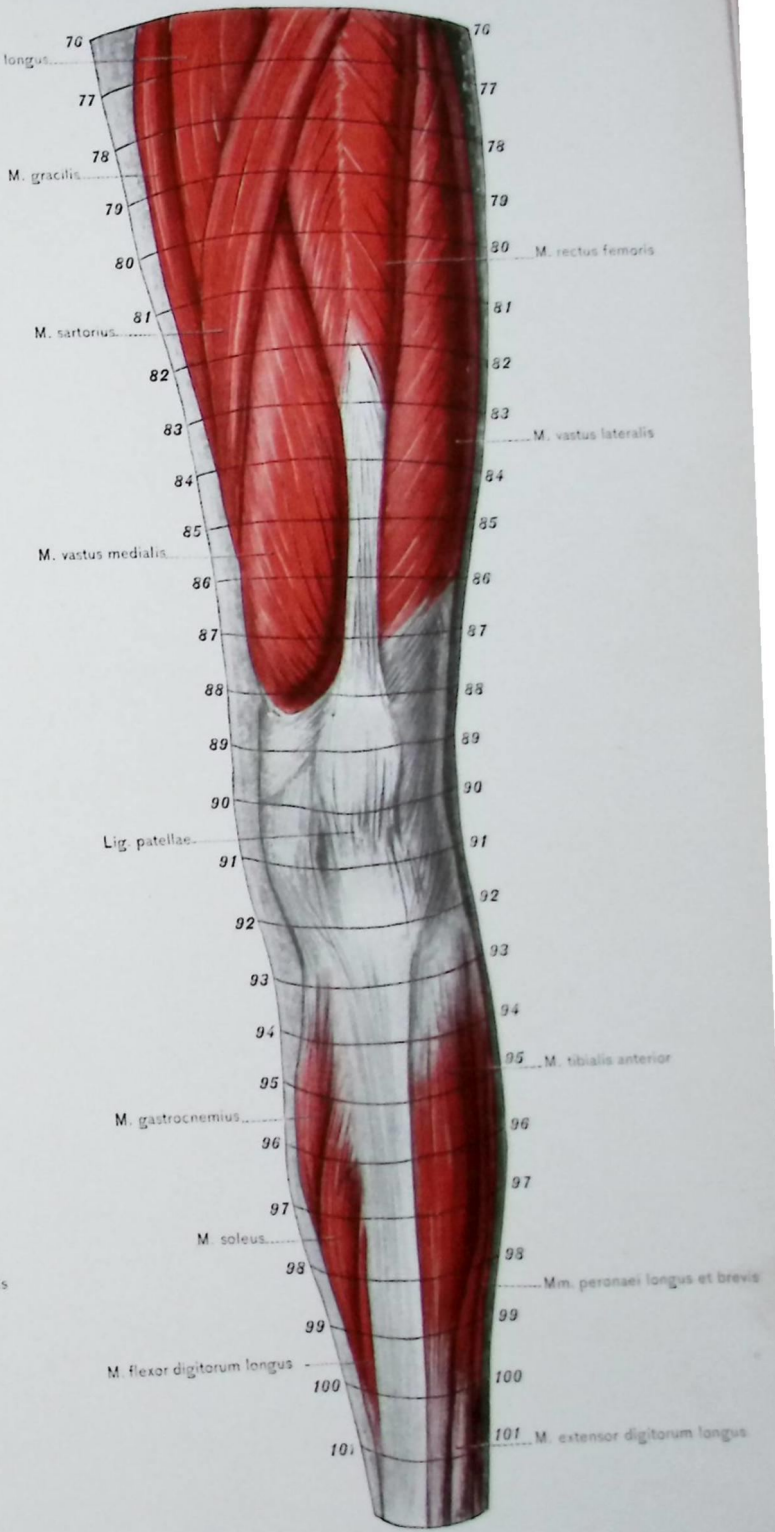
This Key-figure was made entirely by reconstruction. It represents a front view of the left lower limb, excepting the portions shown in connection with the trunk, and in Key-figure XIII. The bones, together with the principal arteries, veins, and nerves, are shown in conventional colors. The levels of the sections with reference to the various structures are indicated by the transverse lines 76-101.

Key-figure XII

This Key-figure was made entirely by reconstruction. It represents a front view of the muscles of the left lower limb, excepting the portions shown in connection with the trunk and in Key-figure XIV. The levels of the sections with reference to the principal muscles are indicated by the transverse lines 76-101.



KEY-FIGURE XI



KEY-FIGURE XII

Sections 76 and 77

Section 76

This section is the first of those in the series on the leg. Its level is practically that of Section 44, as a comparison with this section will show. While duplication is undesirable, it has been done, in this instance, for the sake of continuity. The level of this section is indicated by line 76 in Key-figures XI, XII. The section passes about 12–15 mm. below the lesser trochanter and through the upper portion of the gluteal tuberosity (19). The following muscles do not extend below the level of this section: the adductor minimus (17), the pectineus (23), and the iliopsoas (26). The tendinous insertion of the glutæus maximus (19) is shown.

Section 77

This section is about 25 mm. below the preceding section. Its level is indicated by line 77 in Key-figures XI, XII. The muscular portion of the biceps femoris (15) appears at this level. A valve of the profunda femoris vein (25) is shown.

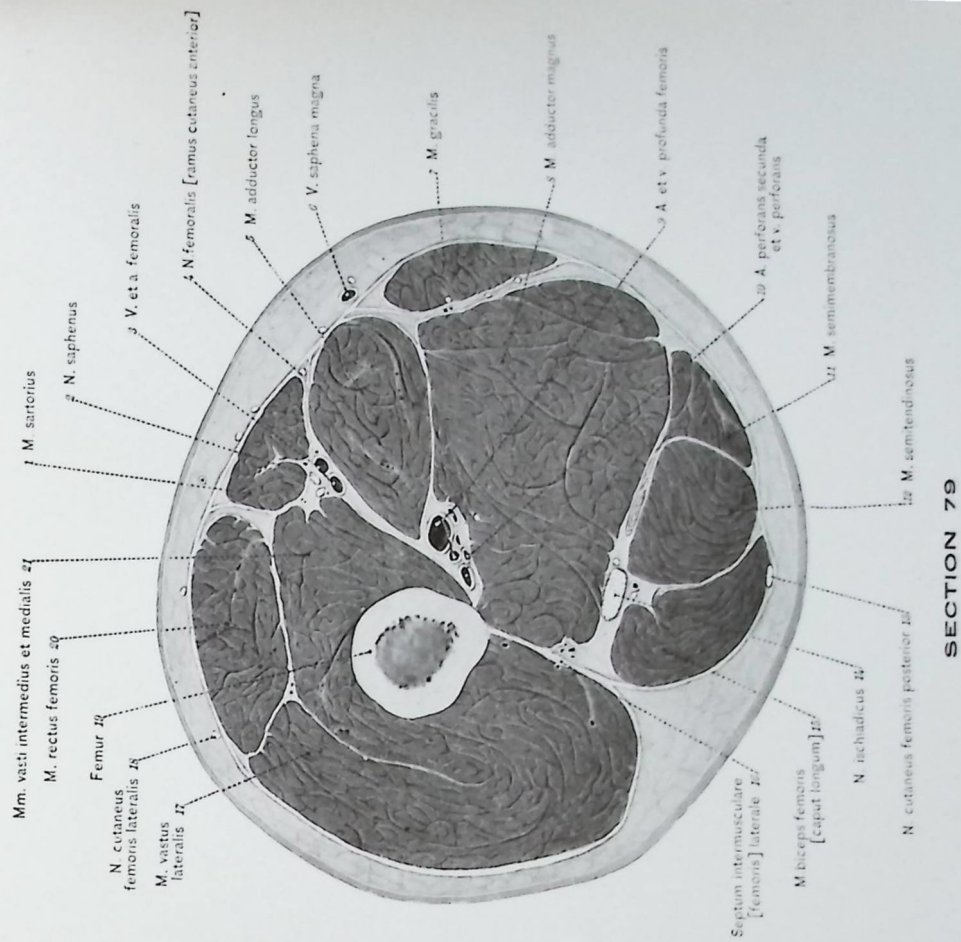
Sections 78 and 79

Section 78

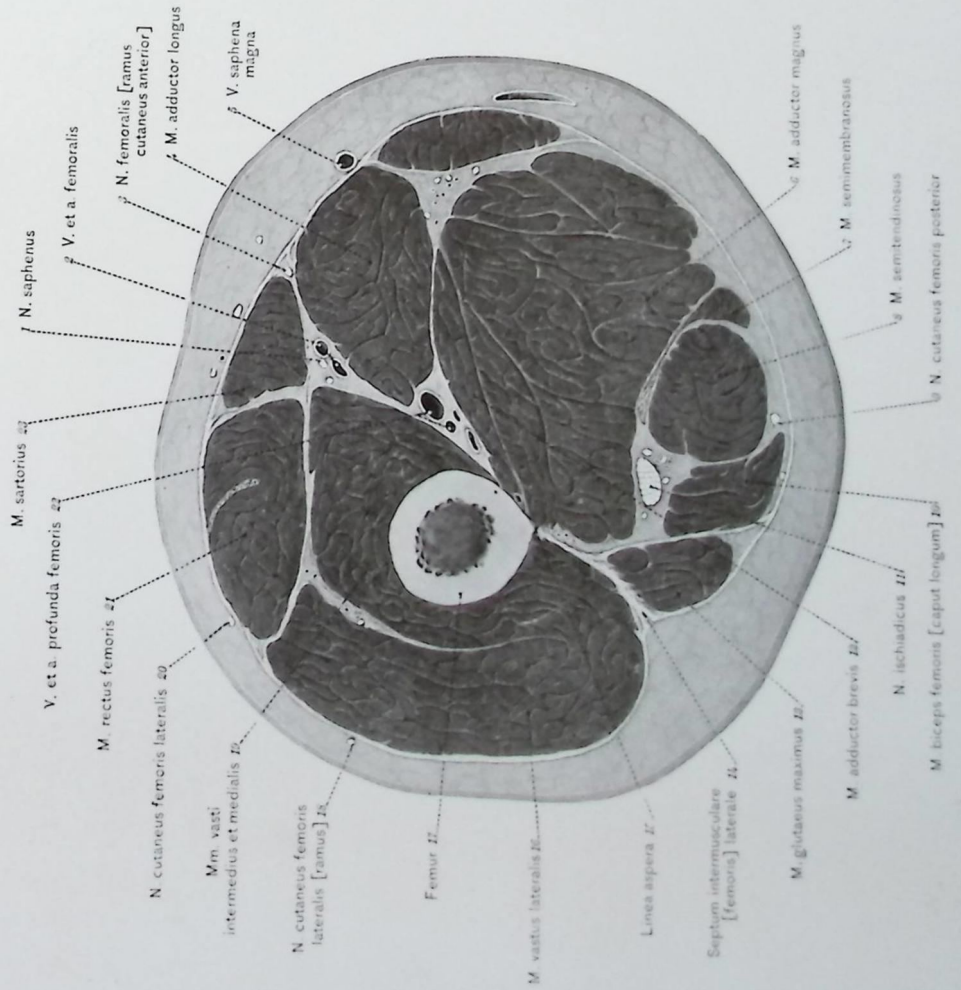
This section is about 24 mm. below the preceding section. Its level is indicated by line 78 in Key-figures XI, XII. The adductor brevis (12) and glutæus maximus (13) muscles do not extend beyond this section. There is as yet no line of division between the vastus intermedius and medialis (19). The second perforating artery (a. perforans secunda) arises within the section from the profunda artery (22).

Section 79

This section is about 27 mm. below the preceding section. Its level is indicated by line 79 in Key-figures XI, XII. The second perforating artery (10) arises from the profunda (9) in the lower portion of the preceding section.



SECTION 79



SECTION 78

Sections 80 and 81

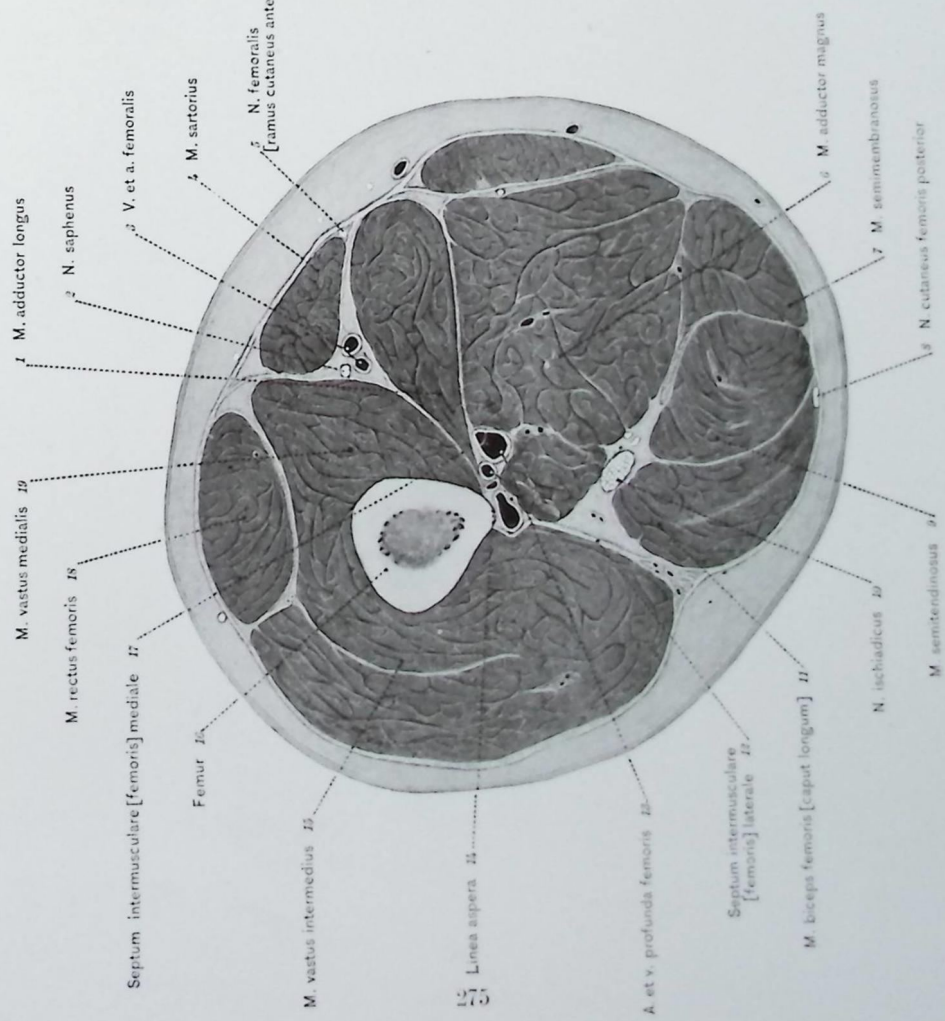
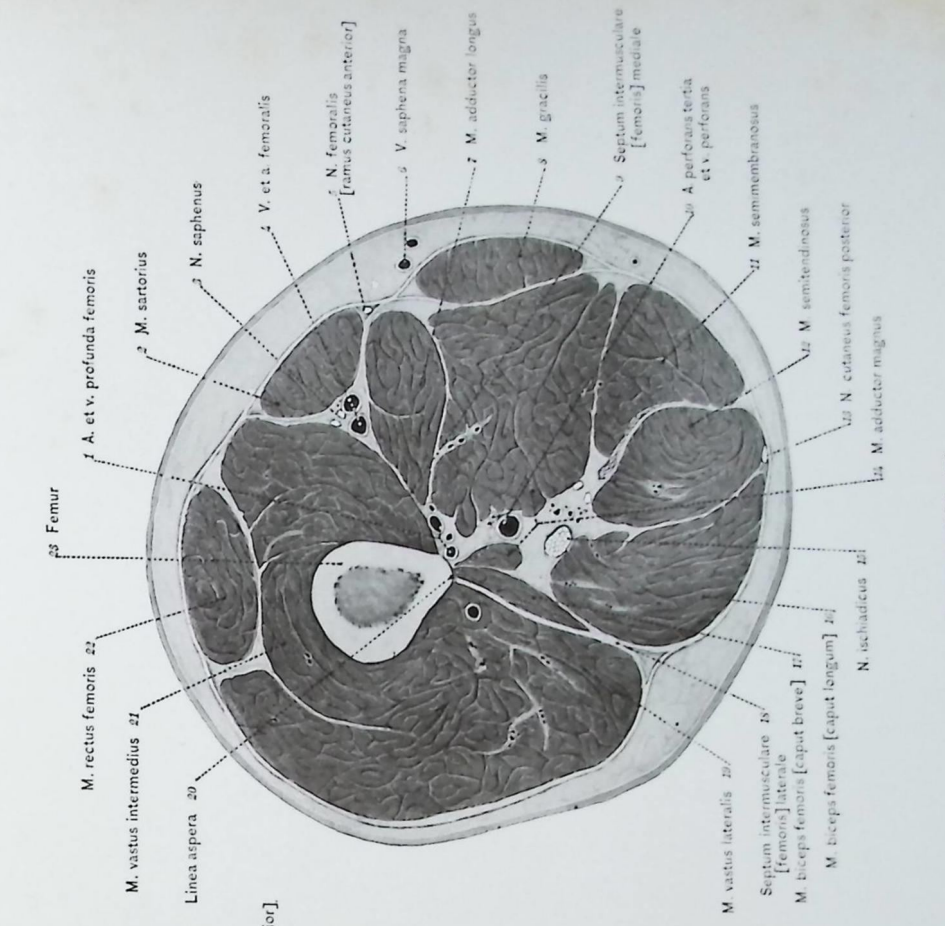
Section 80

This section is about 26 mm. below the preceding section. Its level is indicated by line 80 in Key-figures XI, XII. The third perforating artery arises from the profunda artery in this section. The deeper veins, in general, are large in this subject.

Section 81

This section is about 27 mm. below the level of the preceding section. Its level is indicated by line 81 in Key-figures XI, XII. The short head of the biceps femoris muscle (17) is first shown in this section, likewise the third perforating artery (10).

It will be noted that there is a large vein (10) which accompanies the perforans tertia. In this and the following section, where it accompanies the perforans tertia, it is labeled v. perforans. In Sections 83-88 it has been labeled v. varians. This vein arises from the popliteal vein in Section 88, and accompanies the great sciatic nerve. In Section 82 it unites with the third perforating vein, which in turn unites with the femoral in Section 80. This variation is one frequently found. In three cases recently observed, in which this condition has been found, the v. saphena parva was exceedingly small.



SECTION BI

SECTION 80

23 Femur
 1 A. et v. profunda femoris
 2 M. sartorius
 3 N. saphenus
 4 V. et a. femoralis
 5 N. femoralis [ramus cutaneus anterior]
 6 V. saphena magna
 7 M. adductor longus
 8 M. gracilis
 9 Septum intermusculare [femoris] mediale
 10 A. perforans tertia et v. perforans
 11 M. semimembranosus
 12 M. semitendinosus
 13 N. cutaneus femoris posterior
 14 M. adductor magnus
 15 N. ischiadicus
 16 M. biceps femoris [caput longum]
 17 Septum intermusculare [femoris] laterale
 18 M. biceps femoris [caput breve]
 19 M. vastus lateralis
 20 Linea aspera
 21 M. vastus intermedius
 22 M. rectus femoris
 23 Femur

1 M. adductor longus
 2 N. saphenus
 3 V. et a. femoralis
 4 M. sartorius
 5 N. femoralis [ramus cutaneus anterior]
 6 M. adductor magnus
 7 M. semimembranosus
 8 N. cutaneus femoris posterior
 9 M. semitendinosus
 10 N. ischiadicus
 11 M. biceps femoris [caput longum]
 12 Septum intermusculare [femoris] laterale
 13 A. et v. profunda femoris
 14 Linea aspera
 15 M. vastus intermedius
 16 Septum intermusculare [femoris] mediale
 17 M. rectus femoris
 18 M. vastus medialis
 19 M. vastus medialis
 20 M. adductor longus

Sections 82 and 83

Section 82

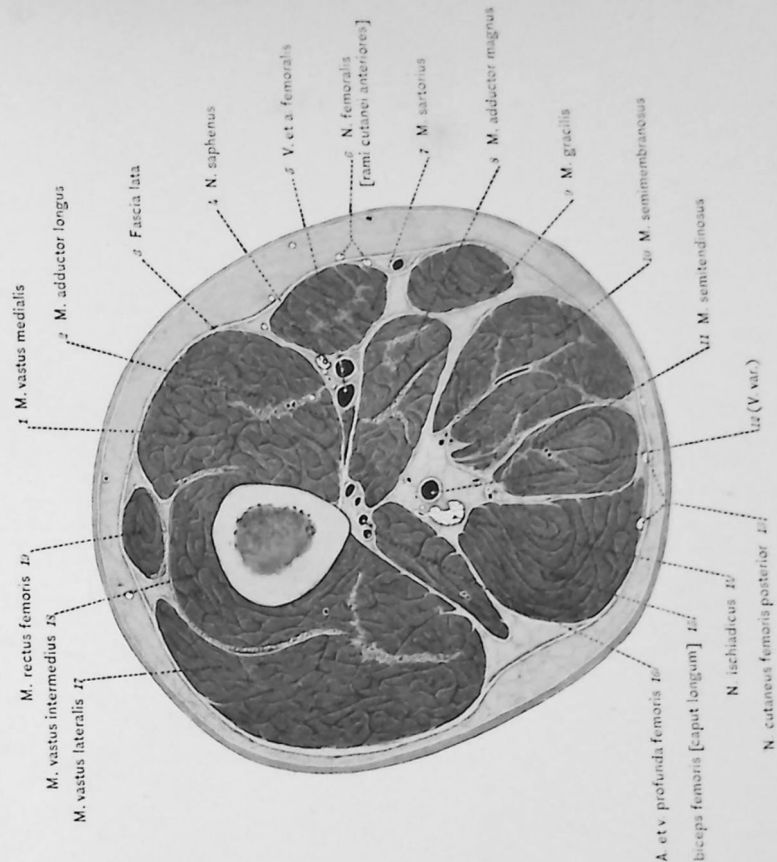
This section is about 25 mm. below the preceding section. Its level is indicated by line 82 in Key-figures XI, XII.

Just behind the saphenous nerve (3) are two large blood vessels, which are not labeled; the internal is the femoral vein and the external the femoral artery. These structures lie in the groove bounded by the vastus internus (1), the adductor longus (5), and the sartorius (4). The long or internal saphenous vein lies between the sartorius and gracilis muscles, just outside the fascia.

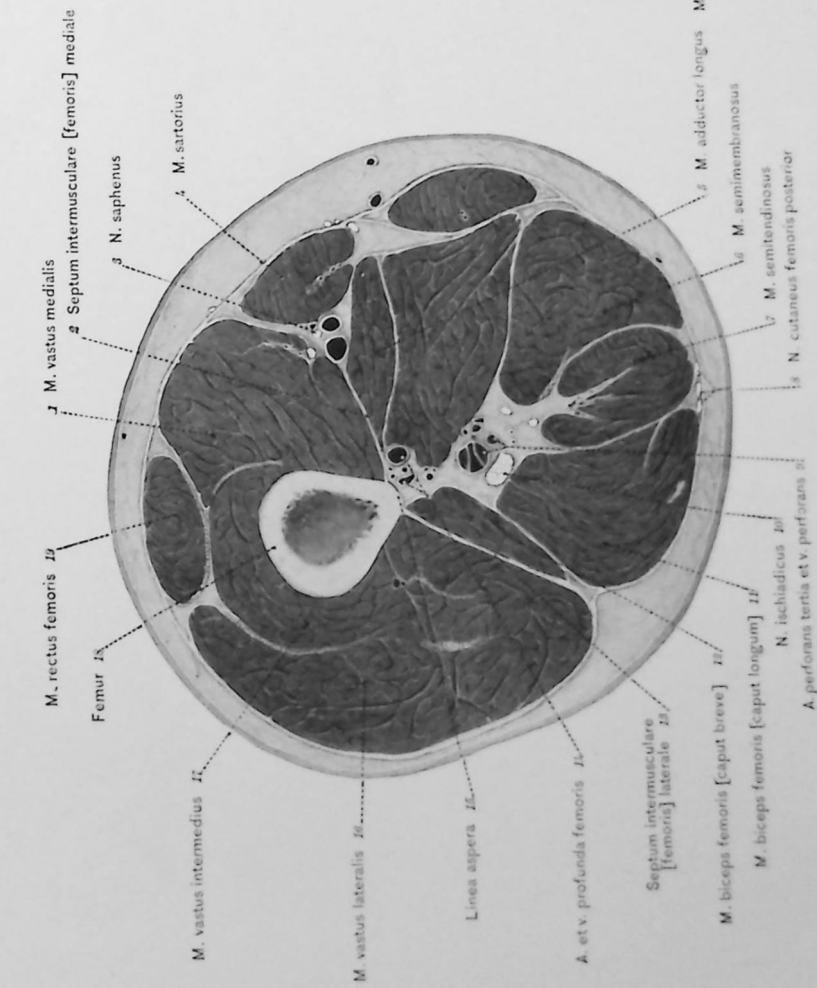
Section 83

This section is about 25 mm. below the preceding section. Its level is indicated by line 83 in Key-figures XI, XII.

The adductor longus muscle (2) does not extend below this section. Hunter's canal begins about the middle of this section, and extends to the upper part of Section 85, where the hiatus is shown. It should be recalled that the entrance to Hunter's canal is defined by a tendinous plate (clearly shown in Section 84), which extends between the anterior margin of the adductor magnus muscle to the medial surface of the vastus internus muscle.



SECTION 83



SECTION 82

Sections 84 and 85

Section 84

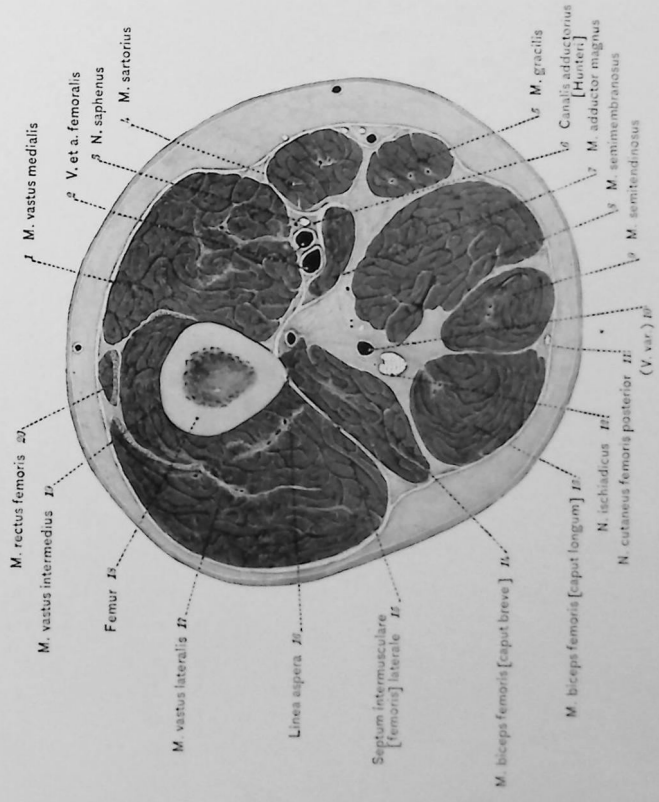
This section is about 26 mm. below the preceding section. Its level is indicated by line 84 in Key-figures XI, XII.

The rectus femoris muscle (20) is becoming tendinous at this level. The femoral vessels (2) are seen in Hunter's canal. The strong tendinous plate going over to the vastus medialis muscle from the anterior margin of the adductor magnus muscle is well defined.

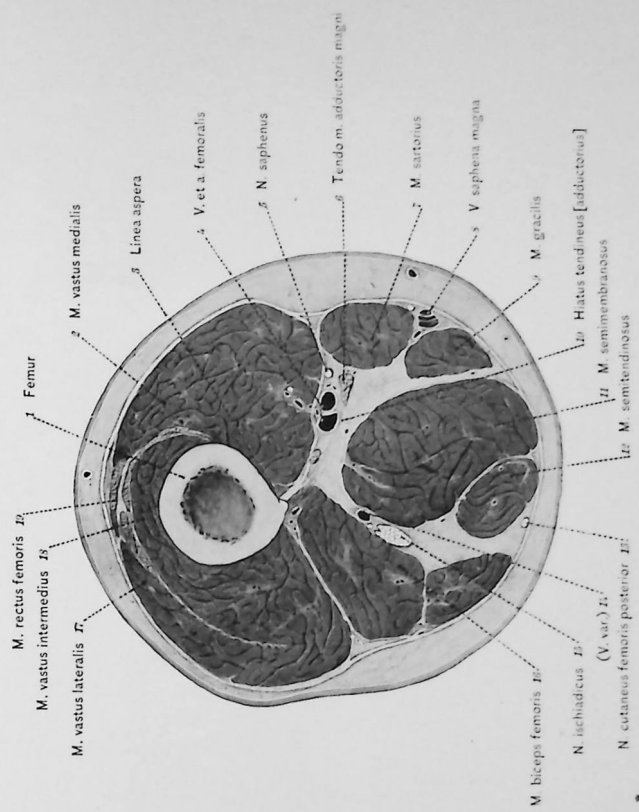
Section 85

This section is about 27 mm. below the preceding section. Its level is indicated by line 85 in Key-figures XI, XII.

The subcrureus muscle originates in this section. The two heads of the biceps (16) have fused. The femoral vessels (4) pass through the hiatus of Hunter's canal, and become the popliteal vessels in this section. The popliteal artery gives rise to the anastomotica magna artery within the section.



SECTION 84



SECTION 85

Sections 86 and 87

Section 86

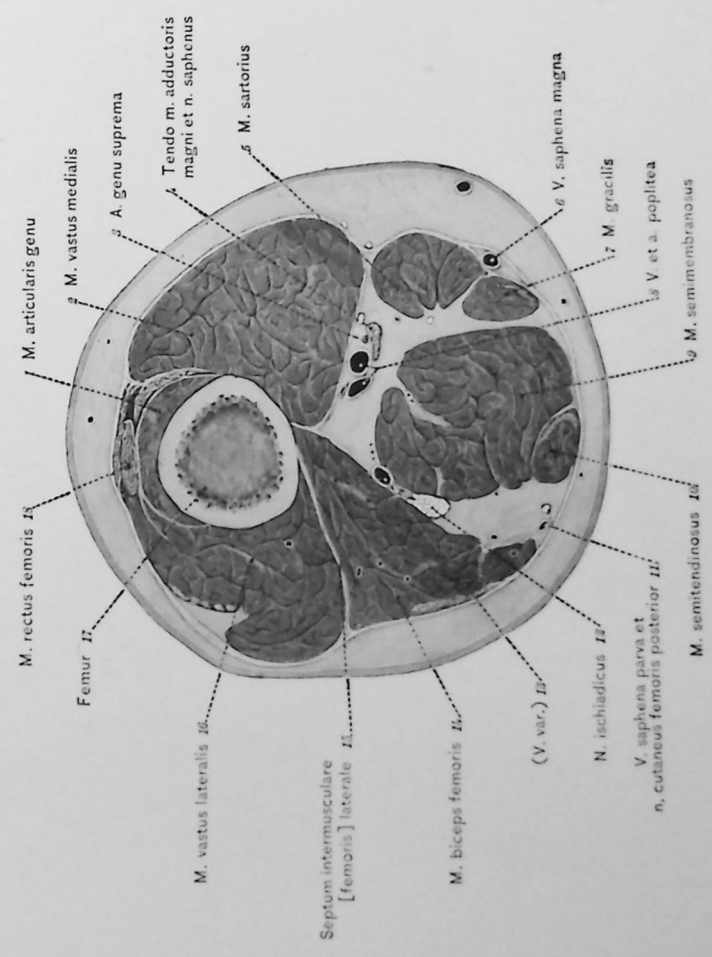
This section is about 25 mm. below the preceding section. Its level is indicated by line 86 in Key-figures XI, XII.

The tendon of the quadriceps femoris muscle is shown, but is not labeled in this section. The index line 4 passes over the saphenous nerve.

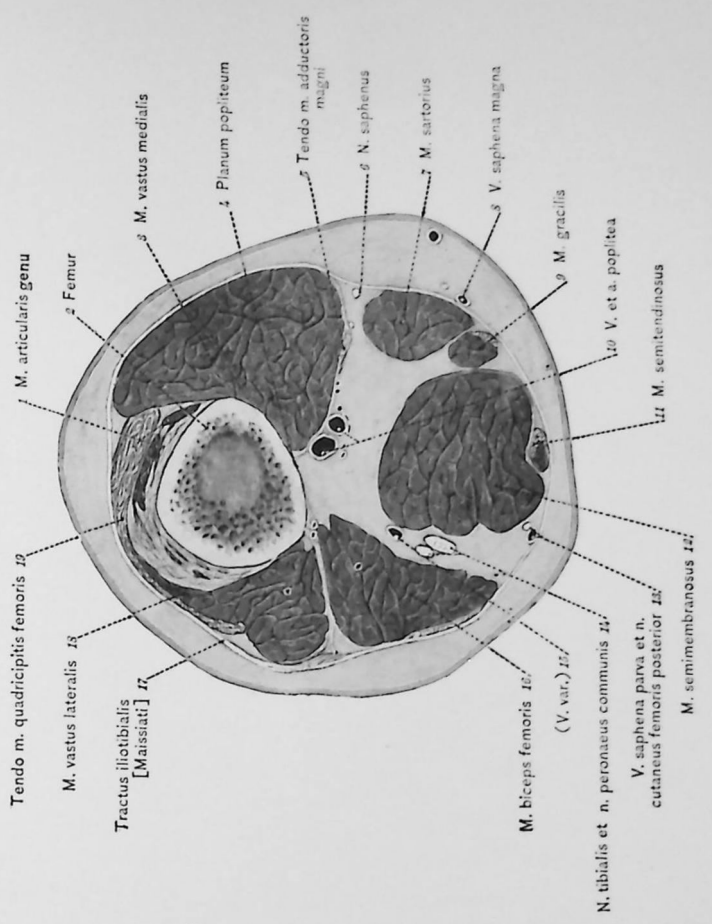
Section 87

This section is about 26 mm. below the preceding section. Its level is indicated by line 87 in Key-figures XI, XII.

The superior, internal, and external articular arteries take origin in the section. Two divisions are now recognizable in the great sciatic nerve (n. ischiadicus), viz., the internal (14) and external (14) popliteal nerves.



SECTION 86



SECTION 87

Sections 88, 89, 90, 91

Section 88

This section is about 25 mm. below the preceding section. Its level is indicated by line 88 in Key-figures XI, XII.

The section passes through the femur about 15 mm. above the base of the patella. The tendinous fibers of the suberureus muscle extend into the upper surface of this section. In the lower portion of this section a large vein branches from the popliteal vein. It follows the course of the internal popliteal nerve through Sections 87, 86, 85, 84, 83. In Section 82 it shows a valve, and lies by the side of the third perforating artery. It continues upward, gradually assuming a deeper position than the nerve, and finally, in Section 80, unites with the profunda femoris vein. In these sections it has been designated as v. varians.

Section 89

This section is about 24 mm. below the level of the preceding section. Its level is indicated by line 89 in Key-figures XI, XII.

The section passes just above the epicondyles of the femur, through the patella (1) about 1 cm. below its base. The mesial head of the gastrocnemius muscle (3) and the plantar muscle (18) appear for the first time. The biceps femoris muscle, crossed by index line 18, is not labeled. The sural branch (17) of the external popliteal nerve is first shown. The changed relations of the popliteal vein and artery, and the tibial and peroneal nerves, should be noted in Section 88, 89.

Section 90

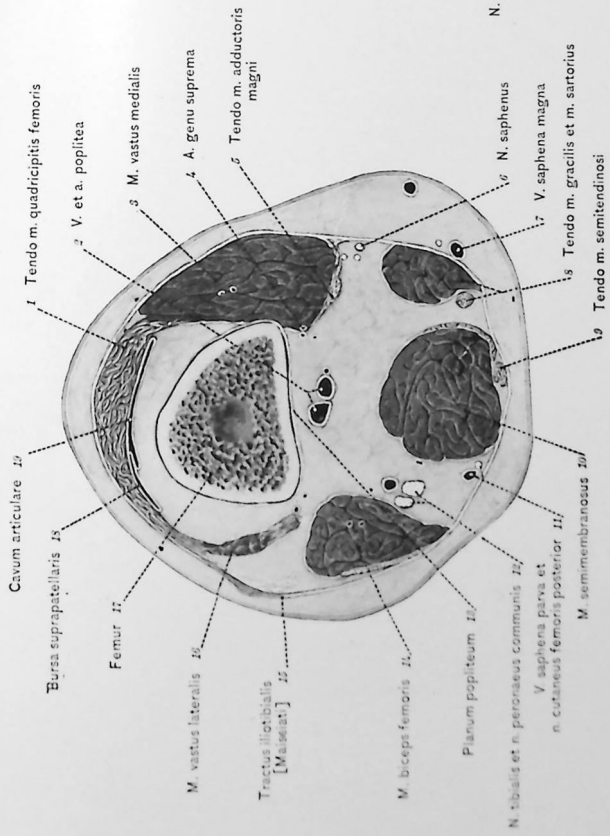
This section is about 27 mm. below the preceding section. Its level is indicated by line 90 in Key-figures XI, XII.

This section passes through the lower third of the patella (30) and through the middle portion of the epicondyles of the femur (5, 26). The prepatellar bursa (1) and the articular cavity of the knee-joint (3, 22) are shown. An alar ligament (plica alaris) is shown at 2 between the patella and femur. The lateral head of the gastrocnemius muscle (23) is first cut by this section. The n. communicans tibialis (19), which arises from the tibial nerve (18), is first shown.

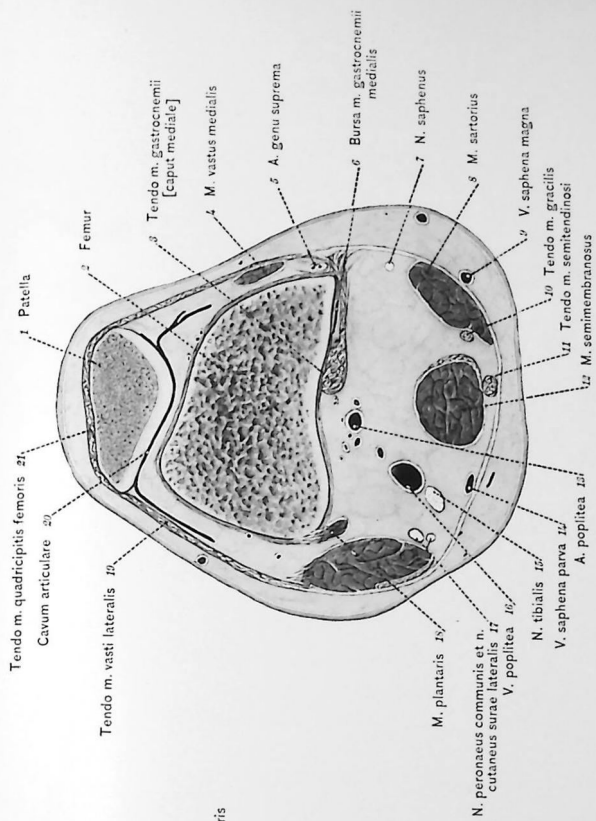
Section 91

This section is about 24 mm. below the preceding section. Its level is indicated by line 91 in Key-figures XI, XII.

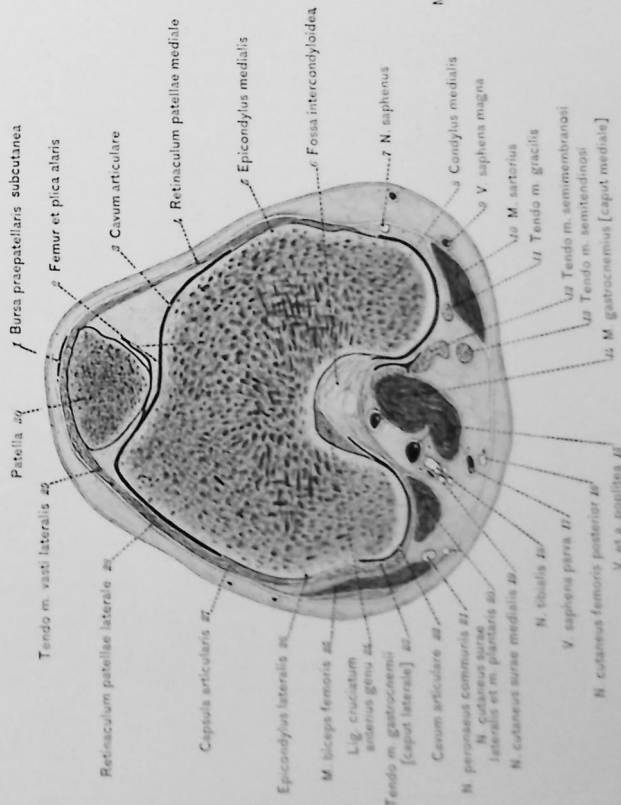
The section passes through the lower margins of the condyles of the femur, the distal portions of which have been removed in order to show the articular surfaces of the tibia (4, 29). The upper end of the tibia (1) is cut. The mesial meniscus (6) and lateral meniscus (26) are both shown, likewise the anterior (30) and posterior (7) crucial ligaments. The patellar ligament (31) and the iliotibial band (27) are shown. With the exception of the sartorius, the femoral muscles have become tendinous while the crural muscles are beginning to enlarge.



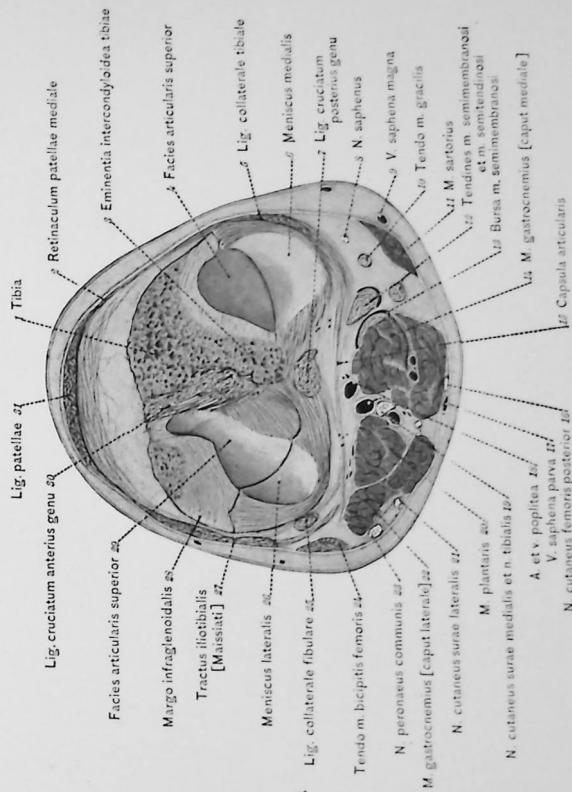
SECTION 88



SECTION 89



SECTION 90



SECTION 91

Sections 92, 93, 94, 95

Section 92

This section is about 27 mm. below the preceding section. Its level is indicated by line 92 in Key-figures XI, XII.

The section passes through the tibia (1) at the lower margins of the condyles (2, 18) and the upper margin of the tuberosity. It also passes through the head of the fibula (16). A considerable portion of the patellar ligament (19) is still shown. The tendinous insertion of the semimembranosus muscle (4) is seen on the posteromesial surface of the tibia (1). The tendons of the gracilis (3), sartorius (5), and semitendinosus (7) muscles are converging to their insertion, which is shown in the next section at 3. The soleus muscle (15) appears. The two heads of the gastrocnemius (11) are in close proximity. The division of the peronæus nerve (15) into a superficial and deep branch occurs in this section.

Section 93

This section is about 25 mm. below the preceding section. Its level is indicated by line 93 in Key-figures XI, XII.

The section passes through the tibia at the level of the lower portion of its tuberosity (1), and through the fibula (15) a little below its head. These bones are separated by a considerable interval; between them the interosseous membrane (20) is shown. The following muscles are cut for the first time: the peronæus longus (17), tibialis posterior (18), tibialis anterior (21), extensor digitorum longus (19), and the extensor hallucis longus (19). The gracilis, semitendinosus, and the sartorius insert in this section. The anterior tibial artery begins in this section, and is shown at 15 in the following section. The branches (16) of the peronæus nerve are first shown in this section.

Section 94

This section is about 24 mm. below the preceding section. Its level is indicated by line 94 in Key-figures XI, XII.

The peronæus brevis muscle (16) begins in the section above, but it is intimately fused at this level with the peronæus longus (16). The soleus muscle (11) is rapidly increasing in size, while the gastrocnemius (8, 11) is decreasing. The anterior tibial vessels (15) are first seen in this section, as are also the peroneal vessels (12).

Section 95

This section is about 25 mm. below the preceding section. Its level is indicated by line 95 in Key-figures XI, XII. The popliteus muscle (3) inserts on the postero-mesial surface of the tibia (2).

Sections 96, 97, 98, 99

Section 96

This section is about 25 mm. below the preceding section. Its level is indicated by line 96 in Key-figures XI, XII.

The lateral head of the gastrocnemius (12) loses its muscular character in this section.

Section 97

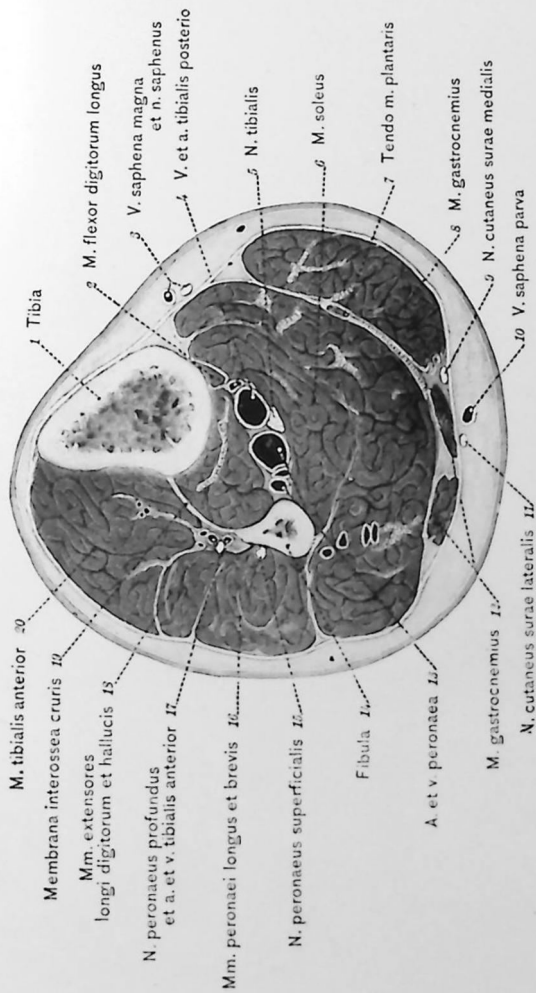
This section is about 25 mm. below the preceding section. Its level is indicated by line 97 in Key-figures XI, XII. The flexor hallucis longus muscle (13) shows for the first time.

Section 98

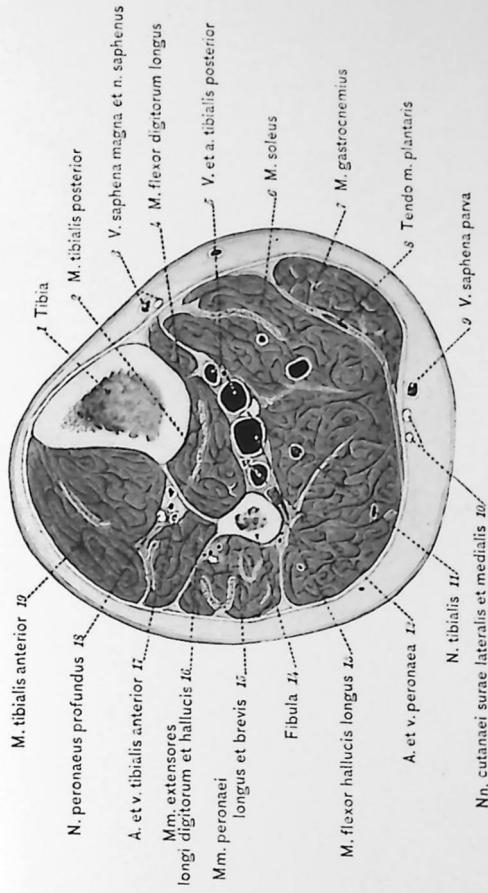
This section is about 25 mm. below the preceding section. Its level is indicated by line 98 in Key-figures XI, XII.

Section 99

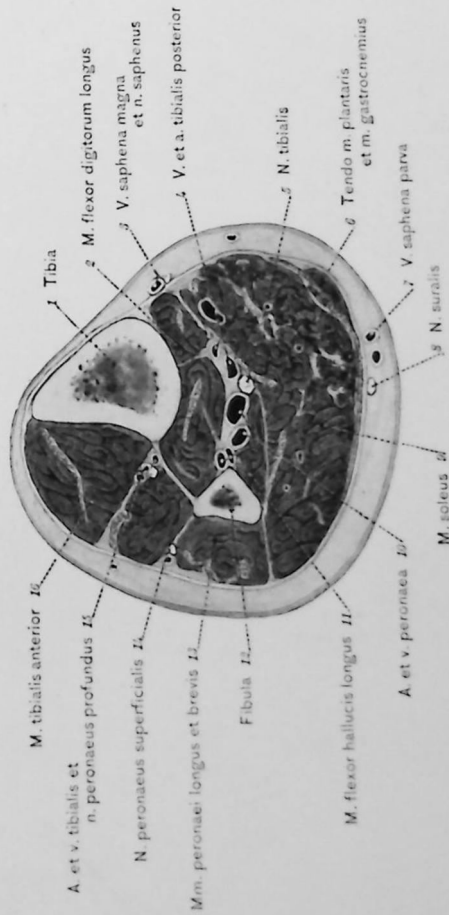
This section is about 24 mm. below the preceding section. Its level is indicated by line 99 in Key-figures XI, XII. The tendons of the plantar (7) and the gastrocnemius (8) muscles are in close proximity.



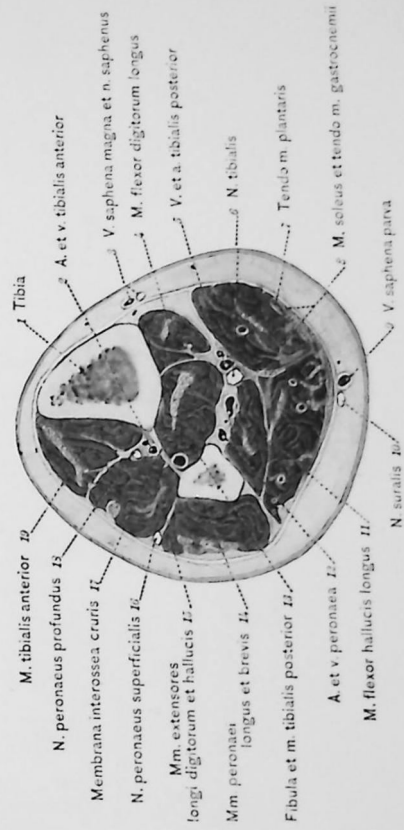
SECTION 96



SECTION 97



SECTION 98



SECTION 99

Sections 100, 101, 102, 103

Section 100

This section is about 26 mm. below the preceding section. Its level is indicated by line 100 in Key-figures XI, XII. The extensor digitorum longus muscle (17) and the extensor hallucis longus muscle (19) are here separated.

Section 101

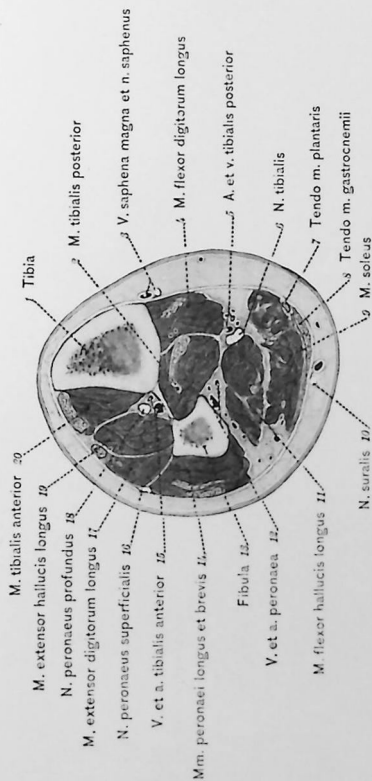
This section is about 27 mm. below the preceding section. Its level is indicated by line 101 in Key-figures XI, XII. In this section the tendons of the gastrocnemius (9) and soleus (10) form the tendon of Achilles which appears in the next section.

Section 102

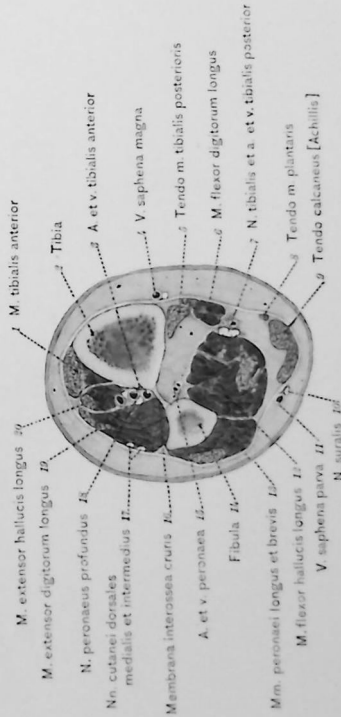
This section is about 25 mm. below the level of the preceding section. Its position is indicated by line 102 in Key-figures XIII, XIV. It should be recalled that this and the remaining sections of the leg and foot are from another subject.

Section 103

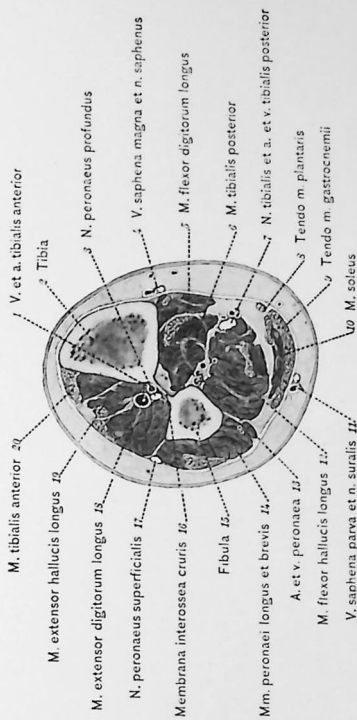
This section is about 25 mm. below the preceding section. Its level is indicated by line 103 in Key-figures XIII, XIV. The division between the peronæus brevis muscle (13) and the peronæus longus muscle (14) is here shown for the first time.



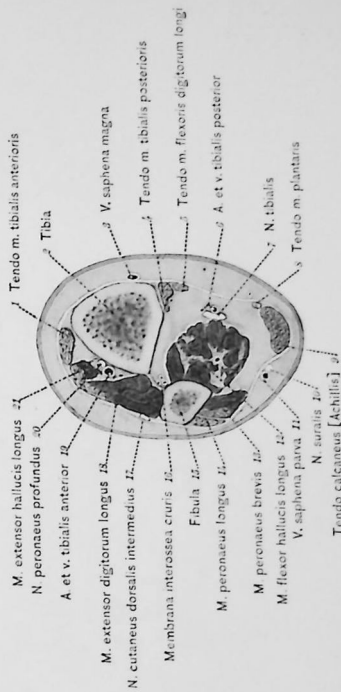
SECTION 100



SECTION 102



SECTION 101



SECTION 103

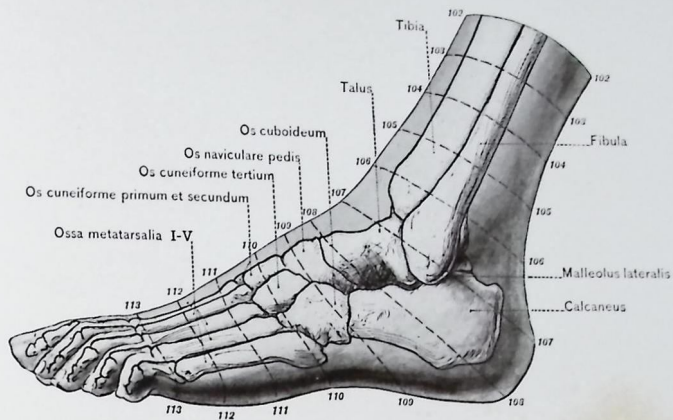
Key-figures XIII and XIV

Key-figure XIII

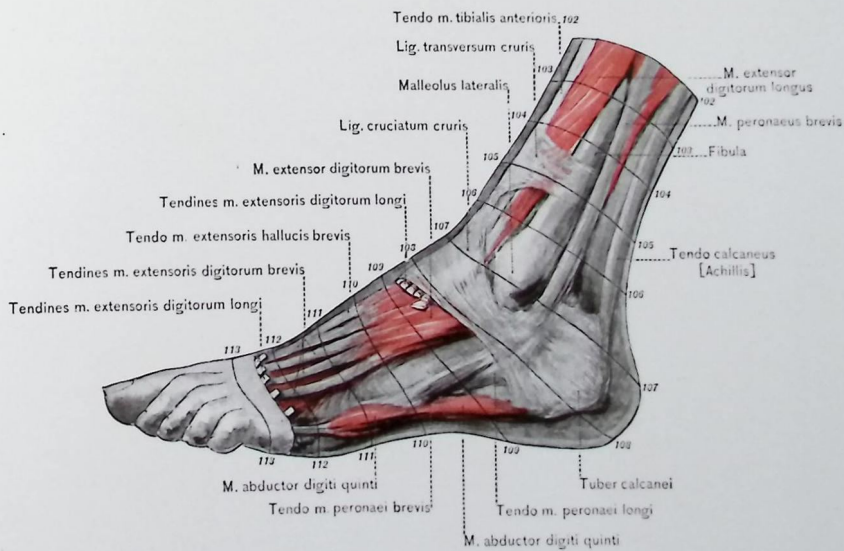
This Key-figure was made entirely by reconstruction. It represents a side view of a portion of the leg and the entire foot, showing the position of the various bones. The levels of the sections with reference to the various bones are indicated by the lines 102-113

Key-figure XIV

This Key-figure was made entirely by reconstruction. It represents a side view of a portion of the leg and the entire foot, showing the principal ligaments and muscles. The tendons of the extensor digitorum longus muscle have been removed in order to show the extensor digitorum brevis and extensor hallucis brevis muscles. The levels of the sections with reference to the various muscles and tendons are indicated by the transverse lines 102-113.



KEY-FIGURE XIII



KEY-FIGURE XIV

Sections 104, 105, 106, 107

Section 104

This section is about 25 mm. below the preceding section. Its level is indicated by line 104 in Key-figures XIII, XIV.

The interosseous membrane between the tibia (2) and fibula (14) is last seen in this section. The sheaths (vaginæ) of the tendons of the following muscles begin: the anterior group, including the tibialis anterior (1), the extensor digitorum longus (17), and the extensor hallucis longus (20); in addition, the sheaths of the tibialis posterior (4), the peronæus brevis (12), and peronæus longus (13) muscles begin in this section.

Section 105

This section is about 25 mm. below the preceding section. Its level is indicated by line 105 in Key-figures XIII, XIV.

The fibula (14) is considerably enlarged at this level. It lies closer to the tibia (3), the intervening space being filled with fibrous connective tissue.

Section 106

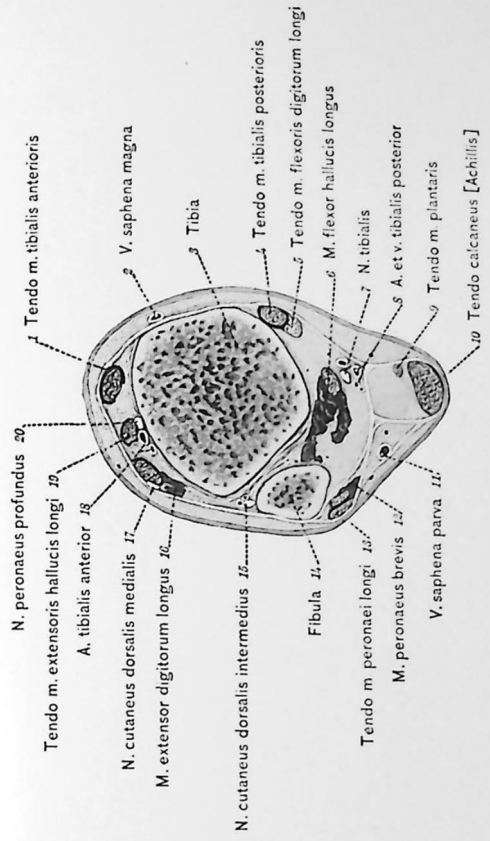
This section is about 25 mm. below the preceding section. Its level is indicated by line 106 in Key-figures XIII, XIV.

The section passes through the tibia (3) at a level slightly above the mesial malleolus, and through the fibula slightly above the lateral malleolus. A large part of the articular surface of the astragalus lies in the lower portion of this section. The external saphenous vein (12) is formed at about this level.

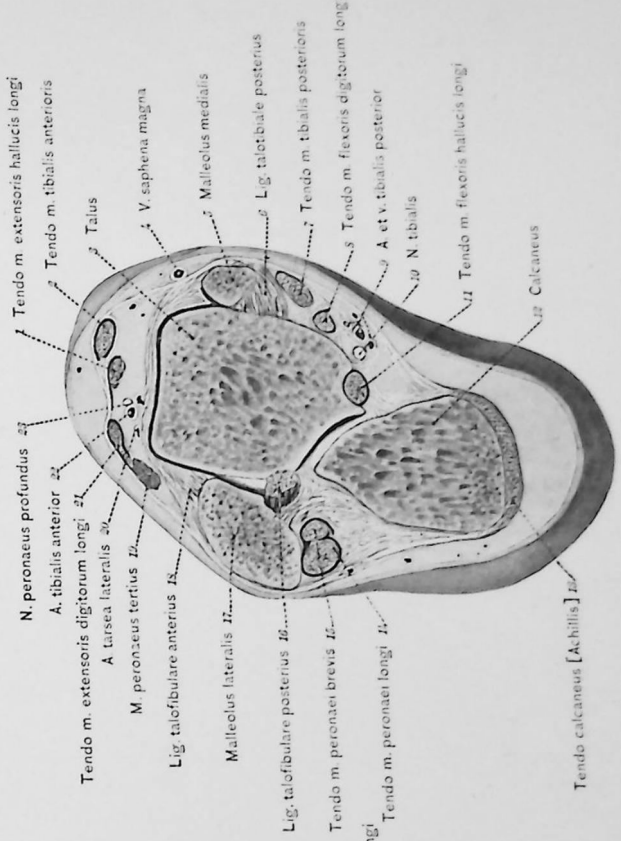
Section 107

This section is about 25 mm. anteriorly and 27 mm. posteriorly below the preceding section. Its level is indicated by line 107 in Key-figures XIII, XIV.

The tibia is cut through the mesial malleolus (5), while the fibula is cut through the lateral malleolus (17). The tendon of Achilles (13) inserts partly in the section above, but largely in this section. The capsule of the joint is well defined.

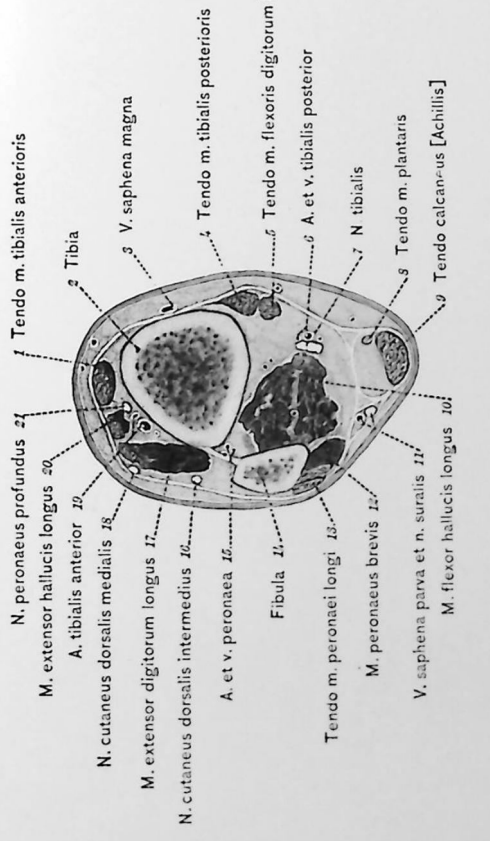


SECTION 104

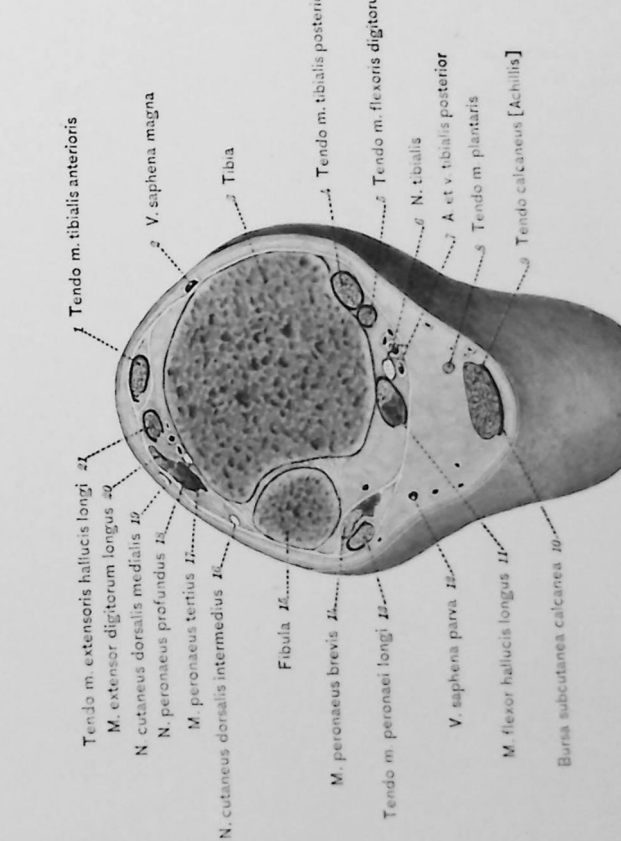


SECTION 105

SECTION 107



SECTION 106



SECTION 106

Sections 108, 109, 110, 111

Section 108

This section is about 25 mm. on the dorsal surface and 30 mm. on the plantar surface below the preceding section. Its level is indicated by line 108 in Key-figures XIII, XIV.

The section passes through the lower portion of the astragalus (4), and slightly below the middle portion of the os calcis or calcaneum (15). The greater portion of the scaphoid (os naviculare) and a small portion of the cuboid lie in this section. The processus trochlearis (17) of the calcaneum appears, and just behind this process the tendon of the peronæus longus is shown. The mesial process of the tuberosity of the calcaneum (13) shows the origin of the abductor hallucis muscle (10). The following muscles first appear: the flexor accessorius (quadratus plantæ) (12), extensor digitorum brevis (19), and the extensor hallucis brevis (21). The posterior tibial artery divides in the section above, giving rise to the medial plantar artery (9) and the lateral plantar artery (11). In like manner the posterior tibial nerve has divided into branches (9, 11) which correspond to the arteries.

Section 109

This section is about 15 mm. on the dorsal and 27 mm. on the plantar surface below the preceding section. Its level is indicated by line 109 in Key-figures XIII, XIV.

The section passes through the lower third of the scaphoid (4), the upper portion of the cuboid (21), and the lower portion of the calcaneum (19). Parts of the three cuneiform bones and a part of the tuberosity of the fifth metatarsal lie in this section. The long plantar ligament (17) is cut obliquely. The following muscles are cut for the first time: the flexor hallucis brevis (7), flexor digitorum brevis (12), and the abductor digiti quinti (16). The plantar fascia (14) is well defined.

Section 110

This section is about 18 mm. on the dorsal and 25 mm. on the plantar surface beyond the preceding section. Its position is indicated by line 110 in Key-figures XIII, XIV.

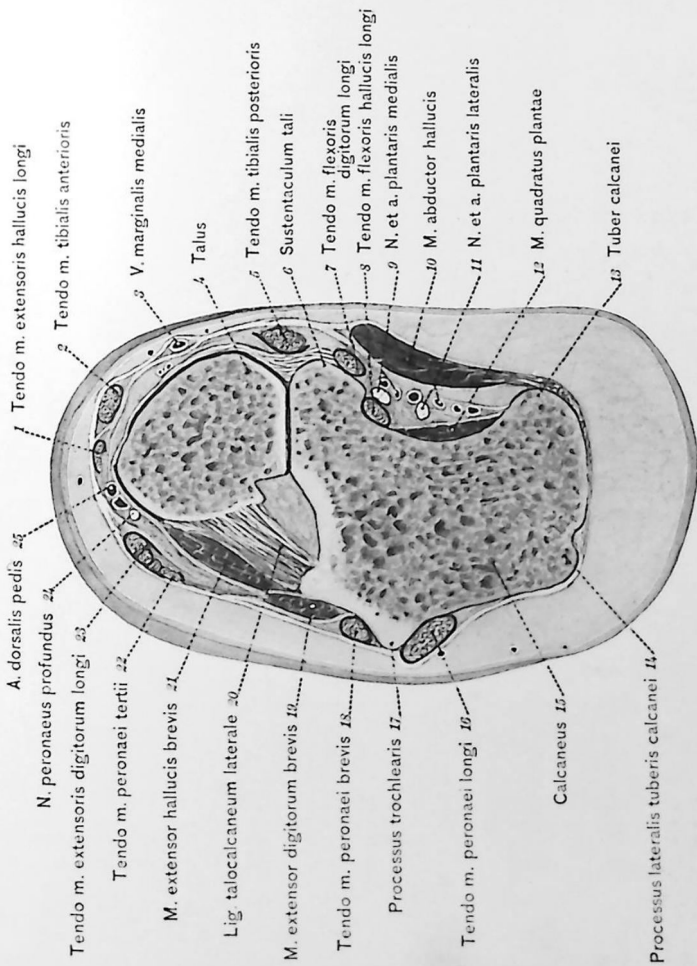
The section passes through the three cuneiform bones (4, 7, 27), through the distal part of the cuboid (24), and the proximal portion of the fifth metatarsal (23). The flexor accessorius (quadratus plantæ) muscle (16) inserts at this level into the tendon of the m. flexor digitorum longus (13). One of the slips of the tibialis posterior muscle is inserted between the second (4) and third (27) cuneiform bones. The tibialis anticus muscle (6) does not extend beyond this section. The plantar ligament (20) breaks up into slips which attach to the bases of the metatarsal bones. The external plantar nerve (17) divides at this level into a superficial and a deep branch, which are labeled in the next section.

Section 111

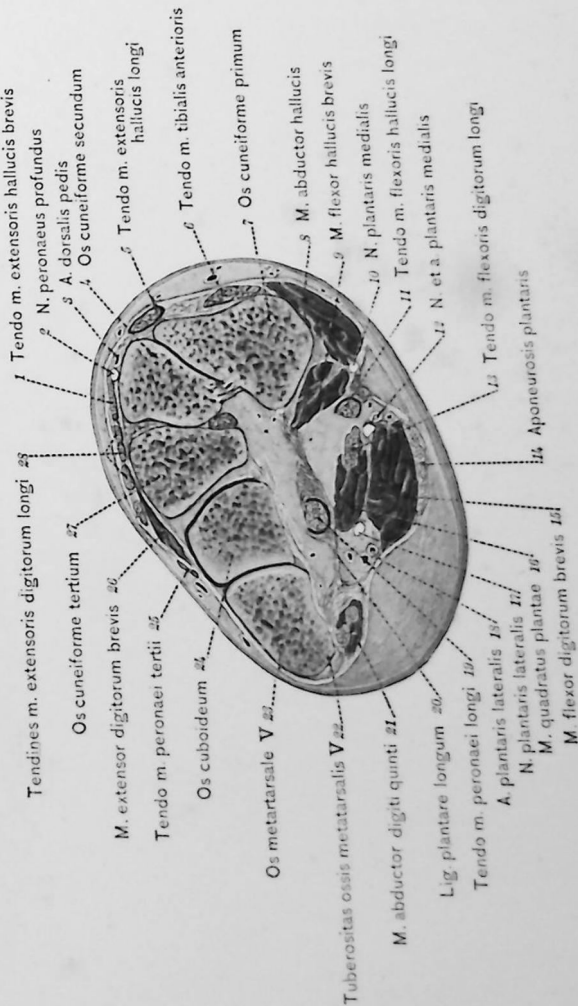
This section is about 23 mm. on the dorsal and 26 mm. on the plantar surface beyond the preceding section. Its position is indicated by line 111 in Key-figures XIII, XIV.

The section passes through the base of the first metatarsal (5) and somewhat beyond the heads of the remaining four metatarsals. The following muscles are first cut: the interossei (19, 21, 24, 29), the lumbricales (11, 13), the oblique head of the adductor hallucis (15), and the opponens digiti quinti (22).

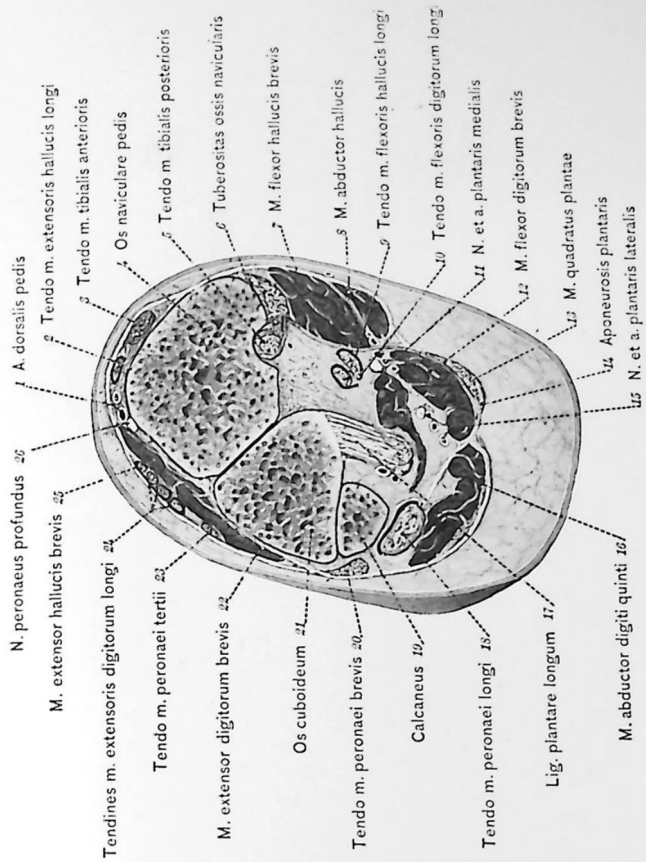
Note.—We have labeled the v. marginalis medialis, Sect. 108, 3, following Spalteholtz, although it is not given in the BNA.



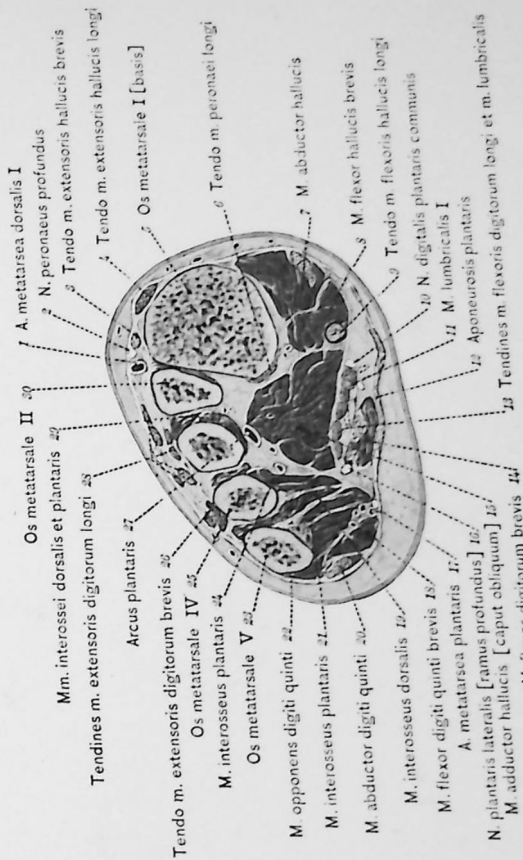
SECTION 108



SECTION 110



SECTION 109



SECTION 111

Sections 112 and 113

Section 112

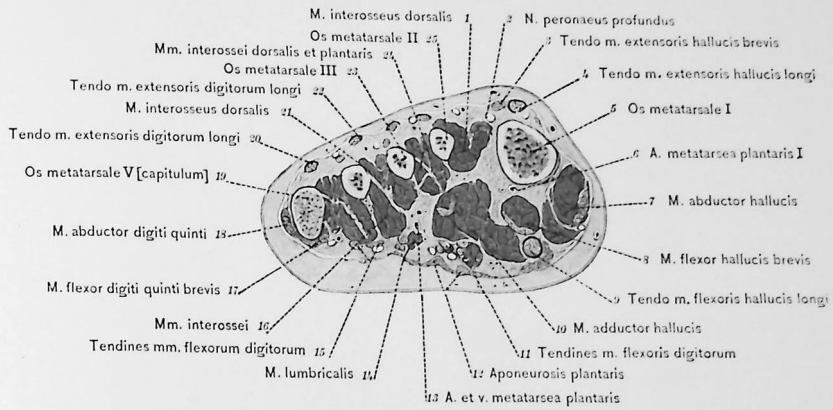
This section is about 22 mm. on the dorsal and 26 mm. on the ventral surface beyond the preceding section. Its level is indicated by line 112 in Key-figures XIII, XIV.

The section passes somewhat beyond the middle of the metatarsal bones. The transverse head of the adductor hallucis muscle is entirely within the section. The plantar arteries have branched to form the metatarsal arteries (6, 13). The plantar nerves have likewise branched into their principal subdivisions; their positions being indicated by 13 in Fig. 113.

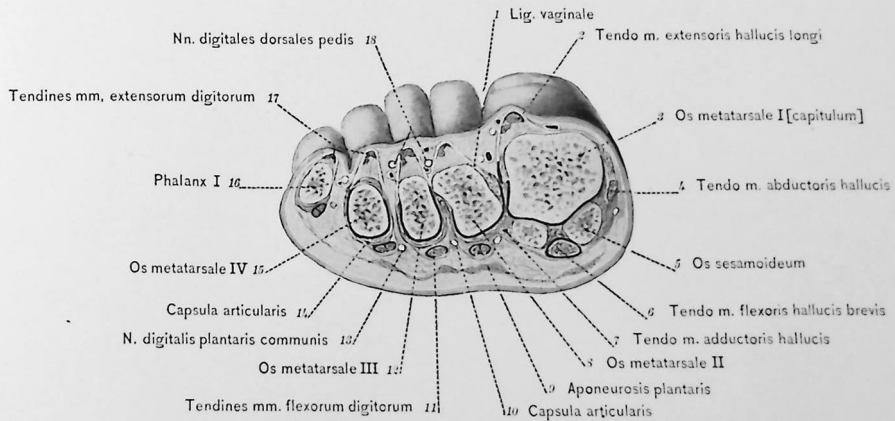
Section 113

This section is the last one of the inferior extremity. Its level is indicated by line 113 in Key-figures XIII, XIV.

The section passes through the distal portion of the first four metatarsal bones (3, 8, 12, 15), and through the proximal end of the first phalanx (16) of the fifth digit. Just below the first metatarsal bone (3) are two sesamoid bones, the one on the right (5) being labeled. The tendons of insertion of the interosseous and lumbrical muscles are no longer separable.



SECTION 112



SECTION 113

TOPOGRAPHY OF THE THORAX AND ABDOMEN

In this chapter we have confined the discussion to the topography of the organs of the thorax and abdomen, since our observations on the topography of other organs are not extended enough to permit generalizations.

The very arduous task of reconstructing ten adult male negro bodies to determine the vertebral levels of the various organs, has been done by Dr. Peter Potter, to whom alone belong the credit and responsibility for the vertebral levels given in all cases, excepting *this* subject.

The projections or reconstructions were made from sections of bodies hardened by intra-arterial injection of fifty-per-cent formalin, according to Dr. Potter's previously published method.

In considering each organ the following order has been observed: first, the individual vertebral levels are given, then the range of variations and finally the average vertebral level, as determined by Dr. Potter. We have supplemented his findings by a number of citations from other authorities. After the discussion of the vertebral level of each organ, we have given a brief description of the relation which this organ in our subject bears to other structures; especially to the anterior thoracic wall. This in turn is followed by citations from various authorities. It will be noted in the following descriptions and the appended table that the levels of some organs are not given for each of the eleven bodies. In such instances the omission is due to the more or less pathological condition of the organs.

The following topographical lines have been used in the descriptions. The anterior *mid-line* of the section is a vertical line passing through the middle of the sternum or linea alba. The posterior *mid-line* of the section is a vertical line through the centers of the spinous processes of the vertebræ. The *mid-plane* or *mesial plane* is the vertical plane determined by these two lines. The *sternal line* is a vertical line along the lateral margin of the sternum. The *mammillary line* is a vertical line through the nipple. The nipple is so variable in position that we have used this term as synonymous with *mid-clavicular line*. The *parasternal line* is a vertical line halfway between the sternal line and the mam-

illary line. The *axillary line* is a vertical line through the apex of the axilla. The *scapular line* is a vertical line through the inferior angle of the scapula.

STERNUM

Suprasternal notch

The suprasternal notch in this subject and one other lies at the level of the upper third of the third thoracic vertebra; in one subject it lies at a level between the upper third of the same vertebra and the second thoracic disc; in two subjects, at the level of the middle third of the third thoracic vertebra; in one, at a level between the upper and lower thirds of the same vertebra; in one, at the level of the third thoracic disc; in one, at a level between the same disc and the upper third of the fourth thoracic vertebra; in one, at the level of the upper third of the second thoracic vertebra; in one, at the level of the middle third of the same vertebra; and in one, at the level of the second thoracic disc.

The variations range from the upper third of the second thoracic vertebra to a level between the third thoracic disc and the upper third of the fourth thoracic vertebra. The average position is at the level of the upper third of the third thoracic vertebra.

Porier and Charpy, and Cunningham place it at the level of the lower part of the second thoracic vertebra. Treves, and Morris place it opposite the second thoracic disc; Sobotta, and Piersol, at the level of the second disc at the end of expiration. Mehnert states that the upper border of the sternum is usually at the level of the second thoracic vertebra or the disc below, but may occasionally lie at the level of the upper portion of the third thoracic vertebra. Langer-Toldt states that the upper border of the sternum is opposite the spinous process of the second thoracic vertebra.

Manubrio-gladiolar junction

The junction of the manubrium and the gladiolus in this subject and four others lies at the level of the middle third of the fifth thoracic vertebra; in one subject it lies at the level of the upper third of the

same vertebra; in one, at a level between the lower third of the same vertebra and the fifth thoracic disc; in one, at a level between the fifth thoracic disc and the upper third of the sixth thoracic vertebra; in one, at the level of the third thoracic disc; in one, at a level between the middle and upper thirds of the sixth thoracic vertebra; in one, at the level of the lower third of the same vertebra.

The variations range from the third thoracic disc to the lower third of the sixth thoracic vertebra. The average position is at the level of the middle third of the fifth thoracic vertebra.

Morris places the manubrio-gladiolar junction opposite the fourth thoracic vertebra; Piersol, opposite the fifth; Cunningham, opposite the spinous process of the third thoracic vertebra.

Xipho-sternal junction

The junction of the xiphoid process with the sternum in this subject and one other lies at the level of the middle third of the tenth thoracic vertebra; in three subjects it lies at the level of the upper third of the same vertebra; in one, at the level of the lower third of the same vertebra; in one, at the level of the seventh thoracic disc; in one, at a level between the middle and lower thirds of the ninth thoracic vertebra; in one, at the level of the lower third of the same vertebra; in one, at the level of the ninth thoracic disc; in one, at the level of the middle of the eleventh thoracic vertebra.

The variations range from the seventh thoracic disc to the middle of the eleventh thoracic vertebra. The average position is between the ninth thoracic disc and the upper third of the tenth thoracic vertebra.

Treves places the xipho-sternal junction opposite the middle of the ninth thoracic vertebra. Morris, and Piersol place it opposite the lower part of the ninth; Cunningham says, opposite the ninth disc and the spinous process of the eighth.

Apex of xiphoid process

The apex of the xiphoid process in this subject and one other lies at the level of the lower third of the twelfth thoracic vertebra; in two subjects it lies at the level of the middle third of the same vertebra; in one, at the level of the ninth thoracic disc; in two, at the level of the middle third of the eleventh thoracic vertebra; in two, at the level of the lower third of the eleventh thoracic vertebra; in one, at a level between the eleventh thoracic disc and the upper third of the twelfth thoracic vertebra; in one, at the level of the upper third of the first lumbar vertebra.

The variations range from the ninth thoracic disc

to the upper third of the first lumbar vertebra. The average position is at the level of the eleventh thoracic disc.

INNOMINATE BONES

Crests of ilia

The crests of the ilia in this subject and one other lie at a level between the middle and lower thirds of the fourth lumbar vertebra; in one subject they lie at the level of the middle of the same vertebra; in four subjects, at the level of the lower third of the same vertebra; in three, at levels between the lower third of the same vertebra and the fourth lumbar disc; in one, at the level of the fourth lumbar disc.

The variations range from the level of the middle third of the fourth lumbar vertebra to the fourth lumbar disc. The average position is at the level of the lower third of the fourth lumbar vertebra.

Morris places the crests of the ilia at the level of the fourth lumbar vertebra; Cunningham, at the fourth lumbar vertebra and the spinous process of the same.

STOMACH

Cardiac orifice

The cardiac orifice in this subject and one other lies at the level of the upper third of the eleventh thoracic vertebra; in three subjects it lies at the level of the middle third of the eleventh thoracic vertebra; in two, at the level of the lower third of the same vertebra; in one, at a level between the upper and middle thirds of the ninth thoracic vertebra; in one, at a level between the ninth thoracic disc and the upper third of the tenth thoracic vertebra; in one, at the level of the lower third of the tenth thoracic vertebra; in one, at the level of the middle third of the twelfth thoracic vertebra.

The variations range from a level between the upper and middle thirds of the ninth thoracic vertebra to the middle of the twelfth thoracic vertebra. The average position is at the level of the upper third of the eleventh thoracic vertebra.

The vertebral level of the cardiac orifice is given by Rüdinger as the ninth thoracic vertebra; by Langer-Toldt, as the ninth to the tenth; by Corning, Morris, and Piersol, as the tenth; by Spalteholtz, and Sobotta as the tenth or eleventh; by Merkel, Joessel, and Schultze, as the eleventh. Cunningham says that it is 2.5 cm. to the left of, and on a level with, the ninth thoracic spine.

Its relation to the anterior thoracic wall in this subject is about 2 cm. to the left of and slightly below the sternal end of the seventh costal cartilage, opposite the sixth intercostal space. According to Rüdinger its position is nearly opposite the sternal ends

of the sixth and seventh left costal cartilages. Corning places it behind the seventh left costal cartilage 3 cm. from the sternum. Cunningham places it opposite a point on the seventh left costal cartilage 2.5 cm. from the sternum.

Fundus

The highest portion of the fundus of the stomach in this subject and one other lies at the level of the ninth thoracic disc; in one, it lies at a level between the upper and middle thirds of the ninth thoracic vertebra; in one, at the level of the middle of the eighth thoracic vertebra; in three, at the level of the middle of the tenth thoracic vertebra; in one, at a level between the middle and the lower thirds of the tenth thoracic vertebra; in two, at the level of the upper third of the eleventh thoracic vertebra; in one, at the level of the eleventh thoracic disc.

The variations range from the middle of the eighth thoracic vertebra to the eleventh thoracic disc. The average position is opposite the middle third of the tenth thoracic vertebra. Cunningham gives the eighth thoracic spine as the vertebral level. Its relation to the anterior thoracic wall in this subject is about opposite the fifth costochondral junction.

According to Joessel the fundus extends from 3 to 5 cm. higher than the cardia. The highest level, according to Porier and Charpy, is that of the fifth rib in the mammillary line. According to Treves, and Morris the highest level is at the sixth chondrosternal junction. Piersol says the fundus rises to the level of the fifth chondrosternal junction.

The lesser and greater curvatures, and the anterior and posterior surfaces, undergo such wide variations in position, owing to degrees of distention, age, etc., that it is practically impossible to give even an average position. The lower margin of the average moderately distended stomach extends, according to Corning, to a level midway between the xiphosternal junction and the umbilicus. Jonnesco, and Merkel say, at the level of a transverse plane passing through the tips of the tenth costal cartilages.

Pylorus

In this subject the pylorus lies at the level of the first lumbar disc; in one, it lies at a level between the first lumbar disc and the upper third of the second lumbar vertebra; in two, it lies at the level of the middle of the first lumbar vertebra; in one, at the level of the upper third of this vertebra; in one, at the level of the lower third of the same vertebra; in one, at the level of the tenth thoracic disc; in one, at the level of the twelfth thoracic disc; in two, at the level of the middle of the second lumbar vertebra;

in one, at a level between the second lumbar disc and the upper third of the third lumbar vertebra.

The variations range from the tenth thoracic disc to a level between the second lumbar disc and the upper third of the third lumbar vertebra. The average level is between the middle and lower thirds of the first lumbar vertebra.

The pyloric orifice lies, according to Braune, and Spalteholtz, at a level somewhere between the eleventh thoracic and the first lumbar vertebra; according to Rüdinger, and Corning, between the twelfth thoracic disc and first lumbar vertebra; according to Sobotta, at the level of the twelfth thoracic vertebra. Joessel, Schultze, Rosenfeld, and Jonnesco place it opposite the first lumbar vertebra. Cunningham places it opposite the twelfth thoracic spine. Addison found that the transpyloric plane in 67.5 per cent of forty subjects examined was within 1 cm. of the level of the first lumbar disc. According to the majority of writers it lies in the median plane or slightly to the right of the same. Spalteholtz says: "In the median line or slightly to the left when empty; when full, markedly to the right." Braune, Merkel, Quain, Cunningham, and Piersol say: "Close to the median line."

With reference to the anterior thoracic wall the pyloric orifice in this subject lies in the median line at a level midway between the xiphosternal junction and the umbilicus. According to Jonnesco and Charpy it lies at the level of a line uniting the internal extremities of the ninth costal cartilages.

DUODENUM, JEJUNUM, ILEUM

Superior portion

The highest portion of the duodenum in this subject lies at the level of the middle of the first lumbar vertebra; in one, it lies at a level between the middle and upper thirds of the same vertebra; in one, at the level of the upper third of the first lumbar vertebra; in one, at a level between the middle and lower thirds of the same vertebra; in one, at the level of the lower third of the tenth thoracic vertebra; in two, at the level of the lower third of the twelfth thoracic vertebra; in two, at the level of the twelfth thoracic disc; in two, at the level of the first lumbar disc.

The variations range from the lower third of the tenth thoracic vertebra to the first lumbar disc. The average position is at a level between the twelfth thoracic disc and the upper third of the first lumbar vertebra. According to Merkel, Cunningham, and Piersol it lies at the level of the first lumbar vertebra. Joessel places it at the same level, but states that this is the position when empty.

Transverse portion

The lower margin of the transverse portion of the duodenum in this subject and two others extends to the level of the upper third of the fourth lumbar vertebra; in one, it extends to the level of the middle of this vertebra; in one, to the level of the fourth lumbar disc; in two, to the level of the middle third of the third lumbar vertebra; in one, to the level of the lower third of the same vertebra; in one, to the level of the third lumbar disc; in one to a level between the third lumbar disc and the upper third of the fourth lumbar vertebra.

The variations range from the middle of the third lumbar vertebra to the fourth lumbar disc. The average position is opposite the middle of the fourth lumbar vertebra.

Corning, and Merkel place the transverse portion of the duodenum opposite the third lumbar vertebra. Piersol, from fifty-four observations, places its lowest point at the fourth lumbar vertebra or the disc above or below; Cunningham, at the third lumbar spine. Fawcett and Blatchford made a large number of observations "On the level at which the lower border of the third part of the duodenum crosses the vertebral column." Three hundred and thirty-seven subjects were examined; of these, one hundred and ninety were males and one hundred and forty-four females. The most common position is opposite the middle third of the third lumbar vertebra. In males the average level is about 1 cm. higher than in females. "In no case was the duodenum found in the male below the fourth lumbar vertebra; as many as seven were below this vertebra in the female." The variations, according to the authors, range from the second lumbar vertebra to the fifth lumbar disc.

Duodeno-jejunal flexure

The duodeno-jejunal flexure in this subject and one other lies at the level of the upper third of the first lumbar vertebra; in one subject it lies at a level between the middle and lower thirds of the same vertebra; in one, at the level of the middle of the eleventh thoracic vertebra; in one, at the level of the lower third of the twelfth thoracic vertebra; in three, at the level of the middle of the second lumbar vertebra; in one, at the level of the lower third of the same vertebra; in one, at the level of the second lumbar disc.

The variations range from the middle of the eleventh thoracic vertebra to the second lumbar disc. The average position is at the level of the lower third of the first lumbar vertebra.

Joessel places it at the level of the first lumbar vertebra; Merkel, opposite the first lumbar disc;

Corning says, opposite the first lumbar disc and again, opposite the second lumbar vertebra. Cunningham places this flexure in the transpyloric plane, which is at the level of the first lumbar; Piersol, opposite the upper part of the second lumbar vertebra.

CÆCUM

Lowest point

The lowest point of the cæcum in this subject lies at the level of the lower third of the fifth sacral vertebra; in two subjects it lies at the level of the middle of the first sacral vertebra; in two, at a level between the upper third of the first sacral vertebra and the fifth lumbar disc; in two, at the level of the middle of the second sacral vertebra; in one, at the level of the upper third of the same vertebra; in one, at the level of the upper third of the third sacral vertebra; in one, at the level of the lower third of the same vertebra; in one, at the level of the fourth lumbar disc.

The variations range from the fourth lumbar disc to the lower portion of the fifth sacral vertebra. The average position is at the level of the second sacral disc. The apex of the cæcum, according to Treves, lies to the inner side of the middle of Poupart's ligament. Sobotta places its lower end at the middle of Poupart's ligament.

Ileo-cæcal valve

The ileo-cæcal valve in this subject lies at the level of the upper third of the second sacral vertebra; in one, it lies at the level of the third lumbar disc; in three, it lies at the level of the middle of the fourth lumbar vertebra; in three, at the level of the middle of the fifth lumbar vertebra; in two, at the level of the lower third of the same vertebra; in one, at the level of the fifth lumbar disc.

The variations range from the third lumbar disc to the upper third of the second sacral vertebra. The average position is at the level of the middle of the fifth lumbar vertebra. Cunningham, and Morris place it at the point of intersection of the intertubercular and Poupartic lines.

VERMIFORM APPENDIX

Base

The point of attachment of the appendix to the cæcum, or, in other words, its origin or base, in this subject lies at the level of the middle third of the third sacral vertebra; in one, it lies at the level of the third lumbar disc; in three, at the level of the fifth lumbar disc; in one, at a level between the fifth lum-

bar disc and the upper third of the first sacral vertebra; in two, at the level of the lower third of the fifth lumbar vertebra; in two, at the level of the middle third of the first sacral vertebra.

The variations range from the third lumbar disc to the middle of the third sacral vertebra. The average position is at the level of the lower third of the fifth lumbar vertebra.

Hewson measured the distance between the base of the appendix and the anterior superior spine of the ilium, and found in the seventy-four subjects measured that the variations ranged from 3 to 16 cm., with an average distance of 7.2 cm. The distance from the umbilicus to the base of the vermiform appendix was measured in forty-six subjects. The variations ranged from 4 to 15 cm., with an average of 7.8 cm.

COLON

Hepatic flexure

The hepatic flexure of the colon in this subject and three others lies at the level of the second lumbar disc; in one, at a level between the second lumbar disc and the upper third of the third lumbar vertebra; in one, at the level of the eleventh thoracic disc; in one, at the level of the middle of the first lumbar vertebra; in one, at a level between the first lumbar disc and the upper third of the second lumbar vertebra; in one, at a level between the middle and upper thirds of the second lumbar vertebra; in one, at the level of the first lumbar disc; in one, at the level of the lower third of the third lumbar vertebra.

The variations range from the eleventh thoracic disc to the lower third of the third lumbar vertebra. The average position is at the level of the second lumbar vertebra.

Hermann and Ruedel place the hepatic flexure at the level of the upper part of the third lumbar vertebra. Quain places it at the level of the first lumbar vertebra; Cunningham, at the level of the first lumbar spine.

Splenic flexure

The splenic flexure of the colon in this subject and one other lies at the level of the eleventh thoracic disc; in one, at the level of the lower third of the tenth thoracic vertebra; in one, at a level between the ninth thoracic disc and the upper third of the tenth thoracic vertebra; in two, at the level of the upper third of the twelfth thoracic vertebra; in two, at the level of the lower third of the same vertebra; in one, at the level of the upper third of the first lumbar vertebra; in one, at the level of the first lum-

bar disc; in one, at a level between the middle and upper thirds of the second lumbar vertebra.

The variations range from the ninth thoracic disc to a level between the upper and middle thirds of the second lumbar vertebra. The average position is at the level of the middle of the twelfth thoracic vertebra. According to Cunningham it lies at the level of the twelfth thoracic spine.

With reference to the thoracic wall, the upper margin of the splenic flexure in this subject lies nearly opposite the seventh rib. According to Fromont, it is usually at the level of the seventh or eighth rib.

PANCREAS

Head

The lowest point of the head of the pancreas in this and two other subjects lies at the level of the second lumbar disc; in one, it lies at a level between this disc and the upper third of the third lumbar vertebra; in one, at the level of the middle of the second lumbar vertebra; in one, at the level of the middle of the third lumbar vertebra; in three, at the level of the upper third of the third lumbar vertebra; in one, at the level of the third lumbar disc; in one, at the level of the upper third of the fourth lumbar vertebra.

The variations range from the middle of the second lumbar vertebra to the upper third of the fourth lumbar vertebra. The average position is at the level of the upper third of the third lumbar vertebra.

Corning places the head of the pancreas at the level of the second lumbar vertebra. Charpy states that the head is usually at the level of the first and second lumbar vertebrae, frequently as low as the second lumbar disc, and sometimes as low as the third lumbar disc. Morris places it at the level of the first or second lumbar vertebra. Cunningham says that it lies at the level of the twelfth thoracic or the first lumbar spine, and that its lowest part lies at the level of the second lumbar spine.

Body

The highest point of the body of the pancreas in this subject lies at the level of the lower third of the eleventh thoracic vertebra; in one, it lies at the level of the ninth thoracic disc; in two, at the level of the upper third of the twelfth thoracic vertebra; in two, at the level of the middle of the same vertebra; in one, at the level of the lower third of the same vertebra; in one, at the level of the twelfth thoracic disc; in one, at the level of the upper third of the first lumbar vertebra; in one, at the level of the mid-

dle third of the same vertebra; in one, at the level of the lower third of the same vertebra.

The variations range from the ninth thoracic disc to the lower third of the first lumbar vertebra. The average position is at the level of the middle of the twelfth thoracic vertebra.

According to Braune, Schiefferdecker, Tschaussow, Sandras, and Zuckerkandl, the body of the pancreas lies opposite the first lumbar vertebra; according to Sappey, and Hyrtl it lies opposite the second lumbar. Wiart states that it lies opposite the lower half of the first lumbar and the upper half of the second lumbar vertebra; Merkel says, opposite the first lumbar and the upper part of the second. Charpy states that "the body of the pancreas is opposite the first lumbar. When a trifle high, it is opposite the lower half of the twelfth thoracic; sometimes it is low and thus corresponds to the second lumbar."

Tail, tip of

The tip of the tail of the pancreas in this subject lies at the level of the middle of the eleventh thoracic vertebra; in one, it lies at the level of the middle of the ninth thoracic vertebra; in two, at the level of the upper third of the twelfth thoracic vertebra; in one, at the level of the middle of the same vertebra; in one, at the level of the lower third of the same vertebra; in one, at the level of the upper third of the first lumbar vertebra; in one, at the level of the lower third of the same vertebra.

The variations range from the middle of the ninth thoracic vertebra to the lower third of the first lumbar vertebra. The average position is at the level of the upper third of the twelfth thoracic vertebra. Cunningham states that it lies opposite the twelfth thoracic spine.

LIVER

Right lobe, highest point

The highest point of the upper or superior surface of the liver in this subject lies at the level of the upper third of the tenth thoracic vertebra; in one, it lies at a level between the lower third of the ninth thoracic vertebra and the ninth thoracic disc; in one, it lies at the level of the middle third of the ninth thoracic vertebra; in two, at the level of the lower third of the ninth thoracic vertebra; in one, at the level of the ninth thoracic disc; in one, at the level of the lower third of the seventh thoracic vertebra; in one, at the level of the eighth thoracic disc; in one, at the level of the lower third of the tenth thoracic vertebra; in one, at the level of the tenth thoracic disc; in one, at the level of the middle of the eleventh thoracic vertebra.

The variations range from the lower third of the seventh thoracic vertebra to the middle of the eleventh thoracic vertebra. The average is at the level of the lower third of the ninth thoracic vertebra.

Its relation to the anterior wall in this subject is as follows: the highest point of the liver lies at the level of the fourth intercostal space in the parasternal line; at the level of the upper margin of the fifth rib in the mammillary line; on the left side its upper margin is somewhat lower. The lateral margin of the liver on the left reaches to the mammillary line. The round ligament is 2.5 cm. to the right of the median line.

Luschka, and Corning place the upper surface of the right lobe at the costochondral junction of the fourth rib. Spalteholz describes and figures the upper surface as opposite the fourth intercostal space. Merkel, and Morris place the upper surface at about the level of the upper border of the fifth rib or the fourth intercostal space in the mammillary line; Toldt, and Treves say, at the fifth costochondral junction.

Right lobe, lowest point

The lowest point of the liver on the right side of the body in this subject lies at the level of the upper third of the fourth lumbar vertebra; in one, it lies at the level of the lower third of the fourth lumbar vertebra; in two, at the level of the fourth lumbar disc; in one, at the level of the lower third of the second lumbar vertebra; in one, at a level between the second lumbar disc and the upper third of the third lumbar vertebra; in one, at the level of the upper third of the third lumbar vertebra; in one, at a level between the upper and middle thirds of the third lumbar vertebra; in one, at the level of the middle of the third lumbar vertebra; in two, at a level between the lower third of the same vertebra and the third lumbar disc.

The variations range from the lower third of the second lumbar vertebra to the fourth lumbar disc. The average position is at a level between the lower third of the third lumbar vertebra and the third lumbar disc. According to Treves it lies at the level of the second lumbar spine.

In this subject the lowest point on the right side lies considerably lower than the average, being less than 1.5 cm. above the iliac crest. Langer-Toldt, Joessel, and Corning state that the lowest point on the right side corresponds in life to the costal margin. Merkel, Treves, Morris, and Cunningham say that in the upright position it projects a little beyond the costal margin, while in the recumbent position it ascends 2 to 3 cm.

Anterior margin, mid-line

The anterior margin of the liver in the mid-line in this and two other subjects lies at the level of the second lumbar disc; in one, at the level of the upper third of the tenth thoracic vertebra; in two, at the level of the middle third of the twelfth thoracic vertebra; in one, at the level of the upper third of the first lumbar vertebra; in one, at a level between the lower third of the first lumbar vertebra and the first lumbar disc; in two, at the level of the first lumbar disc; in one, at the level of the lower third of the second lumbar vertebra.

The variations range from the upper third of the tenth thoracic vertebra to the second lumbar disc. The average position is at the level of the lower third of the first lumbar vertebra.

In this subject the anterior margin of the liver in the mid-line lies opposite the middle third of the space between the xiphoid-sternal junction and the umbilicus.

The lower margin, according to Joessel, lies opposite a line joining the tips of the ninth left and the tenth right costal cartilages. Langer-Toldt defines the lower border by a line joining the middle of the seventh costal cartilage on the left and the tip of the eighth on the right. Quain, Treves, and Piersol say that the lower margin corresponds to a line passing from the tip of the eighth left to that of the ninth right costal cartilages. Merkel says it crosses the right costal margin at the tip of the ninth rib. Schultze says: "In the right mammillary line the inferior border leaves the costal margin, passes obliquely upward and to the left, crosses the median line midway between the navel and the xiphoid process and reaches the left costal margin in the parasternal line." Corning places its anterior margin, in the median line, midway between the base of the xiphoid and the umbilicus.

According to Charpy, the lower border of the liver in the mid-line usually lies opposite the upper third of the space between the xiphoid and the umbilicus. The lower border of the liver, according to Cunningham, passes from the eighth left to the tip of the tenth right costal cartilages.

GALL BLADDER

Lowest point

The lowest point of the gall bladder in this subject lies at the level of the third lumbar disc; in one, it lies at the level of the upper third of the twelfth thoracic vertebra; in one, at the level of the lower third of the first lumbar vertebra; in two, at the level of the first lumbar disc; in two, at the level

of the second lumbar disc; in two, at a level between this disc and the upper third of the third lumbar vertebra; in one, at the level of the middle third of the third lumbar vertebra; in one, at the level of the upper third of the fourth lumbar vertebra.

The variations range from the upper third of the twelfth thoracic vertebra to the upper third of the fourth lumbar vertebra. The average position is at the level of the lower third of the second lumbar vertebra.

The position of the fundus of the gall bladder when projected on the anterior abdominal wall is given by Langer-Toldt as the angle formed, on the right side, by the rectus muscle and the costal margin. Merkel places it opposite the tip of the ninth right costal cartilage; Joessel, opposite the lower border of the tip of the ninth costal cartilage; Corning, opposite the tip of the eighth costal cartilage; Sobotta, opposite the tip of the ninth or tenth costal cartilage. Morris, Cunningham, and Piersol place it opposite the tip of the ninth costal cartilage. According to Raynal and Siraud, its fundus is immediately below the costal border and corresponds in the majority of cases to the anterior cartilaginous extremity of the tenth rib, the subject being supine. Sometimes it may be opposite the cartilaginous extremity of the ninth rib, or again opposite that of the eleventh.

SPLEEN

Highest point

The highest point of the spleen in this subject and one other lies at the level of the ninth thoracic disc; in one, it lies at the level of the upper third of the tenth thoracic vertebra; in one, at a level between the upper and middle thirds of the tenth thoracic vertebra; in one, at a level between the upper third of the eighth thoracic vertebra and the seventh thoracic disc; in one, at the level of the middle third of the tenth thoracic vertebra; in one, at the level of the lower third of the tenth thoracic vertebra; in one, at the level of the tenth thoracic disc; in two, at the level of the middle of the eleventh thoracic vertebra; in one, at the level of the lower third of the same vertebra.

The variations range from a level between the seventh thoracic disc and the upper third of the eighth thoracic vertebra to the lower third of the eleventh thoracic vertebra. The average position is at the level of the lower third of the tenth thoracic vertebra.

Piersol places the highest point of the spleen at the level of the ninth thoracic vertebra, while Joessel places it at the level of the tenth thoracic ver-

tebra. The vertebral level, according to Quain, Treves, Morris, and Cunningham is the ninth thoracic spine.

Lowest point

The lowest point of the spleen in this subject lies at the level of the upper third of the twelfth thoracic vertebra; in one, it lies at the level of the eleventh thoracic disc; in three, at the level of the upper third of the first lumbar vertebra; in one, at a level between the middle and upper thirds of the first lumbar vertebra; in one, at a level between the middle and lower thirds of the same vertebra; in one, at the level of the lower third of the same vertebra; in one, at the level of the first lumbar disc; in one, at the level of the lower third of the second lumbar vertebra; in one, at a level between the lower third of the second lumbar vertebra and the second lumbar disc.

The variations range from the eleventh thoracic disc to the second lumbar disc. The average position is at the level of the middle third of the first lumbar vertebra.

The lowest point, according to Quain, and Treves, is at the level of the first lumbar spine; Piersol says at the first or second lumbar vertebra. Cunningham places it at the level of the twelfth thoracic spine; again, at the first lumbar spine. Morris places it at the level of the twelfth thoracic spine, and states that it may be at the level of the eleventh thoracic vertebra.

Its relation to the thoracic wall in this subject is as follows: in the scapular line its upper margin lies at the level of the upper margin of the ninth rib. Its long axis coincides with the ninth rib. Its maximal mesial extension is within about 4 cm. of the mesial plane. It lies nearly opposite the eighth, ninth, and tenth ribs.

Langer-Toldt states that it lies parallel to the ninth and tenth intercostal spaces. Merkel, and Corning place it parallel to the ninth, tenth and eleventh ribs. A line drawn from the top of the sternum to the tip of the eleventh rib should lie anterior to the spleen. According to Picou, the internal extremity (upper end) is about 4.5 cm. to the left of the mid-line in the upper portion of the tenth intercostal space. The external extremity (anterior angle), on the average, corresponds to the inferior border of the ninth rib. The posterior basal angle (posterior angle) corresponds to the eleventh rib in the posterior axillary line. The crenated border (anterior border) is opposite the tenth rib about 6 cm. from the mid-line; it is opposite the ninth rib in the scapular line, and the lower border of the eighth rib in the axillary line.

TRACHEA

Origin

The trachea begins in this subject at the level of the upper third of the seventh cervical vertebra. According to Luschka, and Hyrtl it lies at the level of the fifth cervical vertebra; Braune, Gerlach, Gegenbaur, Rauber, Langer-Toldt, Joessel, Morris, and others say, at the level of the sixth cervical vertebra. Sappey, Merkel, Corning, and others place it opposite the sixth cervical disc; Nicholas, and Piersol, opposite the seventh cervical vertebra; Cunningham, opposite the sixth cervical spine.

Bifurcation

The bifurcation of the trachea in this and one other subject lies at the level of the upper third of the fifth thoracic vertebra; in three, it lies at the level of the lower third of the same vertebra; in one, at the level of the lower third of the fourth thoracic vertebra; in one, at the level of the fourth thoracic disc; in two, at the level of the upper third of the sixth thoracic vertebra; in one, at a level between the middle and lower thirds of the same vertebra; in one, at the level of the middle of the seventh thoracic vertebra.

The variations range from the lower third of the fourth to the middle of the seventh thoracic vertebra. The average position is at the level of the lower third of the fifth thoracic vertebra.

Hyrtl, Testut, and Nicholas place it at the level of the third thoracic vertebra. Luschka, Sappey, Gegenbaur, Rüdinger, Rauber, and Langer-Toldt place it at the level of the fourth thoracic vertebra. Joessel, and Corning place it opposite the fourth or the fifth thoracic vertebra. Henle, Merkel, Bianchi and Cocchi place it at the level of the fifth thoracic vertebra. Gerlach, and Cunningham state that its level is indicated by the tip of the third thoracic spine.

With reference to the anterior thoracic wall it lies, in this subject, opposite the upper margin of the costo-sternal junction of the second rib. Piersol says it lies opposite the manubrio-gladiolar junction.

LUNGS

Right, apex

The apex of the right lung in this and two other subjects lies at a level between the seventh cervical disc and the upper third of the first thoracic vertebra; in two, at the level of the seventh cervical disc; in two, at the level of the upper third of the first thoracic vertebra; in one, at the level of the

middle of the first thoracic vertebra; in two, at the level of the lower third of the same vertebra; in one, at the level of the first thoracic disc.

The variations range from the seventh cervical disc to the first thoracic disc. The average position is at the level of the upper third of the first thoracic vertebra.

The level, according to Merkel, is the first thoracic vertebra. Merkel further states that a section passing horizontally through the seventh cervical disc does not cut the lung. Morris states that the apex is opposite the seventh cervical vertebra, and again, opposite the first thoracic vertebra, while Cunningham says, at the level of the seventh cervical spine.

Langer-Toldt, Joessel, and Corning state that it extends to the neck of the first rib. Merkel, and Piersol say that it never extends above this level. Its distance above the level of the sternal end of the first rib is given by Langer-Toldt as about 3 cm.; by Joessel, as 5 cm.; by Treves, and Cunningham as 2.5 to 5 cm.; by Piersol, as 3 cm. With reference to its distance above the clavicle there is considerable divergence of opinion: Pansch gives 1 to 3 cm.; Joessel, 3 cm.; Merkel, 3.5 cm.; Corning, 2 to 3 cm.; Treves, 1 to 3 cm.; Cunningham, 1.3 to 3.8 cm.; Piersol, 1 cm. It should be recalled in this connection that some topographic anatomists—Luschka, Krause, Braune, and Cunningham—state that the apex of the right lung is from .5 to 1 cm. higher than the left. Others—Henle, Pansch, Merkel, and Joessel—state that there is no appreciable difference.

Right, base

The lowest point of the anterior margin of the base of the right lung in this subject and one other lies at the level of the tenth thoracic disc; in one, it lies at the level of the lower third of the tenth thoracic vertebra; in two, at the level of the ninth thoracic disc; in one, at the level of the middle of the eleventh thoracic vertebra; in two, at the level of the lower third of the same vertebra; in one, at the level of the upper third of the twelfth thoracic vertebra; in one, at the level of the middle third of the same vertebra; in one, at the level of the lower third of the same vertebra.

The variations range from the ninth thoracic disc to the lower third of the twelfth thoracic vertebra. The average position is at the level of the middle of the eleventh thoracic vertebra.

The level of the lower border of the right lung may be defined, according to Joessel, Corning, and others by drawing a gentle curve from the sternal end of the sixth rib to the vertebral end of the eleventh rib. According to Merkel, Treves, and Cun-

ningham, it lies in the mammillary line at the lower border of the sixth rib. Merkel places it in the axillary line from the seventh to the eighth rib; Cunningham, at the eighth rib after expiration; Piersol, at the eighth rib. Merkel locates it in the scapular line opposite the ninth to the tenth rib. Treves, and Cunningham place it opposite the tenth. Morris places it opposite the ninth rib. According to Joessel, Merkel, Corning, and Morris its vertebral level is opposite the eleventh rib. According to Cunningham, and Piersol, the spinous process of the tenth thoracic vertebra serves as a guide to locate its level.

The right lung in this subject extends anteriorly in the mammillary line to the level of the fifth costal cartilage. In the axillary line it extends to the upper margin of the ninth costal cartilage. In the scapular line it extends to the tenth intercostal space. Its vertebral extremity reaches to the level of the spinous process of the eleventh thoracic vertebra.

Right, fissures

The oblique fissure in this subject begins at the neck of the fifth rib slightly above the level of the tip of the fourth thoracic spine, and opposite the lower third of the fourth thoracic vertebra. It ends opposite the sixth rib at a distance some 5 cm. outside the mammillary line.

The fissure of the right lung, although variable, is somewhat lower than the average in this subject. Porier and Charpy, and Testut state that it begins at the level of the vertebral extremity of the third to the fifth rib. The majority of writers place its origin on a level with the vertebral extremity of the third or fourth rib, about opposite the base of the spine of the scapula.

The horizontal fissure of the right lobe in this subject begins opposite the sixth rib in the axillary line, and extending upward and forward, ends at the sternum in the third intercostal space. It is thus somewhat abnormal in this subject. The upper margin of the inferior lobe of the right lung in this subject begins on a level posteriorly with the tip of the fourth thoracic spine, and at the level of the middle of the neck of the sixth rib.

Left, apex

The apex of the left lung in this subject and one other lies at a level between the seventh cervical disc and the upper third of the first thoracic vertebra; in three, it lies at the level of the upper third of the first thoracic vertebra; in four, at the level of the middle third of the same vertebra; in two, opposite the lower third of the same vertebra.

The variations range from a level between the

seventh cervical disc and the upper third of the first thoracic vertebra to the lower third of the first thoracic vertebra. The average position is at the level of the middle third of the first thoracic vertebra. Cunningham places it at the level of the seventh cervical spine.

Left, base, lowest point

The lowest point of the anterior margin of the base of the left lung in this subject lies at the level of the upper third of the tenth thoracic vertebra; in one, it lies at the level of the lower third of the same vertebra; in one, at the level of the middle third of the ninth thoracic vertebra; in one, at the level of the lower third of the same vertebra; in one, at the level of the ninth thoracic disc; in three, at the level of the middle third of the eleventh thoracic vertebra; in one, at the level of the lower third of the eleventh thoracic vertebra; in one, at the level of the eleventh thoracic disc; in one, at the level of the middle of the twelfth thoracic vertebra.

The variations range from the middle of the ninth to the middle of the twelfth thoracic vertebra. The average position is at the level of the tenth thoracic disc.

The left lung in this subject extends anteriorly in the mammillary line to the level of the fifth intercostal space. In the mid-axillary line it reaches to the level of the seventh rib. In the scapular line it reaches to the level of the tenth rib. Its vertebral extremity is opposite the lower margin of the head of the eleventh rib. The lower margin, according to Joessel, begins at the sixth rib in the parasternal line and extends downward in a uniformly curved line to the head of the eleventh rib.

Left, fissure

The fissure of the left lung in this subject begins posteriorly at the level of the middle third of the second thoracic vertebra, and ends opposite the fifth rib about 2 cm. outside the mammillary line.

Merkel, Schultze, Spalteholtz, Corning, Porier and Charpy, Testut, and others state that it ends opposite the junction of the sixth rib with its costal cartilage near the mammillary line.

Respiratory changes

During moderate respiration, according to Porier and Charpy, and Cunningham, the distance between the apex and the upper margin of the clavicle ranges from 1 to 3 cm. According to Porier and Charpy, the apex may lie behind the clavicle in strong or forced inspiration. From the data given by various authors the maximal range of levels of the upper

margin of the clavicles, with reference to the apices of the lungs, is from 1 to 3 cm.

The lower borders of the lungs are approximately the same on both sides, and in moderate respiration, according to Corning, are as follows: In the mammillary line at the level of the sixth rib; in the axillary line, at the level of the eighth rib; in the scapular line, at that of the tenth rib; and at the vertebral column, at the level of the upper half of the eleventh thoracic vertebra. Gerlach gives the following levels in deep inspiration: in the sternal line the lower border of the sixth rib; in the parasternal line the superior border of the seventh rib; in the mammillary line the eighth rib; in the axillary line the inferior border of the ninth rib; in the scapular line the superior border of the eleventh rib.

The average displacement of the lung in the upright position, according to Porier and Charpy, is 1.5 to 2 cm. in the right parasternal line; 2 to 3 cm. in the right mammillary line; 3 to 4 cm. in both the right and left axillary lines; in the scapular line about 2 cm. (Weill), and at the vertebral column 3 cm. (Eichhorst). In the recumbent dorsal position according to Gerhardt the lungs descend from 1 to 2 cm. lower. In the recumbent lateral position the lung on the free side may, in very deep inspiration, completely fill the pleural cavity.

KIDNEYS

Right, superior extremity

The superior extremity of the right kidney in this subject and one other lies at the level of the middle of the twelfth thoracic vertebra; in one, at the level of the upper third of the same vertebra; in two, at a level between the middle and lower thirds of the same vertebra; in one, at the level of the lower third of the same vertebra; in one, at the level of the twelfth thoracic disc; in one, at the level of the middle of the tenth thoracic vertebra; in one, at the level of the middle of the eleventh thoracic vertebra; in one, at the level of the eleventh thoracic disc; in one, at the level of the middle of the first lumbar vertebra.

The variations range from the middle of the tenth thoracic vertebra to the middle of the first lumbar vertebra. The average position is at the level of the upper third of the twelfth thoracic vertebra.

According to Merkel, Corning, and Morris, the highest point of the right kidney lies at the level of the twelfth thoracic vertebra. Joessel places it at the level of the lower border of the twelfth; Piersol, at the upper border of the twelfth thoracic vertebra.

Cunningham places it at the level of the twelfth thoracic spine.

Right, inferior extremity

The inferior extremity of the right kidney in this and two other subjects lies at the level of the lower third of the third lumbar vertebra; in one, at a level between the lower third of the same vertebra and the third lumbar disc; in one at the level of the middle of the same vertebra; in two, at the level of the second lumbar disc; in three, at the level of the third lumbar disc; in one, at the level of the upper third of the fourth lumbar vertebra.

The variations range from the second lumbar disc to the upper third of the fourth lumbar vertebra. The average position is at the level of the lower third of the third lumbar vertebra.

According to Merkel, Corning, Piersol, and Joessel, the inferior extremity of the right kidney lies at the level of the third lumbar vertebra. Cunningham places it at the level of the third lumbar spine.

Left, superior extremity

The superior extremity of the left kidney in this subject lies at the level of the tenth thoracic disc; in one subject it lies at the level of the ninth thoracic disc; in two, at the level of the eleventh thoracic disc; in two, at a level between this disc and the upper third of the twelfth thoracic vertebra; in one, at the level of the upper third of the twelfth thoracic vertebra; in two, at the level of the middle third of the same vertebra; in one, at a level between the middle and lower thirds of the same vertebra; in one, at a level between the lower third of the twelfth thoracic vertebra and the twelfth thoracic disc.

The variations range from the ninth thoracic disc to a level between the lower third of the twelfth thoracic vertebra and the twelfth thoracic disc. The average position is at the level of the eleventh thoracic disc.

According to Merkel, Spalteholtz, Corning, and Piersol, the highest point of the left kidney lies at the level of the eleventh thoracic vertebra. Joessel says that it lies at the upper border of the twelfth; Cunningham, at the level of the tenth thoracic spine.

Left, inferior extremity

The inferior extremity of the left kidney in this and one other subject lies at the level of the middle of the third lumbar vertebra; in one, at the level of the upper third of the same vertebra; in one, at the level of the lower third of the same vertebra; in one, at a level between the lower third of the same vertebra and the third lumbar disc; in two, at the level

of the second lumbar disc; in one, at a level between the second lumbar disc and the upper third of the third lumbar vertebra; in three, at the level of the third lumbar disc.

The variations range from the second lumbar disc to the third lumbar disc. The average position is at the level of the middle of the third lumbar vertebra.

According to Corning, the inferior extremity of the left kidney is at the level of the second lumbar disc. Morris says that it lies at the middle of the second lumbar; Piersol, at the lower border of the second lumbar; Merkel, at the upper border of the third lumbar; Joessel, at the middle of the third lumbar; Spalteholtz, at the third lumbar; Cunningham, at the third lumbar spine.

Recamier, Glateney and Gosset say that in the great majority of cases the kidneys lie opposite the twelfth thoracic and the first and second lumbar vertebrae. The normal variations, according to the latter authors, range from the upper margin of the eleventh thoracic vertebra to the lower margin of the third lumbar vertebra.

Birmingham, and Thompson, in a large number of subjects studied, found the average distances of the kidneys from the iliac crests as follows: Right kidney in males, average distance, 3.2 cm.; in females, 2.7 cm. Highest in males, 6.5 cm.; in females, 7.5 cm. Lowest in males, even with the iliac crest; in females, below the iliac crest. Left kidney in males, average distance, 4 cm.; in females, 3 cm. Highest in males, 8.5 cm.; in females, 7.5 cm. Lowest in both males and females, about the same distances as given for the right kidney.

SUPRARENALS

Right, apex

The highest point of the right suprarenal in this subject lies at the level of the upper third of the eleventh thoracic vertebra; in two, at the level of the middle third of the same vertebra; in two, at the level of the lower third of the same vertebra; in three, at the level of the eleventh thoracic disc; in two, at the level of the upper third of the eleventh thoracic vertebra.

The variations range from the upper third of the eleventh thoracic vertebra to the upper third of the twelfth thoracic vertebra. The average position is at the level of the lower third of the eleventh thoracic vertebra.

Right, lowest point

The lowest point of the right suprarenal in this subject lies at the level of the middle third of the first

lumbar vertebra; in one, it lies at the level of the upper third of the same vertebra; in one, at the level between the middle and lower thirds of the same vertebra; in five, at the level of the lower third of the same vertebra; in one, at the level of the twelfth thoracic disc; in one, at the level of the upper third of the second lumbar vertebra.

The variations range from the twelfth thoracic disc to the upper third of the second lumbar vertebra. The average position is at a level between the middle and lower thirds of the first lumbar vertebra.

Left, superior margin

The highest point of the left suprarenal in this subject lies at the level of the upper third of the eleventh thoracic vertebra; in one, at the level of the middle third of the same vertebra; in three, at the level of the eleventh thoracic disc; in two, at the level of the upper third of the twelfth thoracic vertebra; in two, at the level of the middle third of the same vertebra; in one, at the level of the twelfth thoracic disc.

The variations range from the upper third of the eleventh thoracic vertebra to the twelfth thoracic disc. The average position is at a level between the eleventh thoracic disc and the upper third of the twelfth thoracic vertebra.

Left, lowest point

The lowest point of the left suprarenal in this and two other subjects lies at the level of the middle third of the first lumbar vertebra; in one, it lies at a level between the middle and upper thirds of the same vertebra; in two, at the level of the first lumbar disc; in three, at the level of the upper third of the second lumbar vertebra; in one, at the level of the middle third of the same vertebra.

The variations range from a level between the upper and middle thirds of the first lumbar vertebra to the middle third of the second lumbar vertebra. The average position is at the level of the lower third of the first lumbar vertebra.

Joessel says that the suprarenals overlap the lower half of the eleventh and upper half of the twelfth thoracic vertebra. Delamare says that the left suprarenal lies at the level of the twelfth thoracic and the first lumbar vertebra. According to Luschka, Sappey, and Delamare, the right suprarenal lies at the level of the twelfth thoracic vertebra. Corning says that the classical levels of the right and left suprarenals are the eleventh and twelfth thoracic vertebrae.

HEART AND HEART VALVES

Base, highest point

The highest point of the base of the heart in this subject lies at a level between the fifth thoracic disc and the upper third of the sixth thoracic vertebra; in one, it lies at the level of the upper third of the sixth thoracic vertebra; in one, at the level between the lower third of the same vertebra and the sixth thoracic disc; in two, at the level of the sixth thoracic disc; in one, at the level of the lower third of the fourth thoracic vertebra; in one, at the level of the lower third of the fifth thoracic vertebra; in one, at the level of the upper third of the seventh thoracic vertebra; in one, at the level of the upper third of the eighth thoracic vertebra.

The variations range from the lower third of the fourth to the upper third of the eighth thoracic vertebra. The average position is at a level between the middle and lower thirds of the sixth thoracic vertebra.

Merkel, and Morris place the highest point of the base of the heart at the level of the fifth thoracic vertebra; Giacomini, and Cunningham, at the level of the fourth thoracic spine.

Apex, lowest point

The lowest point of the apex of the heart in this subject and one other lies at the level of the tenth thoracic disc; in two, it lies at the level of the middle of the tenth thoracic vertebra; in one, at the level of the eighth thoracic disc; in one, at the level of the ninth thoracic disc; in one, at the level of the upper third of the eleventh thoracic vertebra; in one, at the level of the middle third of the same vertebra; in one, at the level of the eleventh thoracic disc.

The variations range from the eighth thoracic disc to the eleventh thoracic disc. The average position is at the level of the lower third of the tenth thoracic vertebra. Merkel gives the average level of the apex as the ninth thoracic vertebra. Sibson, and Cunningham say that it lies at the level of the eighth thoracic spine.

In this subject the apex of the heart, with reference to the anterior thoracic wall, lies in the fifth intercostal space in the mammillary line. According to Joessel, Schultze and others the apex lies at the level of the fifth intercostal space midway between the parasternal and the mammillary lines. According to Merkel, the heart is so movable that it is impossible to give definite topographic data. Merkel quotes Ebstein as follows: "The heart in men whose heights range from 130 to 170 cm. extends from 2 to 2.5 cm. to the right of the sternum. In

men whose heights range from 170 to 190 cm. the heart extends 2.5 to 3 cm. to the right of the sternum." Merkel states that a normal heart does not extend to the left beyond the mammillary line, but usually is slightly mesial of this line. Downward a normal heart extends to the xipho-sternal junction, seldom if ever overlapping the upper end of the xiphoid.

Tricuspid valve

The tricuspid valve in this subject and one other lies at the level of the eighth thoracic disc; in one, it lies at a level between the same disc and the lower third of the eighth thoracic vertebra; in one, at the level of the upper third of the seventh thoracic vertebra; in one, at the level of the seventh thoracic disc; in one, at the level of the middle of the ninth thoracic vertebra; in two, at the level of the lower third of the same vertebra; in one, at the level of the middle third of the tenth thoracic vertebra.

The variations range from the upper third of the seventh to the middle third of the tenth thoracic vertebrae. The average position is at the level of the upper third of the ninth thoracic vertebra.

With reference to the anterior thoracic wall the tricuspid valve in this subject lies slightly to the right of the median line, opposite the sternal end of the fourth intercostal space.

Braune says that the center of this valve lies opposite the middle of the right half of the sternum, at the level of the sternal end of the fourth costal cartilage. Merkel draws a line, slightly curved to the right, from a point in the lower margin of the third costal cartilage (1.5 to 1.8 cm. to the left of the sternum) to the sternal end of the sixth costal cartilage on the right. The superior portion of this line—i. e., to the lower portion of the third intercostal space—corresponds to the mitral valve, while the inferior portion of this line corresponds to the tricuspid. Langer-Toldt adopt this line and place the middle of the tricuspid valve opposite the sternal end of the fifth costal cartilage. They show the valve extending from the middle of the fourth to the middle of the sixth costosternal junctions. Spalteholtz states that it lies behind the right half of the sternum at the level of the sternal end of the fourth intercostal space. According to Quain, it lies behind the sternum slightly to the left of the fourth intercostal space and the fifth costal cartilage. Cunningham says it lies obliquely behind the right half of the sternum at the level of the fourth and fifth cartilages and the intervening space. Piersol places it in the median line of the sternum on a level with the sternal end of the fifth costal cartilage. According to Debierre, the tricuspid valve lies opposite a line

which begins at the sternal end of the fourth left costal cartilage, extends obliquely downward and to the right, crosses the mid-sternal line opposite the fourth intercostal space, and ends at the chondrosternal articulation of the fifth right costal cartilage. Its extent ranges from 4 to 4.2 cm.

Pulmonary valve

The pulmonary valve in this subject lies at the level of the lower third of the sixth thoracic vertebra; in two, it lies at the level of the sixth thoracic disc; in one, at a level between the same disc and the upper third of the seventh thoracic vertebra; in one, at the level of the fourth thoracic disc; in one, at the level of the lower third of the fifth thoracic vertebra; in two, at a level between the lower third of the seventh thoracic vertebra and the seventh thoracic disc; in one, at the level of the lower third of the eighth thoracic vertebra.

The variations range from the fourth thoracic disc to the lower third of the eighth thoracic vertebra. The average position is at the level of the sixth thoracic disc.

With reference to the anterior thoracic wall, the pulmonary valve in this subject lies in the second left intercostal space, its center being about 1 cm. from the sternum.

According to Luschka, the pulmonary valve lies in the second left intercostal space; its center is near the left border of the sternum. Henke, and Engel place it somewhat lower at the level of the third left costal cartilage. Braune says it lies opposite the upper border of the third left costal cartilage .5 cm. from the sternum. Merkel places it opposite the upper portion of the third costal cartilage, with the center of the valve at the chondrosternal junction. Langer-Toldt, and Corning say that it lies opposite the third left chondrosternal junction. Quain places it immediately to the left of the sternum and opposite the third costal cartilage; Cunningham, opposite the upper border of third left chondrosternal junction; Morris, opposite the third left chondrosternal junction; Piersol, behind the sternal end of the third left costal cartilage. According to Debierre, the pulmonary orifice lies opposite a nearly transverse line which passes along the lower part of the second intercostal space and the upper margin of the third costal cartilage. The inner end of the line reaches, or extends slightly upon, the sternal margin. Its extent ranges from 2.2 to 2.5 cm.

Mitral valve

The mitral valve in this and one other subject lies at the level of the middle third of the eighth thoracic vertebra; in two, it lies at the level of the lower third

of the same vertebra; in one, at the level of the eighth thoracic disc; in one, at a level between the same disc and the upper third of the ninth thoracic vertebra; in one, at the level of the middle of the sixth thoracic vertebra; in one, at the level of the middle of the seventh thoracic vertebra; in one, at the level of the upper third of the tenth thoracic vertebra.

The variations range from the middle of the sixth to the upper third of the tenth thoracic vertebra. The average position is at the level of the middle of the eighth thoracic vertebra.

With reference to the anterior thoracic wall, the center of the mitral valve in this subject lies opposite the upper portion of the sternal end of the fourth left costal cartilage.

Joessel, Spalteholz, and Piersol state that it lies behind the sternal end of the left third intercostal space. According to Braune, its center lies opposite a point in the middle of the third left intercostal space 1 cm. from the sternum. Merkel and Langer-Toldt locate it as stated under the description of the tricuspid valve. Quain says that it lies slightly to the left of the auriculo-ventricular groove, and opposite the fourth costal cartilage and the adjacent part of the sternum. Cunningham places it behind the left half of the sternum at the level of the fourth rib. According to Debierre, it lies opposite a line which begins at the inferior border of the middle portion of the third costal cartilage, passes obliquely downward and to the right across the third intercostal space and the articulation of the fourth costal cartilage, and ends at or in the left margin of the sternum opposite the fourth intercostal space. Its extent ranges from 3.8 to 4 cm.

Aortic valve

The aortic valve in this subject lies at the level of the middle of the seventh thoracic vertebra; in two, it lies at the level of the seventh thoracic disc; in two, at a level between the same disc and the upper third of the eighth thoracic vertebra; in one, at the level of the fifth thoracic disc; in one, at the level of the middle third of the sixth thoracic vertebra; in one, at the level of the upper third of the eighth thoracic vertebra; in one, at the level of the upper third of the ninth thoracic vertebra.

The variations range from the fifth thoracic disc to the upper third of the ninth thoracic vertebra. The average position is at the level of the middle third of the seventh thoracic vertebra.

With reference to the thoracic wall, the aortic valve in this subject lies directly behind the sternum, opposite the lower portion of the second interspace and the third costal cartilage.

The aortic valve, according to Luschka, lies opposite a line which cuts obliquely the sternal extremity of the third intercostal space, in such a position that its right half is behind the sternum and its left half is behind the intercostal space. Braune says that the center of the aortic valve lies opposite the middle of the left half of the sternum at the level of the third costal cartilage. Merkel states that it begins behind the sternal extremity of the third right costal cartilage, from which point it extends to the left and downward until the mesial plane is reached. Langer-Toldt, and Corning say that it lies opposite the sternal end of the third intercostal space nearer the mid-plane than the pulmonary valve. Quain says it is behind the left half of the sternum at the level of the third costal cartilage; Cunningham, behind the left half of the sternum at the level of the lower border of the third left costal cartilage. Piersol locates it behind the left half of the sternum and a little below and to the right of the pulmonary valve, the two overlapping about one fourth their diameters. According to Debierre, the aortic valve lies opposite a line which begins at the middle of the third left costal cartilage near its sternal end, passes slightly downward and to the right, and ends in the mid-sternal line at the level of the inferior border of the third costal cartilage or the third intercostal space. Its extent ranges from 2.2 to 2.5 cm.

AORTA

Arch

The highest point of the arch of the aorta in this subject lies at the level of the upper third of the third thoracic vertebra; in one, it lies at the level of the second thoracic disc; in two, it lies at the level of the lower third of the third thoracic vertebra; in two, at a level between the lower third of the third thoracic vertebra and the third thoracic disc; in two, at the level of the third thoracic disc; in two, at the level of the middle third of the fourth thoracic vertebra; in one, at the level of the middle third of the fifth thoracic vertebra.

The variations range from the second thoracic disc to the middle of the fifth thoracic vertebra. The average position is at the level of the third thoracic disc.

The highest point of the arch of the aorta, according to Hildebrand, is opposite the third to the fourth thoracic vertebra; according to Morris, opposite the third thoracic vertebra. According to Merkel, and Piersol, it is on a level with the third thoracic spine. Cunningham says it is just below the second thoracic spine.

With reference to the anterior thoracic wall, the aortic arch in this subject is opposite the suprasternal notch. Piersol, and Morris place it about one inch below the suprasternal notch. Joessel places it on a level with the middle of the first costal cartilage.

Bifurcation

The bifurcation of the aorta in this subject lies at a level between the fourth lumbar disc and the upper third of the fifth lumbar vertebra; in two, it lies at the level of the fourth lumbar disc; in one, at the level of the upper third of the fifth lumbar vertebra; in one, at the level of the middle of the fifth lumbar vertebra; in one, at the level of the third lumbar disc; in two, at the level of the middle third of the fourth lumbar vertebra; and in three, at the level of the lower third of the same vertebra.

The variations range from the third lumbar disc to the middle third of the fifth lumbar vertebra. The average position is at the level of the lower third of the fourth lumbar vertebra.

Joessel, and Corning place the bifurcation opposite the lower portion of the fourth lumbar vertebra; Porier and Charpy, Cunningham, Morris, and Piersol say at the level of the fourth lumbar vertebra.

VENA CAVA SUPERIOR

Formation

The formation of the superior vena cava in this subject is at the level of the upper third of the third thoracic vertebra; in two, it lies at the level of the middle of the same vertebra; in one, at the level of the lower third of the same vertebra; in two, at a level between the lower third of the third thoracic vertebra and the third thoracic disc; in one, at the level of the third thoracic disc; in one, at the level of the second thoracic disc; in one, at the level of the upper third of the fourth vertebra; in one, at the level of the fourth thoracic disc.

The variations range from the second to the fourth thoracic discs. The average position is at the level of the lower third of the third thoracic vertebra. Morris places it opposite the third thoracic vertebra. With reference to the anterior thoracic wall it lies in this subject, behind the left sternoclavicular junction.

According to Luschka, Joessel, Langer-Toldt, and Morris, it lies at the sternal end of the first right costal cartilage. According to Corning it lies opposite the lower margin of the same or opposite the sternal end of the first intercostal space. Porier and Charpy, and Piersol state that it lies just below

the lower border of the sternal end of the first costal cartilage.

Cardiac orifice

The cardiac orifice of the superior vena cava in this subject lies at the level of the upper third of the seventh thoracic vertebra; in three, it lies at the level of the lower third of the same vertebra; in two, at the level of the seventh thoracic disc; in one, at the level of the upper third of the fifth thoracic vertebra; in one, at the level of the lower third of the sixth thoracic vertebra; in one, at the level of the upper third of the eighth thoracic vertebra; in one, at the level of the lower third of the same vertebra.

The variations range from the upper third of the fifth to the lower third of the eighth thoracic vertebra. The average position is at the level of the middle third of the seventh thoracic vertebra.

According to Porier and Charpy, it lies at the level of the sixth or the seventh thoracic vertebra. Morris places it at the level of the sixth thoracic vertebra.

With reference to the anterior thoracic wall, it lies in this subject opposite the sternal end of the second right intercostal space. Porier and Charpy state that it lies at the sternal end of the third costal cartilage, or just above the second intercostal space.

VENA CAVA INFERIOR

Formation

The formation of the inferior vena cava in this and four other subjects is at the level of the lower third of the fifth lumbar vertebra; in two, it lies at the level of the middle third of the same vertebra; in two, at the level of the fourth lumbar disc; in one, at a level between the fourth lumbar disc and the upper third of the fifth lumbar vertebra.

The variations range from the fourth lumbar disc to the lower third of the fifth lumbar vertebra. The average position is at the level of the middle third of the fifth lumbar vertebra.

Langer-Toldt places it at the level of the fourth lumbar vertebra; Corning, at the level of the lower part of the fourth lumbar vertebra or the fourth lumbar disc; Joessel, at the level of the fourth disc. Porier and Charpy, and Piersol place it at the fourth disc or the fifth lumbar vertebra. Cunningham, and Morris place it at the level of the fifth lumbar vertebra.

Cardiac orifice

The cardiac orifice of the inferior vena cava in this and one other subject lies at the level of the ninth thoracic disc; in three, it lies at the level of the

middle of the ninth thoracic vertebra; in one, between the lower third of the seventh thoracic vertebra and the seventh thoracic disc; in three, at the level of the middle third of the tenth thoracic vertebra; in one, at the level of the lower third of the same vertebra.

The variations range from the seventh thoracic disc to the lower third of the tenth thoracic vertebra. The average position is at the level of the lower third of the ninth thoracic vertebra. Porier and Charpy, and Morris place it at the level of the ninth thoracic vertebra. Cunningham locates it at the level of the seventh thoracic spine.

With reference to the anterior thoracic wall, it lies in this subject opposite the sternal end of the fourth right intercostal space.

UMBILICUS

The umbilicus in this subject lies at the level of the fourth lumbar disc; in one, at the level of the upper third of the fourth lumbar vertebra; in one, at the middle third of the same vertebra; in one, at the level of the third lumbar disc; in one, at the level of the middle third of the fifth lumbar vertebra.

The variations range from the third lumbar disc to the middle third of the fifth lumbar vertebra. The average position is at the level of the lower third of the fourth lumbar vertebra. Corning, and Morris place the umbilicus at the level of the third lumbar disc. Cunningham places it at the level of the middle of the fourth lumbar vertebra.

Table giving Vertebral Levels of Various Organs

TABLE GIVING VERTEBRAL LEVELS OF VARIOUS ORGANS

The table of levels given on the following page is based on the assumption that each vertebra is three times as thick as the corresponding disc, and that the differences in thickness between two contiguous vertebra is negligible. Each thoracic vertebra is designated by the letter "T" with a subscript to indicate its number in the series; each lumbar vertebra by the letter "L" with a subscript, and each sacral by the letter "S" with a subscript. The discs are indicated by the letter "D" with a subscript. The number of each disc is the same as that of the vertebra above it.

In the table each large horizontal space is subdivided into three parts to correspond to the three divisions of a vertebra. This method was adopted as a convenient and rapid way of recording the data. Thus, if the part of an organ being measured is at the level of the upper third of the sixth thoracic vertebra, the fact is recorded in full by placing a T

in the upper division of the space opposite the organ, and in the column corresponding to the particular body being measured. When the part is at the level of a disc, the D is placed in the middle division, as it would require an unnecessary amount of tabular space to have separate divisions for the discs. When the level of a part is on the dividing line between two of the above-named divisions of the vertebral column, the fact is readily indicated by making two entries in the table.

From the table the averages are easily computed. Thus T_7 in the third space and T_8 in the first space would be equivalent to $2D_7$. Again $2D_7$ and D_8 are the equivalents of $2T_8$ in the first space and T_8 in the second space. Many times it was impossible to reduce the entire eleven to a single value, necessitating two entries in the column of averages. In such cases the residual number is given within parentheses.

TABULATION OF VERTEBRAL LEVELS

	1	2	3	4	5	6	7	8	9	10	11	Average
STERNUM:	T3		T3									
Suprasternal notch.		T2	D2	D3	T3	T3	T4	D2	T3	T3	T2	T3
Manubrio-gliadiolar junction.				T6		T3						
	T5	D3	D5	D5	T5	T6		T5				
Xipho-sternal junction.			T5			T6	T6		T5	T5	T5	T5
				T10				T10				(T5)
Apex of xiphoid.	T10	D7	T9	T10	T10	T10	T11	T10	T9	D9	T10	T10
						T12	L1		T9			(T12)
	T12	D9	T11	T12	T12	D11		T11	T11	T11	T12	D11
INNOMINATE BONE:												
Crests of ilia.	L4	L4	D4		D4				L4	D4	D4	
	L4	L4	L4	L4		L4	L4	L4		L4	L4	L4
STOMACH:	T11	T9	T11			T11			T10			T11
Oesophageal orifice.		T9		T11	T11		T12	T11	D9	T10	T11	T11
Fundus.	D9	T8	T10	D9	T11	T10	D11	T10	T9	T10	T11	(T10)
								T10	T9			T10
Pylorus.	D1	D10	D1	D12	L2	L1	D2	L1	L1	L1	L2	L1
			L2					L1				L1
					L1			L1				L1
DUODENUM:	L1		L1		L1	D12	D1			D12	D1	D12
Superior portion.		T10	L1	T12					T12			
Transverse portion.	L4	L3	L4		D4		L4	L4	L3	D3	L4	L4
			D3			L3						
Duodeno-jejunal flexure.	L1	T11	L2		D2	L2	L2	L1		L1	L2	(D1)
									T12	L1	L1	L1
CÆCUM:		S3		D4	S1	S2	S2	S1	S1	S1	S2	D2
Lowest point.	S5		S3					D5	D5			
Ileo-cæcal valve.	S2		D4	D3	D4	L5		L5	D4	L5	D5	L5
		L5										
APPENDIX:	S3		S1	D3	D5	D5	D5			D5	S1	(D5)
Base.								L5	L5			L5
					L3				L2	L2		
COLON:	D2	D11	D2	L1	D2	D1		D2	D1	L2	D2	L2
Hepatic flexure.							L3					(T12)
Splenic flexure.	D11	D9			D1	L1	L2		T12	T12	D11	T12
			T12	T12			L2					
			L3	L3		L3	L4	L3				L3
PANCREAS:	D2	L2	L3	D2	D3				D2	D2	L3	
Head (lowest point).												
Body (highest point).		D9	D12		L1	T12		T12	T12	T12	L1	T12
	T11			T12			L1					
LIVER:	T10					D9	T11	T9	D8		D10	(D9)
Right lobe (highest point).		T7	D9	T9	T10					T9		T9
Right lobe (lowest point).	L4	L3	D3		D4	L3		D3	L3	L3	D4	D3
		L3	L3	L2		D2	L4	L3				L3
Anterior margin (mid-line).		T10		L1		D1	D2	D1	T12	T12	D1	(L1)
	D2				D2						L1	L1
		T12	L2							D2	D2	
GALL BLADDER:	D3		L3	D1	D2	D1		L3				
Lowest point.								D2	L1			L2
		T8	T10							T10		
SPLEEN:	D9	D7		T10	T11			D10	D9	T10	T11	
Highest point.						T10	T11					T10
Lowest point.	T12	D11	L1	L1	D1			L1	L1	L1		L1
						L1		L2	L1		L2	
	T5				T6		T7	T6	D4	T5	T6	(D5)
TRACHEA:												
Bifurcation.		T4	T5	T5	T6	T5						T5

TABLE GIVING VERTEBRAL LEVELS OF VARIOUS ORGANS.

TABULATION OF VERTEBRAL LEVELS

	1	2	3	4	5	6	7	8	9	10	11	Average
LUNG, RIGHT: Apex.	T1 D7	T1 D7	T1	T1	D1	D7		T1		T1 D7	D7	T1 (T1)
Base (lowest point, anterior margin).	D10	D9	T11	T11	T12	T11	T12	T10	D9	D10	T12	T11 (T11)
LUNG, LEFT: Apex.	T1 D7	T1 D7	T1	T1	T1		T1	T1	T1		T1	T1
Base (lowest point, anterior margin).	T10	T9	T11	T9	T11	D11	T12	T11	D9	T10	T11	D10 (T10)
KIDNEY, RIGHT: Superior extremity.	T12	T10	T12	D11	T12	L1	D12	T12 T12	T12	T11	T12	T12 (T12)
Inferior extremity.	L3	L3	D3 L3	D2	D3	D3	D3	L4		D2	L3	L3
KIDNEY, LEFT: Superior extremity.	D10	D9	T12 D11	T12	D12 T12	T12	T12	T12	D11	D11	D11	D11
Inferior extremity.	L3	D2	D3 L3	L3	D3	L3	D3	D3	D2	D2	L3	L3
SUPRARENAL, RIGHT: Apex.	T11		T11	T11	D11	D11	D11	T12			T12	(D11) T11
Lowest point.	L1		L1	D12	L1	L1	L1	L1	L1	L1	L1	L1
SUPRARENAL, LEFT: Superior margin.	T11		D11	T12	T12	D11	T12	D12	D11	T11	T12	T12 D11
Lowest point.	L1		D1	D1	L2	L1	L2	L2	L1	L1	L2	(D1) L1
HEART: Base (highest point).	T6 D5		T6			D6	T8	D6		D6 T6	T7	T6 T6
Apex.	D10	D8	T10			D10	D11	T11	D9	T10		T10 T9
Tricuspid valve.	D8	T7	D8 T8			T9	T10	T9	D7	D8		
Pulmonary valve.		D4	D6			D7	T8	D6		D6	D7	D6
Mitral valve.	T6	T6	T8			T7	T10	T9 D8	T5 T7		T7	
Aortic valve.	T8	T6	T8			T8	T9	T8		T8	D8	T8
AORTA: Arch.	T3	D2	D3 T3	T3	T4	T4	T5		D3	D3	D3	D3
Bifurcation.	L5 D4	L5	L4	L4	L4	L4	D4	L5	D3	L4	D4	(D4) L4
VENA CAVA SUPERIOR: Formation.	T3	D2	T3	D3 T3	T4	D3	D4	D3		T3		(D3) T3
Cardiac orifice.	T7	T5		D7				D7			T8	T7 (T7)
VENA CAVA INFERIOR: Formation.			T6 L5	T7	T7	T8				T7		
Cardiac orifice.	L5	L5	D4	D4	L5	L5	L5	L5		D4	L5	L5
UMBILICUS:	D9	D7 T7	T9	D9	T9	T10	T10	T10		T9	T10	(D9) T9

TABLE GIVING VERTEBRAL LEVELS OF VARIOUS ORGANS—Continued.

Illustration showing Organs at Average Vertebral Levels

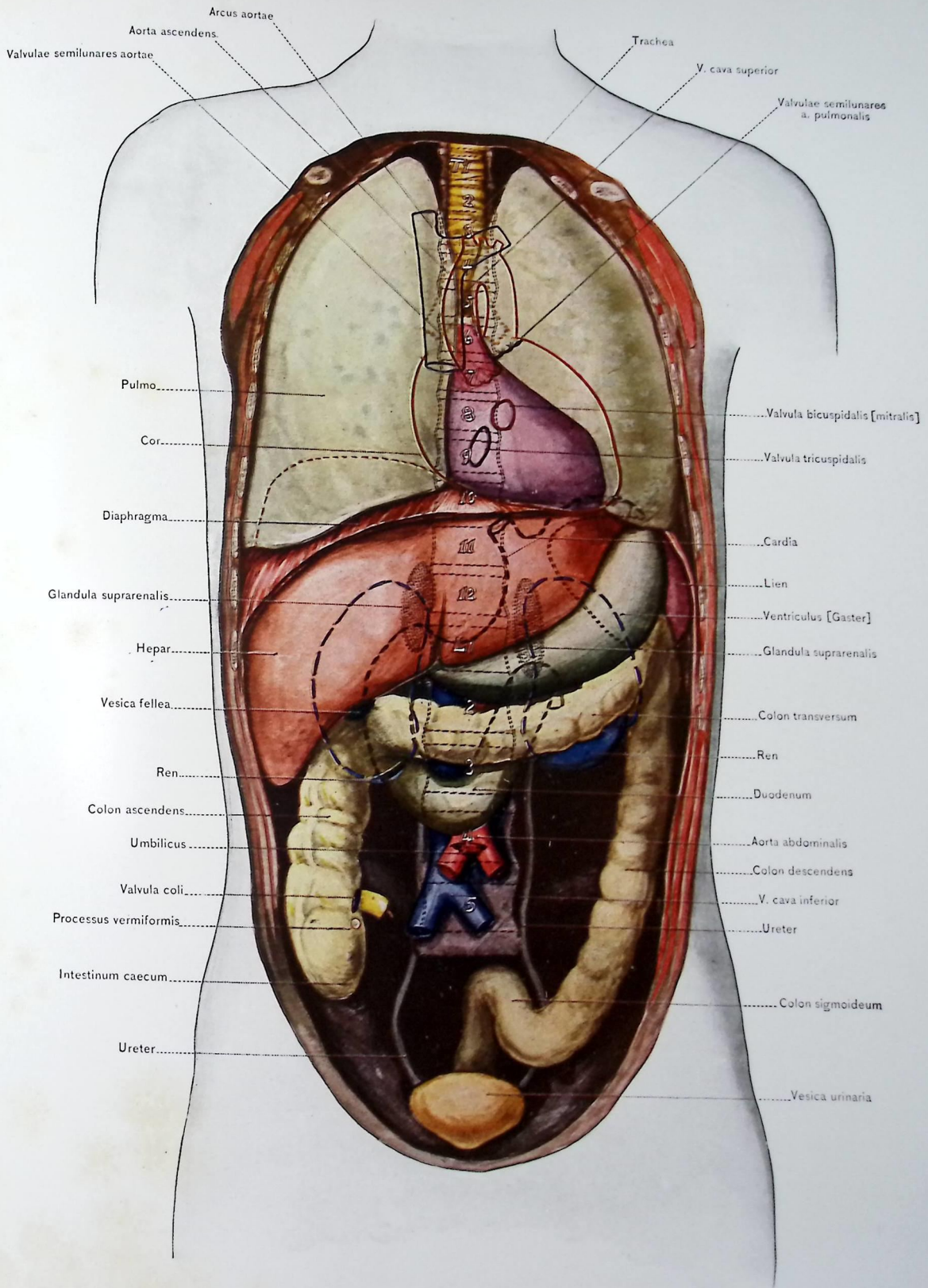
ILLUSTRATION SHOWING AVERAGE VERTEBRAL LEVELS OF PRINCIPAL ORGANS OF THE THORAX AND ABDOMEN

The illustration on the opposite page, showing the average vertebral levels of the principal organs of the thorax and abdomen, is built up largely from the preceding table. In order to obtain a body outline, measurements were taken through the middle of every third vertebra in each of the eleven bodies; these were then averaged and these averages form the basis for the body outline of the composite picture. In like manner the width and thickness of each vertebra and each intervertebral disc in each body were measured and the average determined. From the average measurements of the first thoracic in the eleven bodies, the extent of the first thoracic vertebra of the composite picture was obtained, and so on for each vertebra throughout the entire vertebral column.

In outlining the organs in the composite picture, the data given in the preceding table were supplemented by a large number of measurements from fixed and definite points, so that the position and profile of the organs are indicated as well as their vertebral levels.

The interpretation of the illustration will be facilitated by the following brief explanation. The uncovered portion of the stomach (ventriculus) is indicated by an olive green, while the contour of the covered portion is indicated by broken black lines. The position of the duodenum is indicated in the

same manner. The position of the appendix is so variable that no attempt has been made to indicate more than its base. The transverse colon and sigmoid colon are so variable that no attempt has been made to represent them except in a diagrammatic manner. The pancreas has been omitted for the sake of clearness. The highest portion of the liver (hepar), which is covered by the diaphragm and extends behind the lung, is indicated by the broken brick-red line. The fundus of the gall bladder (vesica fellea) is indicated. The uncovered portion of the spleen (lien) is of a purplish color; the profile of the portion lying behind the liver and stomach is indicated by a dotted line. The bifurcation of the trachea is indicated by dotted yellow lines. The right kidney is outlined by a heavy broken blue line. The lower portion of the left kidney is shown and its covered portion outlined in the same manner as the right. The bladder (vesica urinaria) is small, owing to the fact that in the cadaver it is usually empty. The suprarenal glands are shown by stippled areas. That portion of the heart which is not covered by the lungs is of a purplish color, while the remainder of its profile is shown by the heavy brick-red line. The aorta is indicated by a similar heavy line. The junction of the innominate veins to form the superior vena cava and the vena cava itself are outlined by a heavy blue line.



AVERAGE VERTEBRAL LEVELS OF THE PRINCIPAL ORGANS OF THE THORAX AND ABDOMEN.

BIBLIOGRAPHY

THE following list of references includes the more important books and special articles which have been consulted in preparing the present work:

- ADDISON, C. On the Topographical Anatomy of the Abdominal Viscera in Man. *Jour. of Anat. and Physiol.*, 1899-1901.
- AEBY, CHR. Ueber die Conservirung von Durchschnitten gefrorener Körpertheile. *Med. Centralbl.* N. 10. S. 150, 1875.
- BARDELEBEN, K. v. Handbuch der Anatomie des Menschen. Jena, 1896.
- BARTHOLIN, G. Institutiones anatomicae. Ed. T. Bartholin. 8° Ludg. Batav., 1641.
- BERAUD, B. J. Atlas complète d'anatomie chirurgicale topographique. 4° Paris, 1862-65.
- BIANCHI, S., e COCCHI, A. Sur rapports dell'albero bronchiale colla parete posteriore del torace. *Arch. Ital. de Biologie*, 1891.
- BIRMINGHAM, A., and THOMPSON, W. H. Distance of the Lower Border of the Kidney from the Iliac Crests in Male and Female Subjects. *Trans. Roy. Acad. Med.*, Ireland, 1891.
- BIRMINGHAM, A. The Topographical Anatomy of the Spleen, Pancreas, etc. *Jour. of Anat. and Physiol.*, 1896.
- BRAUNE, W. Topographisch-anatomischer Atlas. Nach Durchschnitten an gefrorenen Cadavern. Leipzig, 1872.
- BROOKS. Topographical Anatomy of the Abdomen. *The Lancet*, 1890.
- BRUN, A. v. Das Verhältniss der Gelenkkapseln zu den Epiphysen der Extremitätenknochen. Leipzig, 1881.
- CARMICHAEL, E. SCOOT. Preliminary note on the Position of the Gall-Bladder in the Human Subject. *Jour. of Anat. and Physiol.*, 1903.
- CAMPER, PETRUS. Demonstrationum anatomico-pathologicarum. Partes I. II. fol. La Haye, 1760-62.
- CHAMBERLAINE, JOHN. Imitations of Original Designs by Leonardo da Vinci. London, 1796.
- CHIEVITZ, J. H. Research on the Topographical Anatomy of the Full-term Human Fetus in situ. Copenhagen, 1899.
- CHOULANT. Geschichte der Anatomischen Abbildung. Leipzig, 1852.
- CORNING, H. Lehrbuch der Topographischen Anatomie. Wiesbaden, 1910.
- CRAIG, A. S. Atlas of Sectional Anatomy. Marysville, Mo., 1907.
- CUNNINGHAM, D. J. Text-book of Anatomy. New York, 1909.
- DE RIEMER, P. Exposition de la position exacte des parties internes du corps humain, tant par rapport à leur position mutuelle, que par leur contact aux parois des cavités où elles se trouvent placées; avec une description explicative y relative. La Haye, 1818.
- DEAVER, J. B. Surgical Anatomy. Philadelphia, 1899-1903.
- DEBIERRE, CH. La projection des orifices du cœur sur la paroi thoracique. *Jour. de l'Anat. et Physiol.*, 1908.
- ENGEL, J. Compendium der topographischen Anatomie. Wien, 1859.
- DWIGHT, T. Notes on the Duodenum. *Jour. Anat. and Physiol.*, 1897.
- FAWCETT, E., and BLACHFORD, J. Some observations on the Level at which the Lower Border of the Third Part of the Duodenum crosses the Vertebral Column. *Jour. Anat. and Physiol.*, 1904.
- FLUDD, R. Anatomia amphitheatrum effigie triplici, more et conditione varia, designatum. Francfort, 1633.
- FROMONT, H. Contribution à l'anatomie topographique de la portion sous-diaphragmatique du tube digestif. *Thèse.* Lille, 1890.
- FRORIEP, L. F. v. Ueber Anatomie in Beziehung auf Chirurgie. Nebst einer Darstellung der relativen Dicke und Lage der Muskeln am Ober- und Unterschenkel. Weimar, 1813.
- Ueber die Lage der Eingeweide im Becken, nebst einer neuen Darstellung derselben. Weimar, 1815.
- GEGENBAUR, C. Lehrbuch der Anatomie des Menschen. Tübingen, 1876.
- GERHARDT, C. Lehrbuch der Auscultation und Percussion. Tübingen, 1876.
- GERLACH, J. v. Handbuch der speciellen Anatomie des Menschen. München, 1891.
- GEROTA, D. Ueber die Anwendung des Formols in der Topographischen Anatomie. *Anat. Anz.*, 1895.
- GIACOMINI, C. Topographia del cuore. Torino, 1886.
- GRAAF, R. DE. Opera omnia. Leyde, 1667.
- HALLER, A. Icones anatomicae quibus praecipuae aliquae partes corporis humani continentur. Göttingen, 1743-56.
- HELM, FR. Beiträge zur Kenntniss der Nierentopographie. *Inaug. Diss.*, Berlin, 1895.
- Zur Topographie der Menschlichen Nieren. *Anat. Anz.*, 1896.
- HEWSON, A. The Anatomy of the Vermiform Appendix. *Am. Jour. Med. Science*, 1893.

- JACKSON, C. M. A Method of Teaching Regional Anatomy. *Jour. of the Am. Med. Assn.*, 1901.
- Orientation of Figures in Topographical Anatomy. *Anat. Anz.*, 1901.
- JOESSEL, G., und WALDEYER, W. Lehrbuch der topographisch-chirurgischen Anatomie mit Einschluss der Operationsübungen an der Leiche. Bonn, 1884-99.
- KOHLRAUSCH. Zur Anatomie und Physiologie der Beckenorgane nebst naturgetreuer Abbildung der Längsdurchschnitte des Männlichen und Weiblichen Beckens. Leipzig, 1854.
- KUPFFER, C. v. Nicolaus Rüdinger. *Anat. Anz.*, 1897.
- LANGER, C. v., und TOLDT, C. Lehrbuch der Systematischen und Topographischen Anatomie. Wien und Leipzig, 1897.
- LE GENDRE, E. Anatomie chirurgicale homologique, ou description et figures des principales régions du corps humain représentées de grandeur naturelle d'après des sections planes pratiquées sur les cadavres congelés. fol. Paris, 1858.
- LIZARS, A. A System of Anatomical Plates of the Human Body. Edinburgh, 1824.
- LUSCHKA, H. Die Brustorgane des Menschen in ihrer Lage. fol. Tübingen, 1857.
- Die Lage der Bauchorgane des Menschen. Karlsruhe, 1873.
- MACEWEN, W. Atlas of Head Sections. Glasgow, 1893.
- MALL, F. P. On the Teaching of Anatomy. *Anatomical Record*, 1908.
- MASCAGNI, P. Anatomia universale, per Antonio Serantoni. fol. Firenze, 1838.
- MEHNERT, E. Ueber Topographische Altersveränderungen des Atmungsapparates. Jena, 1901.
- MERKEL, F. Handbuch der Topographischen Anatomie. Braunschweig, 1885-1907.
- MORRIS, H. Human Anatomy. Philadelphia, 1907.
- PANSCH, A. Sägeschnitt-Modelle des Menschlichen Körpers. Kiel, 1876.
- Anatomische Vorlesungen für Aerzte und ältere Studierende. Theil I. Brust und Wirbelsäule. Berlin, 1884.
- PIERSOL, G. Human Anatomy. Philadelphia and London, 1907.
- PIROGOFF, N. Anatome topographica sectionibus per corpus humanum congelatum triplici directione ductis illustrata. Petropoli, 1852-59.
- PLACENTINUS, G. Nova anatomia organorum sensilium. 1612.
- POISSON, P., et CHARPY, A. Traité d'anatomie humaine. Paris, 1899-1901.
- POTTER, P. Topography of the Thorax and Abdomen. University of Missouri Studies, Columbia, Mo., 1905.
- QUAIN, J. Elements of Anatomy. Ed. by Schäfer and Thane. London and New York, 1896.
- RAUBER, A. Lehrbuch der Anatomie des Menschen. Leipzig, 1898.
- RAYNAL, J. Recherches sur la vesicule biliaire. *Thèse*, Toulouse, 1894.
- ROSENMÜLLER, J. C. Handbuch der Anatomie des menschlichen Körpers zum Gebrauch der Vorlesungen ausgearbeitet. Leipzig, 1819.
- RÜDINGER, A. Topographisch-chirurgische Anatomie des Menschen. Stuttgart, 1873-79.
- Cursus der Topographischen Anatomie. München, 1899.
- SANDRAS, L. Contribution à l'étude de la topographie et de la chirurgie du pancréas. *Thèse*, Lyon, 1897.
- SAPPEY, PH. C. Traité d'anatomie descriptive. Paris, 1876-79.
- SCHRÖDER, K. Der schwangere und kreisende Uterus. Bonn, 1886.
- SCHULTZE, O. Topographische Anatomie. München, 1903.
- SELLHEIM, H. Der Normale Situs der Organe im Weiblichen Becken, und ihre Häufigsten Entwicklungshemmungen, auf Sagittalen, Queren und Frontalen Serienschnitten. Wiesbaden, 1903.
- SIRAUD. Notes sur l'anatomie de la vesicule biliaire. *Lyon Medicate*, 1895.
- SOBOTTA, J. Atlas and Text-book of Human Anatomy. Ed. J. P. McMurrich. Philadelphia and London, 1909.
- SOEMMERING, S. Dissertatio de basi encephali et originibus nervorum cranio egredientium. Göttingen, 1778.
- SOEMMERING, G. De oculo hominis animaliumque sectione horizontali. fol. 1819.
- SPALTEHOLZ, W. Hand-Atlas of Human Anatomy. Translated by L. F. Barker. Philadelphia, 1898-1906.
- SPIEGHEL, A. De humani corporis fabrica libri X. Venise, 1627.
- SYMINGTON, J. The Topographical Anatomy of the Child. Edinburgh, 1887.
- A Comparison of the Pelvic Viscera and the Pelvic Floor in Two Adult Subjects. *Journ. Anat. Phys.*, B. 34 S. 101-110. 2 Fig.
- TERRY, R. J. A Method of Sectioning the Whole Decalcified Body with a Knife. *Proc. Assn. Am. Anatomists*, 1900.
- TESTUT, L., et JACOB O. Précis d'anatomie topographique. Paris, 1907.
- TOLDT, C. Anatomischer Atlas. Berlin and Wien, 1900.
- TREVES, F. Applied Anatomy. Philadelphia, 1901.
- TSCHAUSSOW, M. Bemerkungen ueber die Lagerung der Bauchspeicheldrüse. *Anat. Anz.*, 1895.
- TUNIS, J. P. A Method of Polishing Frozen Sections. *Anatomical Record*, 1909.
- VESALIUS, ANDREAS. De humani corporis fabrica libri septem. fol. Basilea, 1543.
- VESLING, J. Syntagma anatomicum, publicis dissectionibus in auditorum usum aptatum. Padoue, 1641.
- VICQ D'AZYR, F. Traité d'Anatomie. 1786.
- VIDIUS, G. De anatome corporis humani. Venetiis, 1611.
- WEBER, W., and WEBER, E. Mechanik der menschlichen Gehwerkzeuge. 1836.
- WEILL. Handbuch der topographischen Percussion. Leipzig, 1880.
- WIART, P. Recherches sur la forme et les rapports du pancréas. *Jour. de l'anatomie*, 1899.
- Recherches sur l'anatomie du cholédoque. *Revue de gynécologie*, 1899.
- ZUCKERKANDL, E. Nothnagel's specielle Pathologie. 1899.

Indices

INDEX TO BNA TERMS

This index consists of alphabetically arranged BNA terms. In all cases where these terms differ essentially from those currently used an equivalent English term has been given in *italics*. Certain features of the index need a word of explanation—e. g., under the general head "Capsula interna," we have given its subdivisions, namely: genu, pars frontalis; pars occipitalis. The terms, as given in the indices of Krause, Toldt, Spalteholz, and others, read: Genu capsulae internæ; Pars frontalis capsulae internæ; Pars occipitalis capsulae internæ. In all cases of this kind cross references have been given from the former terms to the latter terms. Occasionally we have added the qualifying term [ramus] or [rami] to unnamed branches of arteries, veins, or nerves. In the index both angular brackets [] and parentheses () are used. The BNA terms within angular brackets are explanatory additions; those within oval brackets or parentheses are anatomical variations. When a synonymous BNA term is given it is within brackets, begins with a capital letter, and is in the nominative case. The tendons of muscles have not been included in the index, since they are not recognized in the BNA except as parts of muscles.

The larger numerals in the index cite the number of the section, while the smaller numerals cite the particular leader where the structure in question may be found.

- Acetabulum, 40⁵⁵, 46⁴³.
 Ala magna ossis sphenoidalis, 6¹⁴, 7²¹, 8²³⁻⁷², 10⁷¹.
 Ampulla recti, 41³⁶, 47²⁹, 48²⁴.
 Angulus inferior scapulae, 25³⁰.
 Antrum tympanicum (*mastoid antrum*), 9³⁴.
 Anus, 43³⁸, 49²¹.
 Aorta abdominalis, 31³⁸, 32³⁹, 33³³, 34³⁸.
 — ascendens, 23¹⁰², 24².
 — descendens, 23⁹⁹.
 — thoracalis, 24⁴⁷, 25⁴⁸, 26⁴⁶, 27⁴⁶, 28⁴⁰, 29⁴³, 30⁵¹.
 Aponeurosis palmaris (*palmar fascia*), 7²², 7³².
 — plantaris (*plantar fascia*), 109¹⁴, 110¹⁴, 111¹², 112¹², 113⁹.
 Appendices epiploicae, 34⁵⁻¹⁰⁻⁶⁷⁻⁶⁸, 36¹⁴, 37⁵⁷.
 Aquæductus cerebri [Sylvii] (*aqueduct of Sylvius*), 7⁴⁶, 8⁴⁴.
 Arachnoidea encephali (*arachnoid of brain*), 17, 29, 6⁹⁰.
 Arcus aortæ (*arch of aorta*), 23⁹⁹.
 — plantaris (*plantar arch*), 111²⁷.
 — posterior atlantis (*posterior arch of Atlas*), 13³⁷.
 — tendineus m. levatoris ani (*white line of pelvis*), 47¹⁴⁻⁴⁴.
 — volaris arteriosus profundus (*deep palmar arch*), 72¹⁹.
 Arteria angularis, 8⁸⁹, 11⁹¹.
 — anonyma (*innominate artery*), 22¹.
 — auricularis posterior, 12⁴⁷.
 — axillaris, 22¹⁹⁻⁸¹, 23²³⁻⁸³.
 — basilaris, 8²⁹, 9²⁴, 10²⁹.
 — brachialis, 50⁹, 51⁸, 52⁷, 53⁶, 54², 55², 56¹, 57¹, 58¹, 59².
 Arteria bronchialis, 24²⁹⁻⁴⁵⁻⁵¹, 25²⁸, 26⁵³.
 — carotis communis, 18¹⁰⁻⁵⁰, 19¹⁰⁻⁵⁵, 20⁷⁻⁶⁹, 21⁴⁻⁷⁹.
 — carotis externa, 12¹⁹⁻⁵¹, 13¹⁷⁻⁵⁰, 14²³⁻⁵⁹, 15¹⁴⁻⁴⁸, 16¹⁶⁻⁴⁵, 17¹⁴.
 — carotis interna, 8⁶⁹, 9¹⁷⁻⁷⁷, 10²¹⁻⁶⁵, 11²⁷⁻⁷³, 12¹⁸⁻⁵¹, 13⁵¹, 14²⁶⁻⁵⁶, 15⁴⁵, 16¹⁸⁻⁴³, 17¹⁷⁻⁵⁰.
 — cerebelli inferior anterior, 9³⁶.
 — cerebelli superior, 7⁴⁴.
 — cerebri anterior, 7².
 — cerebri media, 5¹⁵, 6¹⁵, 7²², 8³⁸⁻⁶⁹.
 — cerebri media [ramus], 1¹¹, 2⁶, 3¹⁰⁻¹⁴, 6⁶⁷.
 — cerebri posterior, 8⁵⁵.
 — cervicalis ascendens (*ascending cervical artery of inferior thyroid*), 20⁸.
 — cervicalis profunda (*deep cervical artery*), 17²⁹, 18³⁸, 19²⁴⁻⁴⁴.
 — circumflexa femoris lateralis (*external circumflex*), 43⁵⁷, 47⁹, 48¹⁰, 49⁹.
 — circumflexa femoris lateralis [ramus descendens]. See RAMUS.
 — circumflexa femoris medialis (*internal circumflex*), 47¹⁰⁻⁴⁷, 48¹⁴⁻³³.
 — circumflexa femoris medialis [ramus], 49¹⁴⁻²⁸.
 — circumflexa humeri anterior (*anterior circumflex*), 22³⁰.
 — circumflexa humeri posterior (*posterior circumflex*), 22²⁶⁻⁸⁰, 23³⁰.
 — circumflexa ilium profunda, 37¹⁴, 38⁵⁹, 39¹¹, 45¹⁰⁻⁶¹.
 — circumflexa ilium superficialis, 45¹⁰, 46⁷, 47⁸⁻⁵¹.
 — circumflexa scapulae (*dorsalis scapulae*), 23³³⁻⁷⁶⁻⁷⁸.
 Arteria colica dextra, 34¹¹, 35¹⁵, 36¹⁶, 37¹⁵, 38¹⁴.
 — colica sinistra, 31⁵³, 32⁵², 33⁵⁰.
 — collateralis media (*median collateral branch of superior profunda*), 52¹², 53¹³.
 — collateralis radialis (*articular branch of superior profunda*), 52¹⁵, 53¹⁵, 54¹², 55¹¹.
 — collateralis ulnaris inferior (*anastomotica magna*), 59¹.
 — collateralis ulnaris superior (*inferior profunda*), 52⁸, 53⁸, 54⁷.
 — communicans posterior cerebri, 8⁹².
 — coronaria cordis dextra (*right coronary of heart*), 25², 26⁴, 27⁷.
 — coronaria cordis sinistra (*left coronary of heart*). See RAMUS.
 — cystica, 31¹⁵.
 — digitalis volaris communis (*palmar digital*), 74¹⁻⁴⁻⁷⁻²⁵, 75¹.
 — dorsalis pedis, 108²³, 109¹, 110⁹.
 — dorsalis penis, 42¹.
 — epigastrica inferior (*deep epigastric*), 36⁴, 37⁴, 38⁶⁸, 39⁵⁻⁷⁰, 40⁹⁻⁶⁴, 45⁸.
 — epigastrica superficialis, 45⁷⁻⁶⁶, 46⁹, 47⁷⁻⁵².
 — epigastrica superior, 29⁷⁸, 30⁵.
 — femoralis, 41³⁻⁶³, 42⁶⁹, 43⁶⁹, 44²⁹, 46⁸⁻⁵¹, 47⁴⁹, 48³⁰⁻⁴⁰, 49⁷⁻³⁴, 76¹, 77², 78², 79³, 80³, 81⁴, 83⁵, 84², 85⁴.
 — frontalis, 5¹, 7⁹⁸, 8⁸⁸.
 — frontalis [ramus], 3³⁻⁴⁰, 4².
 — gastrica brevis (*vasa brevia*), 28⁵².
 — gastrica dextra (*pyloric*), 31⁶⁴⁻⁷³, 32⁶⁵.
 — gastrica dextra [ramus], 31⁶⁴.
 — gastrica sinistra (*coronary artery*), 29⁵⁶⁻⁶⁴⁻⁶⁸, 30⁸².

- Arteria gastrica sinistra [ramus], 30⁷⁸.
 — gastroduodenalis, 31¹¹, 32¹.
 — genu inferior medialis (*inferior inter-articular*), 92⁸.
 — genu suprema (*anastomotica magna*), 86³, 88⁴, 89⁵.
 — glutæa inferior (*inferior branch of glutæa*), 40²⁸⁻⁴¹, 41²³⁻²⁹⁻⁴⁷, 42³⁰⁻⁵⁰, 43²⁸⁻⁴⁶, 45²⁷⁻⁴⁶, 46¹⁹, 47¹⁹⁻³⁹, 48³⁰.
 — glutæa superior (*sciatic*), 39²⁴⁻⁴⁸⁻⁴⁹.
 — hæmorrhoidalis inferior, 48²¹⁻²⁹.
 — hæmorrhoidalis media, 45²⁸⁻⁴⁸, 46²³⁻³⁷.
 — hæmorrhoidalis superior (*glutæa*), 35⁹, 36⁹, 37¹⁰, 38⁹, 39⁸, 45²⁴⁻⁴¹, 46²³⁻³⁴.
 — hepatica, 30⁴.
 — hypogastrica (*internal iliac*), 37²⁹⁻⁴⁵, 38²²⁻³², 39²⁴⁻³⁴.
 — ilea (*vasa intestini tenuis*), 35⁵, 36²⁻⁶⁶.
 — ileocolica, 35¹⁹, 36⁹, 37⁹, 38¹⁹.
 — iliaca communis, 35²⁸, 36²⁸⁻⁴⁹.
 — iliaca externa, 37¹⁹⁻⁴³, 38¹⁷⁻⁵⁶, 39¹³⁻³⁹, 40¹¹⁻⁶², 45¹¹.
 — iliolumbalis, 35³²⁻³⁷, 36¹⁴, 38²²⁻⁴⁹.
 — iliolumbalis [ramus], 37²².
 — infraorbitalis, 10⁷².
 — intercostalis, 21⁹, 22⁴¹, 23²⁶, 24³⁸, 25²⁵⁻⁴⁵, 26¹⁸⁻³¹⁻³⁶⁻⁴⁸, 27²³⁻²⁷⁻⁴⁰⁻⁴⁴⁻⁵⁰, 28²⁹⁻³⁶⁻⁴³, 29¹⁰, 30¹⁶⁻⁵².
 — interossea communis, 61⁹.
 — interossea dorsalis antibrachii (*posterior interossea*), 62¹⁹, 63¹⁴, 64¹², 65¹², 66¹².
 — interossea volaris (*anterior interossea*), 62², 63²⁸, 64¹³, 65²³, 66¹⁴.
 — jejunalis (*vasa intestini tenuis*), 33⁶¹, 34⁵⁶⁻⁵⁷, 35⁵²⁻⁵⁴, 36⁶², 37⁶².
 — lacrimalis (*lachrymal*), 87³.
 — lienalis (*splenic*), 29⁵⁸, 30⁷¹.
 — lingualis, 167³³.
 — lumbalis, 31³⁵.
 — mammaria interna, 21⁸, 22⁶⁻⁹⁴, 24⁴, 25³, 26³⁻⁷⁴, 27⁴, 28³⁻⁷⁷.
 — maxillaris externa (*facial*), 14¹⁰⁻⁶⁹, 15⁸⁻⁴⁹, 16¹¹⁻⁴⁹.
 — maxillaris externa [rami], 17⁵⁸.
 — maxillaris interna, 10⁵, 11¹⁶⁻⁸⁸.
 — meningea media, 5¹¹, 6¹⁷⁻⁷⁰, 9²¹, 10¹⁶⁻⁶⁵, 11²⁴⁻⁷⁵.
 — meningea media [ramus], 27³, 31⁴, 41².
 — mesenterica inferior, 33³⁸, 34³⁴.
 — mesenterica superior, 31¹⁰, 32⁶¹, 33⁵³, 34⁶⁴.
 — mesenterica superior [rami], 32⁶⁰.
 — metacarpea dorsalis (*dorsal interossea*), 73²³.
 — metacarpea volaris (*palmar interossea*), 72²³.
 — metatarsæ dorsalis (*dorsal interossea*), 111¹.
 — metatarsæ plantaris (*digital branch of external plantar*), 111¹⁷, 112⁹⁻¹³.
 — musculophrenica, 29⁷⁶.
 — obturatoria, 41¹⁹⁻⁶⁰, 42⁶⁷, 45¹⁵⁻³⁴, 46¹¹, 47³⁹, 48¹².
 — Arteria (obturatoria), 40⁹⁻⁶⁴.
 — occipitalis, 6²⁷, 7⁴⁷, 8⁴³, 10²³, 11⁴⁰, 12¹⁴, 13²⁰, 15¹⁶.
 — occipitalis [ramus], 31⁸, 11⁴⁵⁻⁵⁵.
 — occipitalis [ramus descendens] (*princeps cervicis*). See RAMUS.
 — ophthalmica, 87²⁸⁻³².
 — ovarica, 45¹³⁻⁵⁵.
 — palatina descendens, 11³⁹.
 — pancreatoduodenalis [rami], 32¹³.
 — perforans prima (*first perforating of profunda*), 42²²⁻⁶², 43²⁵⁻⁵⁰, 44⁸, 76¹⁸.
 — perforans prima [ramus], 77¹⁹.
 — perforans secunda, 79¹⁰.
 — perforans tertia, 81¹⁰, 82⁹.
 — pericardiacophrenica (*superior phrenica*), 23⁵, 24¹⁰⁻⁶⁸, 26¹⁵⁻⁶⁵, 27¹⁹⁻⁷¹, 28⁶⁸, 99¹², 100¹², 101¹³, 102¹⁵, 104¹⁵.
 — phrenica inferior, 28²³⁻³³, 29³⁰⁻³², 30⁷⁷.
 — plantaris lateralis (*external plantar*), 108¹¹, 109¹⁵, 110¹⁸.
 — plantaris medialis (*internal plantar*), 108⁹, 109¹¹, 110¹².
 — poplitea, 86⁷, 87¹⁰, 88², 89¹³, 90¹⁵, 91¹⁸, 92⁹, 93¹².
 — profunda brachii (*superior profunda*), 50¹⁹, 51¹⁰.
 — profunda femoris, 41⁶², 42¹⁷⁻⁶⁷, 43¹⁹⁻⁵⁶, 44¹⁵, 48³⁹, 49³⁻³³, 76³⁰, 77²³, 78²², 79⁹, 80¹³, 81¹, 82¹⁴, 83¹⁶.
 — profunda lingue (*ranine*), 15³.
 — profunda lingue [ramus dorsalis], 13⁴.
 — profunda penis (*artery of corpus cavernosum*), 43².
 — pudenda interna (*internal pudic*), 40²⁵⁻⁴⁶, 41²⁷, 42³⁴, 45²⁵⁻⁴⁸, 46²¹, 47³⁷.
 — pulmonalis, 24⁷¹.
 — pulmonalis [ramus], 25¹⁸⁻⁵⁸, 26²⁰, 27³¹.
 — pulmonalis [ramus dexter]. See RAMUS.
 — pulmonalis [ramus sinister]. See RAMUS.
 — radialis, 60³⁹, 61²⁹, 62²⁷, 63²⁶, 64²², 65²⁰, 66²³, 67²², 68²², 69²¹, 70²⁹, 71²¹.
 — recurrens radialis, 58¹⁸, 59²⁵, 60²⁹.
 — recurrens ulnaris, 58⁹, 59¹³, 60¹².
 — renalis, 30⁶², 31²⁷⁻⁴⁶, 32²².
 — renalis [ramus], 29³⁷, 30³⁴⁻⁶⁴⁻⁶⁶, 31⁴²⁻⁵⁰.
 — sacralis lateralis, 38³¹, 39³², 40²¹, 41²⁵, 45²⁸.
 — sacralis media, 36⁴³, 37²⁶, 38⁴², 45³⁶.
 — sigmoidea, 35⁴², 36⁶³, 37⁵⁹⁻⁶⁸.
 — sigmoidea [rami], 38³⁷, 40³³.
 — spermatica interna (*spermatic*), 33¹⁴⁻⁴⁷, 34²¹⁻⁴⁹, 35²²⁻⁴⁸, 36³⁶, 37¹⁶, 38¹⁵⁻⁶⁰.
 — sphenopalatina, 10⁷.
 — subclavia, 21⁸, 22⁹⁷.
 — submental, 167³⁴.
 — suprarenalis inferior (*suprarenal branch of renal*), 29³⁰.
 — Arteria tarsea lateralis (*external tarsal*), 107²⁰.
 — temporalis profunda anterior, 10⁹⁷.
 — temporalis profunda posterior, 10⁹⁷.
 — temporalis superficialis, 6²⁹, 7²⁹, 8³⁰, 9²⁸⁻⁶⁵, 10¹⁹⁻⁶¹, 11²⁶⁻⁷⁴.
 — temporalis superficialis [ramus], 1⁹, 2³, 3¹¹, 4¹⁵⁻¹⁷.
 — thoracalis lateralis (*long thoracic*), 22⁸⁵, 23¹⁶⁻⁸⁷, 27²²⁻⁶².
 — thoracodorsalis (*subscapular*), 23³⁰⁻⁷³, 24²²⁻⁵⁷, 26²².
 — thyreoidea inferior, 20⁶¹⁻⁶¹.
 — thyreoidea superior, 17¹¹, 18³².
 — tibialis anterior, 94¹⁵, 95¹³, 96¹⁷, 97¹⁷, 98¹⁵, 99², 100¹³, 101¹, 102³, 103¹³, 104¹⁹, 105¹⁸, 107²².
 — tibialis posterior, 94⁵, 95⁵, 96⁴, 97⁵, 98⁴, 99⁵, 100⁵, 101⁷, 102⁷, 103⁶, 104⁶, 105⁷, 106⁷, 107².
 — transversa colli (*transversalis colli*), 20²⁵.
 — transversa colli (*superficial cervical*) [ramus ascendens]. See RAMUS.
 — transversa colli (*posterior scapular*) [ramus descendens]. See RAMUS.
 — transversa scapulæ (*suprascapular*), 21²³.
 — ulnaris, 60², 61⁷, 62⁶, 63⁶, 64⁵, 65⁵, 66⁴, 67³, 68⁴, 69³, 70⁴, 71⁵, 72⁴.
 — ulnaris [ramus volaris profundus]. See RAMUS.
 — umbilicalis, 45¹².
 — uterina, 45¹⁹⁻²⁰⁻⁵³.
 — vaginalis, 45²³, 46¹², 47¹⁶.
 — vertebralis, 11⁴²⁻⁶⁰, 12³⁹, 13²⁵⁻⁴⁷, 14²²⁻⁵⁰, 15³⁸, 16²³, 17²⁵⁻⁴³, 18⁴⁷, 19¹³⁻⁵², 20¹⁰⁻⁵⁹.
 — vesicalis inferior, 40²⁷⁻⁴⁵.
 Articulatio sacroiliaca, 37⁴³, 39²⁹.
 Atlas, 12²⁶.
 Atrium dextrum (*right auricle*), 26⁷, 27⁸.
 — sinistrum (*left auricle*), 25¹⁴, 26⁹¹.
 Auricula dextra (*right auricular appendix*), 25⁶.
 Axilla, 22⁶, 23¹⁸⁻⁸⁵.
 Basis pedunculi cerebri (*crusta of cerebral peduncle*), 73¹.
 — prostata, 42¹³.
 Brachium conjunctivum cerebelli (*superior cerebellar peduncle*), 81¹, 91⁴⁻⁹.
 — pontis, 93⁸⁻⁵², 10¹⁸.
 Bronchus dexter, 24²⁶, 25²⁵.
 — sinister, 24²⁰, 25²⁷.
 Bulbus olfactorius, 83².
 — urethre, 43³⁹.
 Bulla ethmoidalis, 9⁶.
 Bursa asnerina, 93⁴.
 — iliopectinea, 40¹⁴.
 — m. coracobrachialis, 21¹⁸.
 — m. gastrocnemii medialis, 89⁹.
 — m. latissimi dorsi, 22²², 23²⁵.

- Bursa m. semimembranosi, 9¹².
 — omentalis (*lesser peritoneal sac*), 28³⁸, 29⁵⁶⁻⁶⁷, 30⁸³, 31⁶².
 — præpatellaris subcutanea, 90¹.
 — subcutanea calcanea, 106¹⁹.
 — subcutanea olecrani, 59¹⁶.
 — subdeltoidea, 20¹⁵, 21²⁰.
 — suprapatellaris, 88¹⁸.
 — trochanterica m. glutæi maximi, 41²⁰⁻⁵⁴, 42²⁴.
- Calcaneus (*os calcis*), 107¹², 108¹⁵, 109¹⁹.
 Calcar avis (*hippocampus minor*), 7³⁸⁻⁶².
 Calyx renalis major, 31²⁸.
 Camera oculi anterior (*anterior chamber of eye*), 8¹³, 9⁸⁵.
 Canalis adductorius [Hunteri] (*Hunter's canal*), 84⁶.
 — incisivus, 12².
 — sacralis, 38³⁸.
 — semicircularis superior, 9³³.
 Capitulum fibulae, 92¹⁶.
 — mallei, 9²¹.
 — ossis metacarpalis, 74¹⁰⁻¹³⁻¹⁷⁻²¹.
 — ossis metatarsalis, 112¹⁹, 113³.
 Capsula externa nuclei lentiformis (*external capsule of brain*), 5¹⁴, 6¹¹⁻⁷⁵, 7⁷⁵.
 — interna nuclei lentiformis (*internal capsule of brain*), 5¹⁶, 7³¹⁻⁷⁴.
 — interna nuclei lentiformis [genu]. See GENU.
 — interna nuclei lentiformis [pars frontalis]. See PARS.
 — interna nuclei lentiformis [pars occipitalis]. See PARS.
 Caput angulare m. quadrati labii superioris (*m. levator superioris alæque nasi*), 9⁴.
 — breve m. bicipitis brachii, 22²¹⁻⁷⁹, 23⁸¹, 50³, 51¹, 52²².
 — breve m. bicipitis femoris, 81¹⁷, 82¹², 84¹⁴.
 — femoris, 40⁵⁶, 41⁵⁷, 46¹²⁻⁴⁵.
 — humeri, 21²¹⁻⁶⁰.
 — infraorbitale m. quadrati labii superioris (*levator labii superior*), 12⁷⁻⁶⁵.
 — laterale m. gastrocnemii, 90²³, 91²².
 — laterale m. tricipitis brachii, 23²⁸, 50¹⁷, 51¹⁵, 52¹⁴, 53¹².
 — longum m. bicipitis brachii, 21¹⁹, 22²³⁻⁷⁶, 23²⁴, 50¹, 51²⁰, 52²¹.
 — longum m. bicipitis femoris, 44⁶, 49¹⁶⁻²⁰, 76¹³, 77¹⁵, 78¹⁰, 79¹⁵, 80¹¹, 81¹⁶, 82¹¹, 83¹⁵, 84¹³.
 — longum m. tricipitis brachii, 22²⁹⁻⁷⁷, 23²⁹, 50¹⁶, 51¹⁴, 52¹⁰, 53¹¹.
 — mediale m. gastrocnemii, 89³, 90¹⁴, 91¹⁴.
 — mediale m. tricipitis brachii, 50¹⁴, 51¹³, 52¹¹, 53¹⁰.
 — nuclei caudati (*head of caudate nucleus*), 5³, 6⁶⁻⁸¹, 7⁸⁹.
- Caput obliquum m. adductoris hallucis (*adductor hallucis — transverse portion*), 111¹⁵.
 — pancreatis, 32⁶.
 Cartilago arytaenoidea, 19².
 — auriculæ, 8³³, 11²⁹⁻⁷².
 — corniculata [Santorini] (*cartilage of Santorini*), 18⁵⁸.
 — epiglottica, 17⁶⁴, 18².
 — septi nasi, 10⁸¹, 11⁹⁹.
 — thyreoidea [cornu superius]. See CORNU.
 — thyreoidea [lamina dextra]. See LAMINA.
 — thyreoidea [lamina sinistra]. See LAMINA.
 — triticea, 17¹³.
 Cauda equina, 33³⁵, 34³⁷.
 — nuclei caudati, 5¹⁹, 6⁵⁴, 7⁶⁸, 8⁶¹.
 Cavum Douglasi (*excavatio rectouterina*), 45³².
 — mediastinale anterius (*anterior mediastinum*), 24¹, 25⁷⁹.
 — nasi, 81⁹⁰, 9⁸⁸⁻⁹³⁻⁹⁷, 10¹⁻⁷⁷, 11¹.
 — peritonæi, 28¹¹⁻⁵⁹, 29¹²⁻⁷², 30⁷⁰, 31², 32²⁻¹⁹, 33¹⁻⁶⁰, 34⁴, 35¹⁹⁻⁶⁶⁻⁷², 36¹⁻¹⁹, 37³, 38⁵⁻⁴⁴⁻⁴⁶, 39³¹, 40⁴⁰⁻⁷⁰, 45⁶⁷, 46².
 — pleuræ, 22⁹², 23⁹, 24⁶⁹, 25⁵, 26⁵⁴, 27⁶⁸, 28¹⁴.
 — septi pellucidi (*fifth ventricle*), 6⁸⁶.
 — subarachnoideale, 13³⁸, 14⁴², 19³², 29⁴².
 — subdurale, 2², 4³⁵, 6⁵⁰, 8⁵⁷.
 — tympani, 10⁶⁰.
 Cellulae ethmoidales, 8⁵, 9⁸⁴⁻⁸⁷.
 — mastoideæ, 10²⁵⁻⁵⁵, 11³⁴⁻⁶⁷.
 Cervix uteri, 45⁴⁰.
 Chiasma opticum, 8⁸⁴.
 Chordæ tendineæ, 25⁷⁷, 26⁶⁷.
 Chorda tympani, 10⁵⁶.
 Claustrum, 5¹³, 6⁶⁷, 7⁷⁶.
 Clavicula, 20²⁰⁻⁴⁹, 21⁶⁷, 22²¹.
 Cochlea, 10⁵⁷.
 Colliculus inferior laminae quadrigeminae (*posterior quadrigeminal body*), 7⁴⁸⁻⁵⁷, 8⁴⁹.
 — superior laminae quadrigeminae (*anterior quadrigeminal body*), 7⁶³.
 Collum femoris (*neck of femur*), 42⁵⁸, 47⁴⁵.
 — radii (*neck of radius*), 60¹⁷.
 Colon ascendens, 34²⁰, 35²⁰, 36¹⁹, 37¹¹, 38⁹.
 — descendens, 30⁶⁷, 31⁵⁶, 32⁵³, 33⁵², 34⁵², 35⁵¹, 36⁵², 37⁵⁵, 38⁶¹.
 — sigmoideum, 39²⁷⁻⁶⁶.
 — transversum, 30⁷³, 31⁵⁹, 32⁵⁹, 33⁵⁹⁻⁷¹, 34⁷².
 Columna fornicis (*anterior pillar of fornix*), 6³, 7⁹³.
 — rectalis [Morgagni] (*column of Morgagni*), 42⁴².
 Commissura anterior cerebri, 6¹, 7⁷⁹⁻⁹⁶.
 — posterior cerebri, 7⁵⁹.
 Concha nasalis inferior (*inferior turbinated bone*), 11⁹⁶.
- Concha nasalis media (*middle turbinated bone*), 9², 10².
 Condylus lateralis tibiae, 92¹⁸.
 — medialis femoris, 90⁸, 92².
 — occipitalis, 12⁴¹.
 Conus arteriosus, 24⁷⁴.
 Cornu inferius ventriculi lateralis, 8²⁸⁻⁶⁰.
 — majus ossis hyoidei, 16⁴³, 17⁶¹.
 — posterius ventriculi lateralis, 5²⁰, 7³⁹.
 — superius cartilaginis thyreoideæ, 18⁹.
 Corona radiata, 5³⁷.
 Corpus adiposum orbitæ (*orbital fat*), 7⁹⁰.
 — callosum [genu]. See GENU.
 — callosum [truncus]. See TRUNCUS.
 — callosum [striae transversæ]. See STRIÆ.
 — cavernosum penis, 42², 43⁷⁰.
 — cavernosum urethrae virilis, 43⁴⁻⁸.
 — cavernosum clitoridis, 48²⁻⁴⁷.
 — fornicis, 5²¹, 6⁸³.
 — geniculatum laterale (*external geniculate body*), 7³³.
 — geniculatum mediale (*internal geniculate body*), 7³⁷.
 — Luysi [Nucleus hypothalamicus], 7⁷³.
 — mamillare, 7²⁶.
 — ossis hyoidei, 17⁶⁵.
 — ossis sphenoidalis, 8⁷, 9⁹.
 — pancreatis, 29⁶⁰, 30⁷⁴, 31⁷⁰.
 — pineale (*pineal gland or epiphysis*), 7⁵³.
 — restiforme (*inferior cerebellar peduncle*), 10³⁰⁻⁴³.
 — sterni (*gladiolus*), 24⁷⁵, 25¹, 26¹, 27¹.
 — uteri, 45⁶⁹.
 — vitreum, 8¹⁴⁻⁸⁰, 9⁸⁵.
 Crena ani (*anal cleft*), 42⁴¹, 46²⁸, 47²⁸, 48²³.
 Crista galli, 8⁹².
 — sacralis lateralis (*lateral sacral ridge*), 38⁴³, 40³⁴.
 Crus fornicis (*posterior pillar of fornix*), 6⁵¹.
 — mediale partis lumbalis diaphragmatis, 31³³⁻⁴², 32³², 33³².
 — penis, 43⁹.
 Culmen monticuli (*culmen of cerebellum*), 8⁴⁶.
 Cuneus (*cuneate lobe of cerebrum*), 42⁷, 52⁷, 64⁴, 74⁹.
 — posterior valvulae bicuspidalis (*marginal cusp of mitral valve*), 26⁶⁹.
- Declive monticuli (*declive of cerebellum*), 9⁴⁶.
 Decussatio lemniscorum (*decussation of mesial fillet*), 11⁴⁹.
 Dens epistrophei (*odontoid process of axis*), 13³⁰.
 Diaphragma, 27⁶⁷, 28¹⁵⁻⁶⁶, 29⁶⁻¹⁶⁻³²⁻⁴⁹, 30¹⁰⁻³⁰, 31⁵¹.
 — [crus intermedium]. See CRUS.
 — [crus mediale]. See CRUS.

- Discus articularis articulationis radioulnaris distalis (*triangular articular disc*), 70⁷.
 — articularis articulationis sternoclaviculares, 222².
 Ductuli efferentes testis (*vasa efferentia*), 44¹.
 Ductus choledochus (*common bile duct*), 32⁸.
 — cysticus, 31¹⁴.
 — deferens (*vas deferens*), 40¹⁹⁻⁵⁷, 41⁶⁷, 42⁷⁴, 43⁹⁵, 44²⁴.
 — hepaticus, 30¹⁴, 31¹².
 — nasolacrimalis, 9⁵⁻⁹¹, 10⁴⁻⁷⁷.
 — pancreaticus [Wirsung], 30⁷⁶, 31⁹⁸.
 — thoracicus, 21⁷⁵, 22⁹⁸, 24¹, 25⁴², 26⁸⁹, 28⁸⁵, 29⁸⁹, 30⁴⁷, 31²⁶, 32²⁴.
 Duodenum 31⁵².
 — [pars descendens]. See PARS.
 — [pars inferior]. See PARS.
 — [pars superior]. See PARS.
 Dura mater encephali, 1²¹, 2², 4⁶, 7¹⁸, 10³².
 — mater spinalis, 13⁹⁵, 21¹, 30¹⁴, 33²⁴, 35³⁵, 38³⁵.
 Eminentia intercondyloidea tibie (*spinous process*), 91².
 Emissarium condyloideum (*emissary vein in condylar foramen*), 11⁵⁵⁻⁷⁰.
 Epicardium (*visceral layer of pericardium*), 25⁶⁰, 26⁶⁰, 27¹⁰⁻⁶⁹.
 Epicondylus lateralis femoris (*external epicondyle*), 90²⁶.
 — lateralis humeri (*external epicondyle*), 58¹⁴.
 — medialis femoris (*internal epicondyle*), 90².
 — medialis humeri (*internal epicondyle*), 58⁷.
 Epidermis, 1⁴.
 Epiglottis, 16³⁵.
 Epistropheus (*axis*), 14⁴², 15²⁵.
 — [processus spinosus]. See PROCESSUS.
 Excavatio rectouterina = Cavum Douglasi (*pouch of Douglas*), 45³⁵.
 — vesicouterina (*utero-vesical pouch*), 45⁴.
 Facies articularis superior tibie, 91⁴⁻²⁹.
 — orbitalis maxillae (*orbital surface of maxilla*), 9⁷.
 — orbitalis ossis zygomatici (*superior internal face of malar*), 9¹⁶.
 — posterior hepatis, 29²⁸.
 Falx cerebri, 2¹, 3¹, 4¹⁻²⁴, 7¹⁰⁰.
 Fascia antibrachii (*deep fascia of forearm*), 61²².
 — dentata hippocampi (*gyrus dentatus*), 6⁹⁵.
 — diaphragmatis pelvis inferior (*anal fascia*), 41⁴⁴, 42⁴⁹, 47²⁵⁻³².
 — diaphragmatis pelvis superior (*pelvic visceral fascia*), 47²⁹⁻³².
 Fascia endopelvina, 42⁷.
 — iliaca, 39⁵⁸.
 — lata, 41⁵³⁻⁶⁵, 43⁴⁴, 44²⁹, 45¹⁶⁻⁵⁷, 46⁴⁶, 47¹³, 48¹²⁻⁵⁶, 77¹², 83³.
 — lumbodorsalis, 41²⁸, 45²⁷.
 — obturatoria, 40⁵³, 45¹⁸, 46¹⁵.
 — pelvis, 40²⁶, 41³⁰⁻⁴², 45³², 46²⁶⁻³³.
 — penis, 42⁷⁰, 43⁵⁻⁷².
 — temporalis, 9²⁵⁻⁷².
 — transversalis, 34¹⁴, 36⁷⁰, 38⁶⁵, 40⁶⁸, 46⁵⁴.
 Fasciculi longitudinales pyramidales pontis (*pyramidal tracts of pons*), 8³², 9³⁷, 10⁵⁰.
 Fasciculus thalamomamillaris [Vieq d'Azyri] (*bundle of Vieq d'Azyr*), 6¹⁹, 7⁸⁴.
 Femur, 43²³, 44¹⁶, 48³⁵, 76²⁹, 77¹⁰, 78¹⁷, 79¹⁹, 80¹⁶, 81²³, 82¹⁸, 84¹⁸, 85¹, 86¹⁷, 87², 88¹⁷, 89², 90².
 Fibrae pontis profundae, 8³¹, 9⁶⁴.
 — pontis superficiales, 8³¹, 9⁵⁷⁻⁷⁰.
 Fibrocartilago intervertebralis (*intervertebral disc*), 21⁸⁰, 27⁴³, 28²⁸, 29⁴¹, 34³⁶, 37³⁵, 38³⁶.
 Fibula, 93¹⁵, 94¹³, 95¹³, 96¹⁴, 97¹⁴, 98¹², 99¹², 100¹³, 101¹⁵, 102¹⁴, 103¹⁵, 104¹⁴, 105¹⁴, 106¹⁵.
 — [capitulum]. See CAPITULUM.
 Filum dure matris spinalis, 39²⁷, 40³⁰.
 Fimbria hippocampi, 6³²⁻³¹, 7³⁵⁻⁶⁶.
 Fissura calcarina, 6²⁹.
 — cerebri lateralis [Sylvii] (*fissure of Sylvius*), 5¹³, 6¹, 7⁸¹, 8⁶⁸.
 — orbitalis inferior (*sphenomaxillary fissure*), 9¹⁴.
 — orbitalis superior (*sphenoidal fissure*), 9¹⁴.
 Flexura coli dextra (*hepatic flexure*), 34¹⁵.
 — coli sinistra (*splenic flexure*), 29⁶².
 — duodenojejunalis, 30⁷⁵, 31⁵⁸.
 Flocculus, 9⁵⁵, 10²⁸⁻⁵².
 Foramen caecum linguae [Morgagni], 15⁶².
 — epiloepum [Winslowi] (*foramen of Winslow*), 31¹⁰.
 — jugulare, 10²⁴.
 — ovale ossis sphenoidalis, 10⁶⁶.
 — sacrae anterioris, 38³², 39⁴¹.
 — sacrae posterioris, 39³⁴.
 Fossa acetabuli, 46⁴⁴⁻⁴⁵.
 — coronoidea humeri, 58⁴.
 — intercondyloidea femoris (*intercondyloid notch*), 90².
 — interpeduncularis [Tarini] (*interpeduncular space*), 8³⁵.
 — ischiorectalis, 42³⁶, 43³⁴, 47²²⁻²⁶, 48²⁷, 49¹⁹.
 — olecrani, 58¹⁹.
 — radialis humeri, 58¹⁷.
 — pterygopalatina (*spheno-mazillary fossa*), 9¹².
 — trochanterica (*digital fossa of femur*), 47¹⁵⁻⁴⁴.
 Fovea capituli radii (*pit of head of radius*), 59²².
 Fundus uteri, 45².
 Funiculus spermaticus (*spermatic cord*), 40⁸, 41⁵, 42⁶.
 Galea aponeurotica (*epicranial aponeurosis*), 1¹⁻¹⁶, 2¹¹, 3²⁰, 4²⁰, 5³⁴, 6³¹, 8⁴².
 Ganglion cervicale superius, 13¹⁹⁻⁵¹, 14²⁸⁻⁵⁵, 15⁴³, 16⁴¹.
 — coeliacum (*coeliac plexus*), 30²⁸⁻⁶⁸, 31²¹⁻⁴⁵.
 — nodosum, 11³¹⁻⁶⁸.
 — semilunare [Gasseri] (*Gasserian ganglion*), 9²⁰.
 — sphenopalatinum (*Meckel's ganglion*), 10⁷³.
 — spinale, 13⁷².
 — thoracale, 21²⁸.
 Genu capsulae internae, 6¹⁰⁻⁷².
 — corporis callosi, 5², 6⁸³.
 Gingiva (*gums*), 14⁴.
 Glandula lacrimalis inferior (*palpebral portion of lachrymal gland*), 8¹⁹.
 — lacrimalis superior (*orbital portion of lachrymal gland*), 7¹⁵, 8⁷⁵.
 — palatina, 12⁴.
 — parotis, 11²⁴⁻²⁸⁻⁷²⁻⁷⁷, 12²², 14⁵⁸, 15¹⁵⁻⁴⁷.
 — sublingualis, 14³, 15⁴⁻⁵⁷.
 — submaxillaris, 15¹⁰⁻⁵¹, 16⁴⁶, 17⁷⁻⁵⁹.
 — suprarenalis, 29²⁷⁻⁵¹, 30²⁶.
 — thyreoidea [lobus dexter]. See LOBUS.
 — thyreoidea [lobus sinister]. See LOBUS.
 Glans clitoridis, 49²⁹.
 Globus pallidus, 6¹², 7²⁸⁻⁸².
 Glomus caroticum (*carotid gland*), 17¹⁵.
 — chorioideum (*chorioid skein*), 6⁵³.
 Granulatio arachnoidealis [Pacchioni] (*Pacchionian body or gland*), 1²².
 Gyrus angularis, 4¹⁸, 5⁵⁶, 6⁵⁸.
 — centralis anterior (*precentral gyrus*), 2¹⁹, 3⁵⁻²³, 4¹¹⁻⁴⁹, 5⁴².
 — centralis posterior (*postcentral gyrus*), 1¹⁰, 2¹⁷, 3¹²⁻³¹, 4¹⁴⁻²⁸, 5⁴⁰.
 — cinguli (*gyrus fornicatus*), 5²⁸⁻⁵³, 6¹⁵⁻⁸⁵.
 — frontalis inferior, 4¹⁹, 5⁴, 6⁷³.
 — frontalis inferior [pars orbitalis]. See PARS.
 — frontalis medius, 3³⁶, 4⁴³⁻⁴⁵, 5⁴⁴⁻⁴⁷⁻⁴⁹, 6⁸⁰.
 — frontalis superior, 1³, 2²³, 3²⁻³⁹, 4⁴⁷⁻⁴⁹, 5³², 6⁸⁴, 7³⁻⁹⁴.
 — fusiformis (*occipitotemporal convolution*), 8⁵¹, 9⁵².
 — hippocampi (*hippocampal convolution of uncinate gyrus*), 7⁴²⁻⁵⁵, 8⁵⁰, 9⁶⁸.
 — linguialis (*subcalcarine gyrus*), 7⁵⁰⁻⁵⁴, 8⁴⁷, 9⁵⁰.
 — occipitalis lateralis, 7⁵⁸, 8⁵², 9⁴⁸.
 — occipitalis superior, 6⁴⁸⁻⁵².

- Gyrus orbitalis, 87^o.
 — rectus, 88⁷.
 — supramarginalis, 415-36, 538, 666.
 — temporalis inferior (*inferior temporal convolution*), 85^o, 927-56.
 — temporalis medius (*middle temporal convolution*), 85^o, 906.
 — temporalis superior (*superior temporal convolution*), 655-62, 705-69-78, 897, 973.
- Hepar [lobus caudatus]. See LOBUS.
 — [lobus dexter]. See LOBUS.
 — [lobus sinister]. See LOBUS.
 — [lobus quadratus]. See LOBUS.
 — [processus papillaris]. See PROCESSUS.
 — [processus caudatus]. See PROCESSUS.
- Hiatus sacralis (*sacral canal, inferior opening of*), 4037.
 — tendineus adductorius (*Hunter's canal, inferior opening of*), 851^o.
- Hippocampus (*cornu ammonis*), 634, 764.
 Humerus, 2224-76, 2326, 501^o, 5118, 521^o, 531^o, 54^o, 55^o, 56^o, 57^o, 5813.
 Hypophysis (*pituitary body*), 996.
- Incisura interlobaris pulmonis (*fissure of lung*), 2363.
 — semilunaris ulnæ (*greater sigmoid cavity*), 598.
- Infundibulum ethmoidale (*infundibulum*), 86.
- Insula (*Island of Reil*), 614, 780.
 Integumentum commune (*skin*), 3567.
 Intestinum cæcum (*cæcum*), 397, 406.
 — ileum, 342-7-8, 356-8-14-16-17-71, 366-8-15-17-51-58-65-67-68-71-73, 371-7-18-54-58-60-61-63-64-65-66-69-70, 382-4-6-8-11-64-67-69-71, 392-6-15-18-57-68-72-73, 405-20-66-69-71.
 — jejunum, 3072, 3155-57, 3254-57-58-64, 3353-55-56-66, 3453-55-58-63-69, 353-40-53-60-61-63.
 — rectum, 4039, 4539, 4630.
 Iris, 812.
- Labium anterius orificii externi uteri (*anterior lip of cervix*), 4631.
 — inferius oris, 1363.
 — majus pudendi (*labium majus*), 492.
 Labrum glenoidale (*glenoid ligament*), 4643.
 Lacertus fibrosus m. bicipitis (*semilunar or bicipital fascia*), 5931, 601.
 Lamina dextra cartilaginis thyreoideæ, 1967.
 — fibrocartilaginea interpubica (*interpubic disc*), 4172, 471.
 — medullaris thalami (*medullary layers of thalamus*), 661.
- Lamina papyracea (*os planum*), 89.
 — perpendicularis ossis ethmoidalis, 995.
 — sinistra cartilaginis thyreoideæ, 1857.
 — terminalis, 72.
 Lemniscus medialis (*mesial fillet*), 1039.
 Lens crystallina (*lens*), 814.
 Lien, 2856, 2961.
 (Lien accessorius), 2959.
 Ligamentum (a) annulare radii (*orbicular lig.*), 5918-23.
 — arcuatum pubis (*inferior pubic lig.*), 423.
 — carpi dorsale (*posterior annular lig.*), 7017.
 — carpi radiatum (*palmar lig.*), 7112-30.
 — carpi transversum (*anterior annular lig.*), 7132.
 — carpi volare (*anterior annular lig.*), 703.
 — collateralia articulationum digitorum manus (*lateral phalangeal ligaments*), 7416.
 — collaterale fibulare (*external lateral lig. of knee*), 9125.
 — collaterale tibiale (*internal lateral lig. of knee*), 915.
 — collaterale ulnare (*internal lateral lig. of ulna*), 5911.
 — coracoclaviculare, 2115-65.
 — coronarium hepatis, 2822-24, 2925.
 — cruciatum anterius genu, 9024, 9130.
 — cruciatum atlantis, 1238.
 — cruciatum posterius genu, 917.
 — denticulatum, 1942.
 — falciforme hepatis, 281, 293, 303, 314.
 — flavum (*lig. subflavum*), 1734, 1828, 1927-37, 2035, 2252, 3050, 3235, 3337, 3435, 3637, 3734.
 — gastrocolicum, 2965.
 — gastrolienale (*gastrosplenic omentum*), 2854-61.
 — (hepatocolicum), 338.
 — hepatoduodenale, 3115.
 — hepatogastricum, 2970.
 — hepatorenale, 3125.
 — iliofemorale (*Y-shaped lig. of Bigelow*), 4016, 4115, 4613.
 — iliolumbale, 3646.
 — inguinale [Pouparti] (*Poupart's lig.*), 3911-63, 4010, 4562, 4652.
 — interclaviculare, 22100.
 — interspinale, 2941.
 — latum uteri (*broad lig.*), 4514.
 — longitudinale anterius (*anterior common lig.*), 1187, 1267, 1364, 3230, 3431, 3541, 3632, 3828.
 — longitudinale posterius (*posterior common lig. of spinal column*), 1820, 3738.
 — nuchæ, 1150, 1233, 1335, 1630, 1733, 1831, 1936, 2034.
 — patellæ (*anterior lig.*), 9131, 9219, 9322.
 — pisohamatum (*pisiform lig.*), 716.
 — pisometacarpeum, 718.
- Ligamentum (a) plantare longum (*calcaneo-cuboid lig. or long plantar lig.*), 10917, 11020.
 — pulmonale (*lig. latum pulmonale*), 2653, 2748.
 — radiocarpeum dorsale (*posterior radiocarpal lig.*), 7014.
 — radiocarpeum volare (*anterior radiocarpal lig.*), 7028.
 — sacroiliacum anterius, 3725.
 — sacroiliacum interosseum (*posterior sacro-iliac lig.*), 3727-41.
 — sacroiliacum posterius breve (*short iliac lig.*), 3840.
 — sacroiliacum posterius longum (*oblique sacroiliac lig.*), 3946.
 — sacrospinous (*small sacrosclatic lig.*), 4131, 4529-43, 4620.
 — sacrotuberous (*great sacrosclatic lig.*), 4140, 4247, 4530-42, 4622-36, 4722-37.
 — sphenomandibulare, 1126-75, 1216-53.
 — stylohyoideum, 169-51.
 — suprascapulare, 3047.
 — talocalcaneum laterale (*external calcaneo-astragaloid lig.*), 10820.
 — talofibulare anterius (*anterior fasciculus of external lateral lig.*), 10718.
 — talofibulare posterius (*posterior fasciculus of external lateral lig.*), 10718.
 — talotibiale posterius (*posterior tibio-tarsal lig.*), 1076.
 — temporomandibulare (*external lateral lig.*), 1018, 1176.
 — teres femoris (*round ligament of femur*), 4017, 4115, 4612.
 — teres hepatis (*round lig. of liver*), 315, 323, 332, 341, 352.
 — teres uteri (*round lig. of uterus*), 459-63, 466-52, 473-54, 483-48.
 — transversum atlantis, 1326.
 — triangulare dextrum hepatis, 3031.
 — [umbilicale laterale] (*obliterated hypogastric lig.*), 3771, 383-70, 3910-55-69, 455-70.
 — umbilicale medium (*urachus*), 3674, 3772, 3872, 3974, 4072, 451, 4658.
 — vaginale digiti manus (*lig. of digital sheath*), 757.
 — vaginale digiti pedis, 1131.
 — venosum [Arantii] (*obliterated ductus venosus*), 2873, 292.
 — vocale (*inferior thyroarytenoid lig.*), 1965.
- Linea alba, 301, 311, 3272, 3372, 3473, 351.
 — aspera, 7815, 8014, 8120, 8215, 8416, 853.
 — semilunaris [Spigeli], 3465, 3565, 367, 387.
 — temporalis ossis frontalis (*temporal ridge*), 69, 786.
 — terminalis (*brim of pelvis*), 3918.
 Lobulus biventer, 1197.
 — centralis, 731.
 — paracentralis (*paracentral gyrus*), 221, 320-38, 434.

- Lobulus parietalis inferior, 31³⁻²⁸⁻³⁰, 41⁹⁻³¹⁻³³, 53².
 — parietalis superior (*superior parietal gyrus*), 21⁵, 32⁶, 43⁷, 53⁰.
 — quadrangularis, 8⁵⁹.
 — semilunaris inferior (*inferior semilunar lobe*), 10³⁴⁻⁴⁶⁻⁵¹, 11⁵³.
 — semilunaris superior (*posterior crescentic lobe*), 9³⁹⁻⁵¹.
- Lobus caudatus [Spigeli] (*Spigelian lobe*), 28⁷⁵, 29⁷⁴, 30¹⁴.
 — dexter glandulae thyreoideae, 19², 20³.
 — hepatis dexter, 28¹⁷, 29²⁰, 30²⁴, 31²¹, 32¹⁸, 34¹⁸.
 — hepatis sinister, 28⁶⁰, 29⁵⁰, 30⁵⁰, 31⁷⁴, 32⁷¹.
 — inferior pulmonis, 22⁵⁸, 23⁶⁵, 24³³⁻⁴⁶, 25³³⁻⁵¹, 26²⁷⁻³², 27²⁹⁻⁵², 28¹⁸⁻²⁶⁻⁴⁸, 29²⁹.
 — medius pulmonis, 24¹⁴, 25¹⁷, 26¹¹.
 — quadratus hepatis, 32⁷, 33⁵.
 — sinister glandulae thyreoideae, 20⁶³, 21⁷⁷.
 — superior pulmonis, 21³⁵, 22⁷, 23⁷⁻¹¹⁻³⁰, 24²⁴⁻⁶⁵, 25²⁶⁻⁶⁵, 26⁶⁴, 27⁷⁰.
- Lymphoglandula, 17¹, 24²⁰, 31³⁴, 32¹⁰, 35⁵⁰⁻⁵⁶, 42¹², 43¹², 45⁵⁶.
 — axillaris, 22⁶⁷, 23⁷³⁻⁸⁶.
 — inguinalis, 47³¹, 49³⁶.
 — mediastinalis, 22⁵, 23⁵, 25³¹.
- Malleolus lateralis (*external malleolus*), 107¹⁷.
 — medialis (*internal malleolus*), 107⁵.
- Mandibula, 14⁶⁸, 15⁶⁰, 16¹.
 — [processus condyloideus]. See PROCESSUS.
 — [processus coronoideus]. See PROCESSUS.
 — [ramus]. See RAMUS.
- Manubrium sterni (*manubrium*), 23².
 Margo axillaris scapulae (*axillary border*), 22³¹⁻⁷².
 — infraglenoidalis tibiae, 91²⁸.
 — vertebralis scapulae (*vertebral border*), 22⁶².
- Massa intermedia (*middle commissure*), 6²⁰.
- Maxilla (*superior maxillary bone*), 10³, 11¹⁰, 12².
 — [processus frontalis]. See PROCESSUS.
 — [processus zygomaticus]. See PROCESSUS.
 — [facies orbitalis]. See FACIES.
- Meatus acusticus externus, 10⁵⁸.
 — nasi inferior, 11⁵.
 — nasi medius, 9⁵⁹.
 — nasi superior, 9⁵⁹.
- Medulla oblongata, 12³⁴.
 — spinalis (*spinal cord*), 14⁴¹, 15²⁹, 16²⁹, 17³², 18²⁹, 19³³, 23³⁶.
- Membrana atlantooccipitalis posterior (*posterior occipitoatlantal lig.*), 12³¹, 13³⁹.
- Membrana interossea antibrachii (*radio-ulnar interossea*), 61¹⁴, 62¹¹, 63⁷, 64²⁴, 65⁸, 66⁵, 67¹⁰, 68¹¹.
 — interossea cruris (*tibio-fibular interossea*), 93²⁰, 94¹⁹, 96¹⁹, 99¹⁷, 101¹⁶, 102¹⁶, 103¹⁶.
 — obturatoria, 41⁵⁹, 47⁵⁰.
 — tectoria (*posterior occipito-axial lig.*), 12²⁸.
 — tympani, 10⁵⁹.
- Meniscus lateralis articularis genu (*external semilunar fibro-cartilage*), 91²⁶.
 — medialis articularis genu (*internal semilunar fibro-cartilage*), 91⁶.
- Mesenterium, 35⁷, 36³⁹⁻⁶⁹, 37⁵⁻⁶⁷, 38⁶⁶.
 Mesocolon transversum, 30⁷⁷, 31⁶³, 33⁶⁸.
- Musculus (i) abductor digiti quinti manus (*abductor minimi digiti*), 71⁷, 72⁸, 73⁸, 74⁸.
 — abductor digiti quinti pedis (*abductor digiti quinti*), 109¹⁶, 110²¹, 111²⁰, 112¹⁸.
 — abductor hallucis, 108¹⁰, 109⁸, 110⁸, 111⁷, 112⁷, 113⁴.
 — abductor pollicis brevis (*abductor pollicis*), 71²⁸, 72²².
 — abductor pollicis longus (*extensor ossis metacarpi pollicis*), 63¹⁶, 64¹⁴, 65¹⁴, 66¹⁷, 67¹⁸, 68¹⁹, 69¹⁷, 70²⁵, 71²⁶.
 — adductor brevis, 42⁷², 43⁶², 44⁴, 48⁵⁻⁴⁵, 49³⁻³², 76⁷, 77⁷, 78¹².
 — adductor hallucis, 112¹⁰, 113⁷.
 — adductor hallucis [caput obliquum]. See CAPUT.
 — adductor longus, 42⁷², 43⁶², 44³¹, 48⁴⁻⁴⁴, 49⁴, 76³, 77⁴, 78⁴, 79⁵, 80¹, 81⁷, 82⁵, 83².
 — adductor magnus, 44⁴, 49¹⁷⁻²⁹, 76¹⁰, 77¹¹, 78⁶, 79⁸, 80⁹, 81¹⁴, 83⁸, 84⁷, 85⁶, 86⁴, 87⁵, 88⁵.
 — adductor minimus (*upper portion of adductor magnus*), 43²¹, 44¹⁰, 48⁶⁻³⁵, 49¹⁴⁻²⁹, 76¹⁷.
 — adductor pollicis, 72²¹, 73²¹.
 — anconeus, 59¹⁷, 60¹⁶, 61¹⁵, 62¹⁴.
 — articularis genu (*subcrureus*), 86¹, 87¹.
 — arytenoideus transversus (*transverse fibers of arytenoid*), 19⁶⁴.
 — auricularis anterior (*atrahens aurem*), 9⁶³.
 — auricularis posterior (*retrahens aurem*), 9²⁴.
 — auricularis superior (*attolens aurem*), 6²³⁻⁶⁵, 7¹⁰, 9⁶¹.
 — biceps brachii (*biceps*), 53²¹, 54¹⁷, 55¹, 56¹⁷, 57¹⁸, 58²³, 59²⁰, 60²⁸, 61².
 — biceps brachii [caput breve]. See CAPUT.
 — biceps brachii [caput longum]. See CAPUT.
 — biceps femoris, 42³², 43³⁰, 47¹⁸⁻⁴⁰, 48¹⁹⁻³¹, 85¹⁶, 86¹⁴, 87¹⁶, 88¹⁴, 90²⁵, 91²⁴, 92¹⁷.
- Musculus (i) brachialis (*brachialis anticus*), 52¹⁷, 53¹⁸, 54¹⁵, 55¹⁵, 56¹⁴, 57¹⁵, 58²⁰, 59²⁷, 60¹⁴.
 — brachioradialis (*supinator longus*), 55¹³, 56¹², 57¹³, 58¹⁹, 59²⁴, 60²⁴, 61²⁵, 62²³, 63²¹, 64²⁰, 65²¹, 66²², 67²¹, 68²¹, 69¹⁸.
 — buccinator, 12⁹, 13⁹⁻⁵⁹, 14⁹⁻⁷¹.
 — bulbo cavernosus (*accelerator urinæ*), 43³⁹.
 — caninus (*levator anguli oris*), 10³, 11⁴, 12³⁻⁶⁹.
 — coccygeus, 41²⁸⁻³²⁻⁴³, 45³¹, 46³³.
 — constrictor pharyngis inferior, 18⁸.
 — constrictor pharyngis superior, 11⁸⁹, 13⁵⁸.
 — constrictores pharyngis, 12⁵, 13³, 14⁶¹, 15⁵⁰, 16⁴⁴⁻⁴⁵, 17⁵⁵, 18⁵³, 19⁶¹.
 — coracobrachialis, 22²¹⁻⁷⁹, 23²¹, 50⁴, 51⁵, 52².
 — cremaster, 43⁶⁷.
 — deltoideus, 20¹⁸⁻⁵³, 21¹⁶⁻²⁴, 22²⁶⁻⁷⁵, 23²⁷, 50¹⁸, 51¹⁷, 52¹⁸.
 — digastricus, 13⁴⁶, 15¹³⁻¹⁷, 16⁵⁻¹²⁻⁴⁸⁻⁵⁶.
 — digastricus [venter posterior]. See VENTER.
 — extensor carpi radialis brevis, 59²¹, 60²², 61²³, 62²¹, 63¹⁹, 64¹⁶, 65¹⁷, 66¹⁹, 67¹⁹, 68¹⁸, 69¹⁴, 70¹⁹, 71¹⁷.
 — extensor carpi radialis longus, 57¹², 58¹⁶, 59²¹, 60²², 61²³, 62²¹, 63¹⁹, 64¹⁶, 65¹⁷, 66¹⁹, 67¹⁹, 68¹⁸, 69¹⁴, 70²⁰, 71¹⁹.
 — extensor carpi ulnaris, 59¹⁹, 60¹⁸, 61¹⁷, 62¹⁵, 63¹², 64¹⁰, 65¹⁰, 66¹⁰, 67¹¹, 68¹⁰, 69⁹, 70¹¹, 71⁹.
 — extensor digiti quinti proprius (*extensor minimi digiti*), 59¹⁹, 60¹⁹, 61¹⁸, 62¹⁷, 63¹⁵, 64¹², 65¹², 66¹², 67¹², 68¹², 69¹⁰, 70¹³, 71¹¹, 72¹², 73¹¹, 74¹¹, 75⁴.
 — extensor digitorum brevis (*extensor brevis digitorum*), 108¹⁹, 109²², 110²⁶, 111²⁶, 113¹⁷.
 — extensor digitorum communis, 59¹⁹, 60²⁰, 61¹⁹, 62¹⁸, 63¹⁷, 64¹⁵, 65¹⁵, 66¹⁵, 67¹⁴, 68¹⁴, 69¹², 70¹⁶, 71¹³, 72¹⁷, 74¹⁴⁻¹⁸, 75⁹.
 — extensor digitorum longus pedis, 93¹⁹, 94¹⁷, 95¹⁶, 96¹⁸, 97¹⁶, 99¹⁵, 100¹⁷, 101¹⁸, 102¹⁹, 103¹⁸, 104¹⁷, 105¹⁶, 106²⁰, 107²¹, 108²³, 109²⁴, 110²⁸, 111²⁸, 112²⁰⁻²², 113¹⁷.
 — extensor hallucis brevis, 108²¹, 109²³, 110¹, 111³, 112³.
 — extensor hallucis longus (*extensor proprius hallucis*), 93¹⁹, 94¹⁷, 95¹⁶, 96¹⁸, 97¹⁶, 99¹⁵, 100¹⁹, 101¹⁹, 102²⁰, 103²¹, 104²⁰, 105¹⁹, 106²¹, 107¹, 108¹, 109², 110⁵, 111⁴, 112⁴, 113².
 — extensor indicis proprius (*extensor indicis*), 65¹¹, 66⁹, 67¹², 68¹³, 69¹¹, 70¹⁵, 71¹⁵, 72¹⁸, 73¹⁷, 75¹¹.

INDEX TO BNA TERMS

- Musculus (i) extensor pollicis brevis (extensor primi internodii pollicis)*, 66¹⁰, 67¹⁰, 68¹⁷, 69¹⁰, 70²⁴, 71²⁴, 72²⁰.
- *extensor pollicis longus (extensor secundi internodii pollicis)*, 62¹³, 63¹³, 64¹¹, 65¹², 66¹¹, 67¹⁵, 68¹⁵, 69¹³, 70¹⁸, 71²⁰, 72²⁵, 73²⁴.
- *flexor carpi radialis*, 59⁶, 60⁶, 61⁴, 62⁴, 63¹, 64²⁵, 65²², 66²⁵, 67²⁴, 68²⁴, 69²³, 70²⁰.
- *flexor carpi ulnaris*, 59¹⁴, 60¹⁰, 61¹¹, 62⁸, 63⁷, 64⁷, 65⁶, 66⁶, 67⁴, 68⁵, 69⁴, 70⁵, 71²⁹.
- *flexor digiti quinti brevis manus (flexor minimi digiti)*, 72⁸, 73⁸.
- *flexor digiti quinti brevis pedis (flexor minimi digiti)*, 111¹⁸, 112¹⁷.
- *flexor digitorum brevis pedis*, 109¹², 110¹⁵, 111¹⁴, 112¹⁵, 113¹¹.
- *flexor digitorum longus pedis*, 96², 97⁴, 98², 99⁴, 100⁴, 101⁵, 102⁶, 103⁵, 104⁵, 105⁵, 106⁵, 107⁸, 108⁷, 109¹⁰, 110¹³, 111¹³, 112¹¹⁻¹⁵, 113¹¹.
- *flexor digitorum profundus*, 59¹⁵, 60¹³, 61¹², 62⁹, 63¹⁰, 64⁶, 65⁴, 66³, 67³, 68³, 69², 70¹, 71¹⁴, 72³, 73¹, 74³⁻⁶⁻²⁴⁻²⁷, 75²⁻¹³.
- *flexor digitorum sublimis*, 59¹⁰, 60⁹, 61⁸, 62⁵, 63⁵, 64⁴, 65³, 66², 67², 68², 69¹, 70², 71³, 72³, 73¹, 74³⁻⁶⁻²⁴⁻²⁷, 75²⁻¹³.
- *flexor hallucis brevis*, 109⁷, 110⁹, 111⁸, 112⁸, 113⁶.
- *flexor hallucis longus*, 97¹³, 98¹¹, 99¹¹, 100¹¹, 101¹², 102¹², 103¹², 104¹⁰, 105⁶, 106¹¹, 107¹¹, 108⁸, 109⁹, 110¹¹, 111⁹, 112⁹.
- *flexor pollicis brevis*, 72²¹, 73²⁰.
- *flexor pollicis longus*, 62²⁴, 63²², 64¹⁹, 65¹⁸, 66²⁴, 67²³, 68²³, 69²², 70³⁰, 71³¹, 72³⁰, 73²⁷.
- *frontalis*, 3⁵, 4⁵, 5¹⁻⁴⁸.
- *gastrocnemius*, 92¹¹, 93⁸⁻¹⁴, 94⁸⁻¹¹, 95⁸⁻¹¹, 96⁸⁻¹², 97⁷, 98⁶, 99⁸, 100⁸, 101⁹.
- *gastrocnemius [caput laterale]*. See CAPUT.
- *gastrocnemius [caput mediale]*. See CAPUT.
- *gemellus inferior*, 41¹⁸⁻⁵².
- *gemellus superior*, 41²⁴⁻⁴⁹, 46¹⁷⁻⁴⁰.
- *genioglossus*, 14¹, 15¹.
- *geniohyoideus*, 16⁵⁹, 17².
- *glossopalatinus (palatoglossus)*, 13⁷.
- *gluteus maximus*, 38²⁷⁻⁴⁵, 39⁵⁰, 40³²⁻⁴¹, 41²⁶⁻⁴⁵, 42⁴⁶⁻⁵⁵, 43²⁴⁻³²⁻⁴³, 44¹¹⁻¹⁴, 45⁵⁰, 46⁴¹, 47²⁶⁻³², 48²²⁻²⁸, 49¹⁸⁻²⁴, 76¹⁶⁻¹⁹, 77¹⁷, 78¹³.
- *gluteus medius*, 36²⁵⁻⁴⁷, 37⁴⁸, 38²⁵, 39⁵³, 40⁵², 41¹⁶, 42⁵⁷, 45⁵², 46⁴⁶, 47¹³⁻⁴⁵.
- *gluteus minimus*, 37¹⁵⁻⁵⁵, 38²⁰, 39⁵⁴, 40⁵⁴, 41¹⁷, 45⁵⁸, 46⁴⁷, 47¹⁴⁻⁴⁶.
- Musculus (i) gracilis*, 42⁴⁻⁷⁶, 43¹⁰, 44³², 48⁴⁰, 49³⁻³⁷, 76⁹, 77⁸, 79⁷, 81⁸, 83⁹, 84⁵, 85⁹, 86⁷, 87⁹, 88⁸, 89¹⁰, 90¹¹, 91¹⁰, 92³, 93³.
- *hyoglossus*, 14⁸⁻⁷⁵, 15⁶⁻⁵⁵, 16⁵, 17⁴⁻⁶².
- *iliacus*, 36²⁷, 37¹⁷.
- *iliocostalis*, 21⁴⁹, 22⁶⁰, 23⁴⁷, 24³², 26³², 27³²⁻⁴⁹, 29³⁴, 30³⁶.
- *iliocostalis cervicis (cervicalis ascendens)*, 20¹³, 22¹².
- *iliocostalis dorsi (accessorius)*, 25³², 28³⁰.
- *iliocostalis lumborum (sacro-lumbalis)*, 31³⁰, 32²⁰, 33³⁰⁻⁴⁰, 34¹², 35³², 36³⁵, 37³³⁻³⁹, 38³³, 39⁴².
- *iliopsoas*, 38²⁰, 39⁵⁸, 40⁶¹, 41¹²⁻⁵⁹, 42²¹⁻⁵⁹, 43²⁰⁻⁵³, 45⁵⁹, 46⁴⁹, 47⁴⁷, 48¹³⁻³⁶, 49⁴¹, 76²⁶.
- *infraspinatus*, 21²⁵⁻⁵⁹, 22³³⁻⁷¹, 23³⁷⁻⁷², 24²⁷.
- *intercostalis externus*, 21⁵⁰, 22¹¹⁻³⁸⁻⁶³, 23¹⁴⁻⁴¹⁻⁴⁵, 26¹⁴⁻¹⁹, 27³³⁻⁶⁴, 29¹⁹⁻²⁴, 30¹⁵⁻²⁵⁻³⁵.
- *intercostalis internus*, 21⁷¹, 22¹²⁻⁴⁰⁻⁵⁹, 23¹⁰⁻¹⁵⁻⁴²⁻⁴⁵⁻⁶⁸⁻⁹⁴, 24⁸⁻⁶⁶, 25⁷⁻¹³, 26⁵⁻¹⁴⁻²⁸, 27⁶⁻¹⁴⁻²⁸, 28¹⁰⁻⁶⁵⁻⁷⁰⁻⁷⁶, 29¹¹⁻¹⁹⁻²⁴, 30¹⁵⁻²⁵, 31⁹.
- *interosseus dorsalis manus*, 72¹²⁻¹⁶⁻²², 73¹²⁻¹⁵⁻¹⁸⁻²², 74¹⁵⁻¹⁹⁻²², 75⁵⁻⁸⁻¹⁰.
- *interosseus dorsalis pedis*, 111¹⁹⁻²⁹, 112¹⁻¹⁶⁻²¹⁻²⁴.
- *interosseus plantaris*, 111²¹⁻²⁴⁻²⁹, 112²⁴.
- *interosseus volaris*, 72¹⁰⁻¹⁴⁻²⁰, 73⁷⁻¹⁴⁻²⁰, 74¹²⁻¹⁵⁻¹⁹, 75⁵⁻⁸⁻¹⁰.
- *intertransversarius*, 13²³, 14³⁰, 34²⁹⁻⁴¹.
- *ischio cavernosus (erector penis vel clitoridis)*, 42⁴⁸, 43⁴², 48¹⁷⁻³⁸.
- *latissimus dorsi*, 22²², 23³²⁻⁸⁰, 24²³⁻⁵⁵, 25²³⁻⁵⁹, 26²⁶⁻⁵⁰, 27²⁴⁻⁵⁸, 28²¹, 29²², 30²⁹, 31²⁴, 32⁴³, 33²⁶, 34²⁷, 50¹³.
- *levator ani*, 41⁵⁰, 42²⁷⁻⁴⁵, 43⁴¹, 47²⁴⁻³⁴.
- *levator costarum*, 21³⁴⁻⁴⁷, 25⁴⁷.
- *levator palpebrae superioris*, 7¹², 8⁷⁹.
- *levator scapulae (levator anguli scapulae)*, 14²⁹⁻⁵³, 15²²⁻⁴⁰, 16²³⁻³⁷, 17²⁶⁻⁴¹, 18¹⁹⁻⁴³, 19²³, 20²⁶⁻⁴⁴.
- *levator veli palatini (levator palati)*, 11²³⁻⁷⁹, 12¹⁷⁻⁵⁴.
- *longissimus capitis (trachelomastoid)*, 12²⁴⁻⁴², 13²⁸⁻⁴³, 14³³⁻⁴⁸, 15²³⁻³⁷, 16²⁵⁻³⁴, 17²⁷⁻⁴⁰, 18²³⁻⁴⁰, 19⁴⁶, 21⁴⁷, 22⁴⁸.
- *longissimus cervicis (transversalis colli)*, 16³⁷, 17²⁷⁻⁴⁰, 18²¹⁻⁴², 19²², 20⁴², 21⁴⁸, 22⁴⁸.
- *longissimus dorsi*, 21⁴⁸, 22⁴⁶⁻⁵⁵, 23⁵¹⁻⁶¹, 24³⁴, 25³⁸, 26³⁴, 27³⁴, 28³⁴, 29⁴⁷, 30⁴¹, 31³², 32³¹, 33³⁰, 34⁴², 35³², 36³⁵.
- *longitudinalis superior linguae (superficial lingual)*, 13⁹².
- *longus capitis (rectus capitis anticus major)*, 10¹¹, 11²⁰⁻⁸¹, 12¹⁴⁻²⁴, 13¹³⁻⁵³, 14²², 15⁴¹, 16⁴², 17²⁰⁻⁴⁹, 18¹²⁻⁵¹, 19¹².
- Musculus (i) longus colli*, 13¹³⁻⁵³, 14²², 15²⁰, 16³⁸, 17⁴⁹, 18¹²⁻⁵¹, 19⁵⁸, 20⁵, 21¹³.
- *lumbricalis manus*, 72⁵, 73¹⁻⁴, 74²⁻⁵⁻²³⁻²⁶, 75⁵⁻⁸⁻¹⁰.
- *lumbricalis pedis*, 111¹¹⁻¹³, 112¹⁴.
- *masseter*, 10¹⁴⁻⁶⁸, 11¹⁹⁻⁷⁸, 12¹², 13²⁷, 14¹⁸⁻⁶³, 15¹⁰⁻⁵¹.
- *mentalis (depressor menti)*, 15².
- *multifidus (multifidus spinæ)*, 15³³, 16³¹, 17³⁵, 18³⁴, 19³¹⁻³⁸, 20³², 21⁴⁴, 22⁴⁹, 23⁵⁸, 24⁴⁹, 25³⁹, 26³⁹, 27³⁹, 29⁴⁴, 30⁴⁵, 31³⁹, 32³⁸, 33³⁷, 34³⁷, 35³⁸, 36³⁹, 37³³, 38³³, 39⁴².
- *mylohyoideus*, 14¹³⁻⁶⁷, 15⁷⁻⁵², 16⁵⁷, 17⁶⁷.
- *nasalis (compressor naris)*, 11⁹⁷.
- *nasalis [pars transversa]*. See PARS.
- *obliquus capitis inferior*, 13²⁷⁻⁴⁴, 14⁴⁵.
- *obliquus capitis superior*, 11⁶², 12²⁶.
- *obliquus externus abdominis*, 28¹³, 29⁹⁻⁷¹, 30¹²⁻⁸¹, 31⁶¹, 32¹⁹, 33¹⁵⁻⁶², 34¹²⁻⁶⁰, 35¹¹⁻⁵⁷, 36¹¹, 37¹¹.
- *obliquus inferior oculi*, 8¹⁸, 9⁸⁻⁵⁹.
- *obliquus internus abdominis*, 32¹⁵, 33¹²⁻²⁰⁻⁵⁸, 34¹⁰⁻⁶¹, 35¹²⁻⁵⁸, 36¹², 38⁸, 39⁶⁷, 40⁷⁻⁶⁵, 46⁵³.
- *obliquus superior oculi*, 7⁷, 8².
- *obturator externus*, 42⁷⁹, 43⁴⁵, 47⁷⁻¹⁵⁻⁴³, 48¹⁵⁻³⁴.
- *obturator internus*, 39²¹, 40²²⁻⁵⁰, 41⁴⁻²¹⁻⁵²⁻⁵⁶, 42²⁶⁻⁵⁶, 45¹⁸, 46¹⁵, 47¹²⁻⁴².
- *occipitalis*, 5²², 6³⁷, 7⁴¹, 8³⁶⁻⁵³, 9⁴²⁻⁵⁴.
- *omohyoideus*, 18⁴, 19⁵⁻⁶⁰, 20²⁰.
- *omohyoideus [venter inferior]*. See VENTER.
- *omohyoideus [venter superior]*. See VENTER.
- *opponens digiti quinti manus (opponens minimi digiti)*, 72⁷, 73⁹.
- *opponens digiti quinti pedis (opponens minimi digiti)*, 111²².
- *opponens pollicis*, 71²⁷, 72²⁸.
- *orbicularis oculi (orbicularis palpebrarum)*, 7⁶⁻⁹⁵, 8⁷¹, 9¹³⁻⁸¹, 10⁹, 11¹².
- *orbicularis oculi [pars palpebralis]*. See PARS.
- *orbicularis oris*, 12⁶⁸, 13⁶⁻⁶¹, 14⁷².
- *palmaris brevis*, 71⁴, 72⁵.
- *palmaris longus*, 59⁹, 60⁷, 61⁵, 62⁴, 63⁴, 64², 65², 66¹, 67¹, 68¹, 69²⁵, 70³², 71².
- *papillaris*, 27⁸².
- *pectineus*, 40⁶³, 41⁷⁻⁶⁶, 42¹⁰, 43³², 44¹², 46⁵⁰, 47⁸⁻⁵³, 48⁷⁻⁴⁰, 49¹²⁻³⁰, 76²³.
- *pectoralis major*, 22⁹, 23²⁰⁻⁹³, 24⁷⁻⁶⁷, 25⁹⁻⁷⁵, 26⁶, 27⁷⁸, 28⁷, 50²¹.
- *pectoralis minor*, 22¹⁶⁻⁸³, 23¹⁸⁻⁸³, 24¹²⁻⁶⁴, 25¹², 26¹².
- *peroneus brevis*, 94¹⁸, 95¹³, 96¹⁶, 97¹³, 98¹³, 99¹⁴, 100¹⁴, 101¹⁴, 102¹³, 103¹³, 104¹², 105¹², 106¹⁴, 107¹³, 108¹³, 109²⁰.
- *peroneus longus*, 93¹⁷, 94¹⁶, 95¹³, 96¹⁶, 97¹³, 98¹³, 99¹⁴, 100¹⁴, 101¹⁴, 102¹³, 103¹⁴, 104¹³, 105¹³, 106¹³, 107¹⁴, 108¹⁶, 109¹⁸, 110¹⁹, 111⁶.

- Musculus* (i) *peroneus tertius*, 106¹⁷, 107¹⁹, 108²², 109²³, 110²⁵.
- *pharyngopalatinus* (*palato-pharyngeus*), 12⁶, 13⁸, 14¹⁵, 15⁵⁰, 16¹⁰⁻⁴⁷, 17⁸.
- *piriformis*, 39³⁰⁻⁴³, 40²³⁻⁴⁸, 45²²⁻⁴⁹, 46¹⁰⁻⁴⁴.
- *plantaris*, 89¹⁸, 90²⁰, 91²⁰, 92¹⁴, 93⁹, 94⁷, 95⁷, 96⁷, 97⁸, 98⁶, 99⁷, 100⁷, 101⁸, 102⁸, 103⁸, 104⁸, 105⁹, 106⁸.
- *popliteus*, 92¹⁶, 93⁷, 94³, 95³.
- *procerus* (*pyramidalis nasi*), 71⁵⁹, 8⁹², 91.
- *pronator quadratus*, 67⁶, 68⁸, 69⁷.
- *pronator teres*, 58⁶, 59⁵, 60⁵, 61⁴, 62²⁸, 63²³, 64¹⁷.
- *psaos major*, 31²², 32²⁰, 33⁴², 34⁴⁴, 35²⁶⁻⁴⁵, 36⁴⁴⁻⁵⁰, 37⁵¹.
- *pterygoideus externus*, 9¹⁹, 10¹⁰⁻⁶⁹, 11²²⁻⁸⁰, 12¹¹⁻⁶⁰.
- *pterygoideus internus*, 11¹¹⁻⁸³, 12⁶¹, 13¹²⁻⁵⁵, 14²¹, 15¹².
- *pyramidalis*, 39¹, 40¹, 41², 45⁷¹, 46¹, 47³⁻⁵⁷.
- *quadratus femoris*, 42²⁸⁻⁵⁴, 43²⁶, 47¹⁶⁻⁴¹, 48¹⁶⁻³³.
- *quadratus labii inferioris* (*depressor labii inferioris*), 14⁷, 15³.
- *quadratus labii superioris* (*levator labii superioris*), 9⁹², 10³, 11⁹⁻⁹⁵.
- *quadratus labii superioris* [caput angulare] (*levator labii superioris alaeque nasi*). See CAPUT.
- *quadratus labii superioris* [caput infraorbitale]. See CAPUT.
- *quadratus lumborum*, 30⁵³, 32⁴², 33²⁷⁻⁴⁴, 34²⁶, 35²⁰.
- *quadratus plantae* (*flexor accessorius*), 108¹², 109¹⁵, 110¹⁶.
- *quadriceps femoris* (*quadriceps extensor tendon*), 87¹⁹, 88¹, 89²¹.
- *rectus abdominis*, 28⁴, 29³⁻⁷⁸, 30⁹⁰, 31³⁻⁶⁹, 32⁴⁻⁶⁹, 33³⁻⁶⁹, 34³⁻⁷⁰, 35⁴⁻⁶⁹, 36³⁻⁷², 37², 38¹, 39³, 40³, 41¹, 45⁶⁸, 46³, 47².
- *rectus capitis anterior* (*rectus capitis anticus minor*), 11²⁰, 12²¹.
- *rectus capitis lateralis*, 11²⁶, 12²³⁻⁴⁴.
- *rectus capitis posterior major*, 12²⁸, 13³⁴, 14²⁰.
- *rectus capitis posterior minor*, 12⁵⁰, 13³⁵.
- *rectus femoris*, 40¹⁴⁻⁵⁹, 41¹³⁻⁵⁸, 42¹⁸⁻⁶⁵, 43¹⁵, 44²⁴, 45¹⁶⁻⁵⁷⁻⁶⁰, 46¹⁰, 47¹⁸, 48¹⁰, 49⁸, 76²⁷, 77²³, 78²¹, 79²⁰, 80¹⁸, 81²², 82¹⁹, 83¹⁹, 84²⁰, 85¹⁹, 86¹⁸.
- *rectus inferior oculi*, 9¹¹⁻⁸⁴.
- *rectus lateralis oculi* (*external rectus*), 8²⁰, 9⁸⁰.
- *rectus medialis oculi* (*internal rectus*), 8¹⁰.
- *rectus superior oculi*, 7¹², 8⁷⁷.
- *rhomboideus major*, 21²⁶, 22⁴³, 23⁴⁹, 24³², 25⁵⁰.
- *rhomboideus minor*, 20³⁰, 21¹⁹.
- Musculus* (i) *sartorius*, 39⁶¹, 40¹²⁻⁶⁰, 41¹², 42¹⁴, 43¹⁵, 44²⁷, 45⁵¹, 46⁵⁰, 47⁴⁹, 48⁸, 49⁷, 76²⁹, 77²⁶, 78²⁵, 79³, 80⁴, 81³, 82⁴, 83⁷, 84⁴, 85⁷, 86³, 87⁸, 88⁸, 89⁸, 90¹⁰, 91¹¹, 92³, 93².
- *scalenus anterior*, 17²¹⁻⁴⁸, 18¹³⁻⁴⁸, 19¹⁸, 20¹²⁻⁵⁷, 21⁸⁻⁷⁴.
- *scalenus medius*, 14²⁰⁻⁵², 15²¹⁻⁴⁰, 16²²⁻²⁸, 17²⁴⁻⁴⁴, 18¹⁶, 19²⁰, 20¹⁵, 21¹¹⁻⁶⁹.
- *scalenus posterior*, 19²⁰, 20⁴⁵.
- *semimembranosus*, 43²⁹, 44⁶, 48¹⁸⁻³², 49¹⁵⁻²⁷, 76¹², 77¹³, 78⁷, 79¹¹, 80⁷, 81¹¹, 82⁹, 83¹⁰, 84⁸, 85¹¹, 86⁹, 87¹², 88¹⁰, 89¹², 90¹², 91¹², 92⁴.
- *semispinalis capitis* (*complexus*), 10³⁷, 11³², 12³⁶, 13³¹, 14²⁶⁻⁴¹, 15²⁶, 16²⁶, 17³⁸, 18²⁶⁻³⁵, 19²⁹⁻⁴⁹, 20²³⁻³⁹, 21³⁹⁻⁴⁵.
- *semispinalis cervicis* (*semispinalis colli*), 15²⁸⁻³¹, 16³¹, 17³¹⁻³⁶, 18²⁷⁻³³, 19³⁰⁻³⁹, 20³³⁻³⁹.
- *semispinalis dorsi*, 22⁴⁹, 24⁴⁰, 25⁵⁹, 26⁵⁹, 27⁵⁹, 29⁴⁴, 30⁴⁵.
- *semitendinosus*, 43³⁰, 44⁵, 48¹⁸⁻³¹, 49¹⁶⁻²⁶, 76¹¹, 77¹⁴, 78⁸, 79¹², 80⁹, 81¹², 82⁷, 83¹¹, 84⁹, 85¹², 86¹⁰, 87¹¹, 88⁹, 89¹¹, 90¹³, 91¹², 92⁷, 93².
- *serratus anterior* (*serratus magnus*), 21²⁸⁻⁵³, 22³⁷⁻⁶⁵, 23²⁹⁻⁶⁹, 24¹⁸⁻⁶¹, 25⁶¹, 26²⁰, 27¹⁸⁻⁶³, 28⁶⁰, 29¹⁵, 30²¹.
- *serratus posterior inferior*, 28²⁵⁻⁵¹, 29⁵³, 30⁶⁰, 32⁴⁴.
- *serratus posterior superior*, 20²⁷, 21²¹, 22⁶¹.
- *soleus*, 92¹⁵, 93¹⁴, 94¹¹, 95¹¹, 96⁹, 97⁶, 98⁹, 99⁸, 100⁹, 101¹⁰.
- *sphincter ani externus*, 43²⁶, 48²³, 49²³.
- *sphincter ani internus*, 43²⁷, 48²⁶, 49²⁰.
- *spinalis capitis*, 12²².
- *spinalis cervicis* (*spinalis colli*), 19³¹⁻³⁸, 20³², 21⁴⁴.
- *spinalis*, 23³⁸, 29⁴⁴.
- *spinalis dorsi*, 22⁵⁰, 23⁵⁹, 24³⁶, 25⁴², 26⁴¹, 27³⁹, 30⁴⁵, 31³⁹, 32³⁸.
- *splenius capitis*, 10²⁹⁻⁴⁹, 11⁴¹⁻⁵⁹, 12²⁵, 13²⁹⁻⁴², 14³⁵⁻⁴⁹, 15³⁵, 16²⁵, 17³⁷, 18²⁵⁻³⁶, 19²⁸⁻⁴¹, 20⁴⁰.
- *splenius cervicis* (*splenius colli*), 14²⁹⁻⁵³, 15²⁰⁻³⁹, 16²⁴⁻³⁵, 17²⁸⁻³⁹, 18²³⁻³⁹, 19²⁵, 20¹⁰, 21³⁷.
- *sternocleidomastoideus*, 10²⁹, 11⁶⁰, 12²⁴⁻⁴³, 13²⁴⁻⁴⁵, 14²¹⁻⁵¹, 15²²⁻³⁸, 16¹⁹, 17¹⁹⁻⁴⁶, 18¹⁴, 19¹¹, 20¹¹⁻³⁴, 21², 22³.
- *sternohyoideus*, 18⁴, 19⁶⁻⁶⁵, 20⁶⁶⁻⁶⁹, 21², 22²⁹³, 23²⁷.
- *sternothyroideus*, 20⁴⁻⁶², 21⁷⁷, 22²⁹⁵, 23¹⁰⁰.
- *styloglossus*, 13¹⁶, 14¹⁷⁻⁶⁴, 15¹¹⁻⁵³.
- *stylohyoideus*, 13¹⁶, 14²⁴⁻⁶⁰, 15¹³⁻⁴⁸, 16¹³⁻⁴⁸, 17⁴⁻⁶³.
- *stylopharyngeus*, 12¹⁹, 13¹⁶, 14¹⁹⁻⁶⁰, 16¹⁰⁻⁴⁷, 17⁸.
- *subclavius*, 20¹⁹⁻⁵⁰, 21¹⁴⁻⁶⁰, 22⁸⁻⁸⁹.
- Musculus* (i) *subscapularis*, 21²⁷⁻⁵⁴⁻⁶³, 22³⁴⁻⁶⁸⁻⁷⁸, 23³³⁻⁷¹, 24²⁷, 25⁵⁵.
- *supinator* (*supinator brevis*), 60²¹, 61¹⁶⁻²⁴, 62²⁰, 63¹⁸.
- *supraspinatus*, 20¹⁰⁻⁵¹, 21⁵⁶.
- *temporalis*, 4⁹⁻⁴², 5⁸⁻⁴³, 6¹⁰⁻⁷⁴, 7²⁷⁻⁸³, 8²⁷⁻⁷⁰, 9²²⁻⁷¹, 10¹¹⁻⁷⁰, 11¹⁷⁻⁸⁵, 12¹³⁻⁵⁹.
- *tensor fasciae latae* (*tensor vaginae femoris*), 38⁵⁸, 39¹⁴⁻⁶⁰, 40⁵⁸, 41⁵⁸, 42¹⁹⁻⁶³, 43⁵⁵, 44²², 45¹³, 46⁴⁸, 47¹¹, 48¹¹, 49³¹, 76²².
- *tensor veli palatini* (*tensor palati*), 11¹⁸⁻⁸⁶, 12⁶⁴.
- *teres major*, 23³¹⁻⁷⁹, 24²³, 25²⁷⁻⁵³, 50¹⁵.
- *teres minor*, 22²⁵⁻²⁸⁻⁷⁴, 23³⁴, 24⁵².
- *thyreoarytenoideus*, 19⁶³.
- *thyreochoyoideus*, 17⁶⁻⁶⁰, 18⁵³, 19⁴.
- *tibialis anterior*, 93²¹, 94¹⁸, 95¹⁷, 96²⁰, 97¹⁹, 98¹⁰, 99¹⁹, 100²⁰, 101²⁰, 102¹, 103¹, 104¹, 105¹, 106¹, 107², 108², 109³, 110².
- *tibialis posterior*, 93¹⁸, 94², 95¹, 97², 99¹³, 100², 101⁴, 102⁵, 103⁴, 104⁴, 105⁴, 106⁴, 107⁵, 108⁵, 109⁵.
- *transversus abdominis* (*transversalis*), 30⁷, 31⁷⁻⁶⁷, 32⁹, 33⁹⁻⁶⁴, 34¹⁷⁻⁶², 35¹³⁻⁵⁹, 36¹⁸⁻⁶⁰, 37¹⁰, 38¹²⁻⁶³, 39⁸, 45⁶⁴, 46³³.
- *transversus linguae*, 13³.
- (*transversus menti*) (*transverse fibers of the trianguluris*), 16¹.
- *transversus perinei superficialis* (*transversus perinei*), 43³⁵.
- *transversus thoracis* (*trianguluris sterni*), 26⁷³, 27⁷⁹, 28², 29⁷⁹.
- *trapezius*, 10³⁸, 11⁴⁸, 12²⁷, 13³³, 14⁴³, 15²², 16³², 17³⁷, 18²⁴⁻³⁷, 19²⁰, 20²¹⁻²²⁻⁴⁸, 21³⁰⁻⁵², 22⁴⁵, 23⁴⁸⁻⁶², 24³⁷, 25⁴⁶, 26⁴², 27⁴².
- *trianguluris* (*depressor anguli oris*), 14⁵⁻⁷⁴, 15⁵⁻⁵⁶.
- *triceps brachii* (*triceps*), 54¹⁰, 55⁸, 56⁸, 57⁸⁻⁸, 58¹².
- *triceps brachii* [caput medialis] (*inner head*). See CAPUT.
- *triceps brachii* [caput laterale] (*outer head*). See CAPUT.
- *triceps brachii* [caput longum]. See CAPUT.
- *uvula*, 13².
- *vastus intermedius* (*crureus*), 42²³⁻⁶⁰, 44¹⁷, 48³⁷, 49¹⁰⁻³³, 76²⁵, 77²⁴, 78¹⁹, 79²¹, 80¹⁵, 81²¹, 82¹⁷, 83¹⁸, 84¹⁹, 85¹⁸.
- *vastus lateralis* (*vastus externus*), 42²¹⁻⁶¹, 43²¹, 44¹⁸, 48¹²⁻³⁸, 49¹¹⁻³⁰, 76²¹, 77²¹, 78¹⁹, 79¹⁷, 81¹⁹, 82¹⁶, 83¹⁷, 84¹⁷, 85¹⁷, 86¹⁶, 87¹⁸, 88¹⁶, 89¹⁹, 90²⁰.
- *vastus medialis* (*vastus internus*), 42²⁴, 44¹³, 49¹⁰⁻³², 76²⁵, 77²⁴, 78¹⁹, 79²¹, 80¹⁹, 82¹, 83¹, 84¹, 85², 86², 87³, 88³, 89⁴.
- *vocalis* (*thyreoarytenoid internus*), 19¹.

- Musculus (i) zygomaticus (*zygomaticus major*), 10¹², 11¹⁵, 12¹⁰⁻⁶².
Myocardium, 26⁸, 27⁸⁰.
- Naris, 11⁹⁸.
Nervus (i) abducens (*sixth nerve*), 9⁷⁴, 10⁵³.
—accessorius (*spinal accessory*), 11³¹⁻⁴³⁻⁷¹, 12²⁰⁻³⁷⁻⁴⁸, 13¹⁸⁻⁵⁰, 14²⁴⁻⁵⁶, 15¹⁹⁻⁴⁵, 16²⁰⁻⁴⁰, 17²⁵⁻⁴⁷, 18¹⁸⁻⁴³.
—accessorius [ramus externus]. See RAMUS.
—acustorius, 9³³⁻⁵⁹, 10⁵².
—acusticus [radix], 10⁴⁵.
—alveolaris inferior (*alveolar of mandible*), 12¹⁶⁻⁵⁵, 13¹⁴⁻⁵³, 14¹⁶, 15⁹⁻⁵⁴.
—auricularis magnus, 15¹⁸⁻⁴², 16²⁰⁻³⁹, 17²²⁻⁴⁴, 18¹⁵⁻⁴⁴.
—auriculotemporalis, 9²⁸, 11²⁵⁻⁷³.
—axillaris (*circumflex*), 22³⁰⁻⁷⁰.
—cardiacus superior, 22².
—cervicalis, 13³², 14³⁴⁻⁴⁶, 15²⁴⁻³⁶⁻⁴¹, 16²¹⁻³⁹, 17²³⁻²⁴⁻⁴³⁻⁴⁵, 18¹⁶⁻¹⁸⁻⁴⁰⁻⁴³, 19¹⁵⁻¹⁷, 20¹³⁻¹⁴⁻³⁷⁻⁵⁵.
—cutaneus antibrachii dorsalis (*cutaneous branch of musculo-spiral*), 53¹⁷, 54¹³, 55¹⁰, 56¹⁰, 57¹¹, 58¹³, 59²⁰.
—cutaneus antibrachii lateralis (*cutaneous branch of musculo-cutaneous*), 54¹, 55¹⁷, 56¹⁶, 57¹⁷, 58²², 59²⁰, 60²⁰, 61²⁸, 62²⁰, 63²⁷, 64²³.
—cutaneus antibrachii medialis (*internal cutaneous*), 50⁵, 51⁵, 52¹, 53⁴, 54⁴.
—cutaneus antibrachii medialis [ramus ulnaris]. See RAMUS.
—cutaneus antibrachii medialis [ramus volaris]. See RAMUS.
—cutaneus brachii medialis (*lesser internal cutaneous or N. of Wrisberg*), 50¹⁴, 51¹⁴.
—cutaneus dorsalis medialis (*internal dorsal cutaneous branch of musculo-cutaneous*), 102¹⁷, 104¹⁸, 105¹⁷, 106¹⁹.
—cutaneus dorsalis intermedius (*external dorsal cutaneous branch of musculo-cutaneous*), 102¹⁷, 103¹⁷, 104¹⁸, 105¹⁵, 106¹⁶.
—cutaneus femoris lateralis (*external cutaneous nerve*), 35²⁸, 36²⁶, 37¹⁸⁻³⁰, 38¹⁶⁻⁵⁵, 39¹²⁻⁶², 40¹³, 41¹³, 42⁶⁶, 43¹⁴, 46⁹, 47¹⁰, 48⁹, 76²⁴, 77²², 78²⁰, 79¹⁸.
—cutaneus femoris lateralis [ramus] (*external cutaneous nerve*), 45¹¹, 78¹⁸.
—cutaneus femoris posterior (*small sciatic*), 42³¹⁻⁵¹, 43²⁷⁻⁴⁷, 44⁷, 46¹⁹, 47²⁰⁻³⁹, 48¹⁹, 49¹⁷⁻²⁵, 76¹⁴, 77¹⁶, 78⁹, 79¹³, 80⁸, 81¹³, 82⁸, 83¹³, 84¹¹, 85¹³, 86¹¹, 87¹³, 88¹¹, 90¹⁶, 91¹⁶.
Nervus (i) cutaneus surae lateralis (*communicans fibularis*), 89¹⁷, 90²⁰, 91²¹, 92¹³, 93¹², 94¹⁰, 95¹⁰, 96¹¹, 97¹⁰.
—cutaneus surae medialis (*communicans tibialis*), 90¹⁹, 91¹³, 92¹⁰, 93¹¹, 94⁹, 95⁹, 96⁹, 97¹⁰.
—digitalis dorsalis pedis (*digital branch of musculo-cutaneous*), 113¹⁸.
—digitalis plantaris communis (*digital branch of internal plantar*), 111¹⁰, 113¹³.
—digitalis volaris communis (*palmar digital branches of median nerve*), 73³⁻⁵⁻²⁸⁻²⁹, 74¹⁻⁷⁻²³, 75¹⁴.
—dorsalis penis, 42⁷⁷, 43¹⁻⁷¹.
—dorsalis scapulae (*posterior scapular*), 21³³.
—ethmoidalis posterior, 8⁹.
—facialis, 9³²⁻⁶⁰, 10²⁴⁻⁵²⁻⁵⁶, 11³²⁻⁶⁹, 12²²⁻⁴⁷, 13²⁰⁻⁴⁹, 14²³.
—facialis [ramus colli]. See RAMUS.
—femoralis (*anterior crural*), 36²⁹, 37²¹⁻⁴⁹, 38¹⁸⁻⁵⁴, 39⁶³, 40¹², 41¹¹⁻⁶¹, 42¹⁵⁻⁶⁸, 43¹⁶⁻⁵⁹, 45⁶⁰, 46⁴⁹, 47⁴⁸.
—femoralis [rami], 43¹³⁻¹⁸⁻⁵⁸, 48³⁰, 49⁸⁻³⁴.
—femoralis [rami cutanei anteriores]. See RAMI.
—femoralis [rami musculares]. See RAMI.
—frontalis, 7¹⁰, 8¹⁶.
—frontalis [ramus], 7⁹¹.
—genitofemoralis (*genito - crural*), 33²⁹⁻⁴³, 34²⁰, 35²³, 36²².
—glossopharyngeus, 10³¹, 11³⁰⁻⁷¹, 12¹⁸⁻⁵⁰, 13⁵², 14²²⁻⁵⁶.
—gluteus inferior, 45²⁰⁻⁴⁷, 46³⁸.
—hemorrhoidalis inferior, 43⁴⁰.
—hypoglossus, 10³², 11³⁷⁻⁴³⁻⁵⁸⁻⁶⁵, 12²⁰⁻⁴⁸, 13¹⁸⁻⁴⁸, 14²⁷⁻⁵⁷, 15¹⁷⁻⁴⁶, 16⁸⁻¹⁵⁻⁴⁴⁻⁵².
—hypoglossus [ramus], 15⁶¹.
—hypoglossus [ramus descendens]. See RAMUS.
—iliohypogastricus, 35²¹⁻⁵⁰, 36⁵⁵, 37¹².
—ilioinguinalis, 35²¹⁻⁴⁹, 36²³, 37¹⁴.
—infraorbitalis, 10⁸⁻⁷², 11⁸⁻⁹⁴.
—intercostalis, 21⁹⁻³⁶, 22⁴¹, 23⁴⁴, 25⁴⁵, 26³¹⁻³⁷⁻⁴⁸, 27²⁷⁻⁵⁰⁻⁵⁵, 28³⁰, 29³³⁻⁴⁵, 30¹⁹, 31⁴⁴, 32²⁵, 34²⁵⁻⁵⁰, 35¹⁸, 36¹³⁻⁶¹, 37⁸.
—interosseus antibrachii dorsalis (*posterior interosseous*), 62¹⁰, 63¹⁴.
—interosseus antibrachii volaris (*anterior interosseous*), 62², 63²⁸, 64¹³, 65²³, 66¹⁴, 67⁹.
—ischiadicus (*great sciatic*), 40²⁴⁻⁴⁷, 41²²⁻⁵¹, 42²⁹⁻⁵³, 43²⁷⁻⁴⁸, 44⁹, 45²⁴⁻⁴⁷, 46⁴⁰, 47¹⁸⁻⁴⁰, 48³², 49¹⁵⁻²⁷, 76¹⁵, 77¹⁸, 78¹¹, 79¹⁴, 80¹⁰, 81¹⁵, 82¹⁰, 83¹⁴, 84¹², 85¹⁵, 86¹².
—lacrimalis, 7¹⁴.
—laryngeus inferior, 20²⁻⁶⁴.
—laryngeus superior, 15¹⁶⁻⁴⁶, 16¹⁶⁻⁴⁴.
—laryngeus superior [ramus internus]. See RAMUS.
Nervus (i) laryngeus superior [ramus externus]. See RAMUS.
—lingualis, 12¹⁵⁻³⁶, 13¹⁰⁻⁵⁶, 14¹⁴⁻⁶⁵, 15⁸⁻⁵⁵⁻⁵⁹.
—lingualis [ramus], 14¹⁻⁷⁶, 15⁴.
—lumbalis, 32³¹⁻⁴⁰, 33²⁷⁻³¹⁻⁴¹⁻⁴⁵, 34²⁵⁻³⁰⁻³²⁻⁴⁰⁻⁴⁷, 35²⁰⁻³⁴, 36³¹⁻³⁸, 37²³.
—lumboinguinalis (*crural branch of genitocrural nerve*), 34⁴⁶, 35⁴⁷, 36⁵⁵, 37⁵⁶, 38⁵⁸, 39¹²⁻⁶⁴, 76⁴.
—mandibularis (*inferior maxillary*), 10¹⁵⁻⁶⁶, 11²¹⁻⁸².
—massetericus, 12¹⁴⁻⁵⁷.
—maxillaris (*superior maxillary nerve*), 10⁷².
—medianus, 22¹⁸⁻⁸², 23²¹⁻⁸², 50⁷, 51⁶, 52³, 53³, 54³, 55³, 56³, 57³, 58², 59⁵, 60³, 61⁹, 62⁴, 63², 64¹, 65¹, 66²⁹, 67²⁵, 68²⁵, 69²⁴, 70³¹, 71¹, 72¹.
—mentalis, 14⁷⁻⁷³, 15⁵⁻⁵⁸, 16².
—musculocutaneus, 22⁹⁰, 23⁸², 50², 51², 52¹, 53¹.
—nasociliaris (*nasal*), 8¹⁵⁻⁸³.
—obturatorius, 36³⁰, 37²³, 38⁵⁰, 39¹⁷⁻⁵⁶, 40¹⁵, 41⁶¹, 45¹⁵⁻⁵⁴, 46¹¹, 47⁹.
—obturatorius [rami anteriores]. See RAMI.
—obturatorius [ramus posterior]. See RAMUS.
—occipitalis major, 11⁴⁶⁻⁵⁴, 12⁵⁵, 13³⁶, 14³⁷⁻⁴⁵.
—occipitalis minor, 12²⁷, 13³⁰, 14³⁴, 15²⁴, 16²⁴⁻⁵⁶.
—oculomotorius, 8²⁵⁻⁶².
—oculomotorius [ramus inferior]. See RAMUS.
—ophthalmicus, 9⁷⁹.
—opticus, 8⁸.
—palatini, 10⁷.
—peroneus communis (*external popliteal*), 87¹⁴, 88¹², 89¹⁷, 90²¹, 91²³, 92¹⁵.
—peroneus profundus (*anterior tibial*), 93¹⁸, 94¹⁵, 95¹³, 96¹⁷, 97¹⁸, 98¹⁵, 99¹⁸, 100¹⁸, 101³, 102¹⁸, 103²⁰, 104²¹, 105²⁰, 106¹⁸, 107²³, 108²⁴, 109²⁶, 110², 111², 112².
—peroneus superficialis (*musculo-cutaneous*), 93¹⁶, 94¹⁴, 95¹⁴, 96¹⁵, 98¹⁴, 99¹⁶, 100¹⁶, 101¹⁷.
—petrosus superficialis major, 9²⁹.
—phrenicus, 19¹⁵⁻⁵⁶, 20⁹⁻⁵⁶, 21⁷⁻⁷³, 22⁸⁻⁹⁶, 23⁵, 24¹¹⁻⁶⁸, 25⁶⁹, 26¹⁷⁻⁶⁵, 27¹⁷⁻⁷¹.
—plantaris lateralis (*external plantar*), 108¹¹, 109¹⁵, 110¹⁷.
—plantaris medialis (*internal plantar*), 108⁹, 109¹¹, 110¹⁰⁻¹².
—plantaris medialis [ramus profundus]. See RAMUS.
—pudendus (*pubic*), 40²⁹⁻⁴³, 41²⁷⁻⁴⁶, 42³⁵⁻⁴⁹, 45²⁶⁻⁴⁴, 46²¹, 47²¹.
—radialis (*musculo-spiral*), 22³²⁻⁶⁹, 23²²⁻⁷⁷, 50¹², 51¹², 52¹³, 53¹⁴, 54¹⁴, 55¹⁴, 56¹³, 57¹⁴, 58¹⁹, 59²⁶.

- Nervus (i) radialis [ramus profundus].
See RAMUS.
 —recurrens (*recurrent laryngeal*), 21²-7⁸, 22⁹⁹, 23¹⁰¹.
 —sacralis, 36⁵⁹, 37⁶², 38⁵⁹⁻⁶⁴⁻⁶⁷, 39⁵⁸⁻⁶⁶⁻⁶⁹⁻⁷¹.
 —saphenus (*long saphenus*), 43⁶¹, 44²⁵, 76²¹, 77¹, 78¹, 79², 80², 81², 82³, 83⁴, 84⁵, 85⁵, 86⁴, 87⁶, 88⁵, 89⁷, 90⁷, 91⁸, 92⁵, 93⁵, 94⁴, 95⁴, 96³, 97³, 98³, 99³, 100³, 101⁴.
 —spermaticus externus (*genital branch of genito-crural*), 34¹⁶, 35¹⁶, 36³⁴, 37¹⁶⁻⁵⁶, 38⁶⁹, 39⁶².
 —spinalis, 32⁴⁵.
 —splanchnicus major, 25³⁵⁻⁴¹, 26³⁵⁻⁴⁴, 27³⁵⁻⁴⁶, 28³²⁻⁴⁷, 29³⁷⁻⁴⁹, 30³⁷⁻⁵⁷.
 —splanchnicus minor, 27³⁷⁻⁴⁵, 28³¹⁻⁴⁵, 29³⁵, 30³⁷⁻⁵⁶, 31⁴¹.
 —suboccipitalis [radix] (*first cervical*), 12²⁹.
 —supraclavicularis, 19¹⁹⁻⁴⁸⁻⁴⁹, 20²¹.
 —supraorbitalis, 7⁹².
 —suprascapularis, 21⁵⁸.
 —suralis (*short saphenus*), 98⁸, 99¹⁹, 100¹⁹, 101¹³, 102¹⁹, 103¹⁹, 104¹¹.
 —thoracalis anterior (*internal anterior thoracic*), 22¹⁶, 23⁴⁷⁻⁸⁸.
 —thoracalis longus (*nerve of Bell*), 21¹²⁻⁶⁸, 22¹⁴⁻³⁶⁻⁶⁶, 23³⁸⁻⁷¹, 24²¹⁻⁵⁶, 25²², 27²²⁻⁶².
 —thoracodorsalis (*long subcapular*), 22¹⁷, 23³⁶⁻⁸⁴, 24²¹⁻⁵⁶, 26²³⁻⁵⁸, 27²⁶⁻⁶⁹.
 —thoracodorsalis [ramus], 26²⁴⁻⁵⁶.
 —tibialis (*internal popliteal*), 87¹⁴, 88¹², 89¹⁵, 90¹⁸, 91¹⁹, 92¹², 93⁹, 94⁸, 95⁶, 96⁵, 97¹¹, 98⁵, 99⁶, 100⁶, 101⁵, 102⁷, 103⁷, 104⁷, 105⁷, 106⁹, 107¹⁹.
 —trigemini (*fifth nerve*), 9⁶².
 —trigemini [portio minor]. *See* PORTIO.
 —trochlearis (*pathetic*).
 —ulnaris, 22³²⁻⁶⁹, 23²²⁻⁷⁷, 50⁸, 51⁹, 52⁶, 53⁷, 54⁸, 55⁷, 56⁸, 57⁸, 58⁵, 59¹², 60¹¹, 61⁹, 62⁷, 63⁶, 64⁵, 65⁵, 66⁴, 67⁵.
 —ulnaris [ramus dorsalis manus]. *See* RAMUS.
 —ulnaris [ramus profundus]. *See* RAMUS.
 —ulnaris [ramus volaris manus]. *See* RAMUS.
 —vagus, 10³¹, 12²¹⁻⁴⁹, 13²¹⁻⁴⁸, 14²⁸⁻⁵⁵, 15¹⁸⁻⁴⁴, 16¹⁹⁻⁴¹, 17¹⁹⁻⁴⁹, 18¹³⁻⁴⁸, 19¹¹⁻⁵⁴, 20⁷⁻⁵⁸, 21⁶⁻⁷⁵, 22⁴⁻⁹⁶, 23⁹⁸, 24²⁸⁻⁴⁹.
 — [ramus bronchialis]. *See* RAMUS.
 — [ramus pharyngeus]. *See* RAMUS.
 Nodus vermis, 9⁴⁴.
 Nucleus amygdalæ, 8⁶⁶.
 —anterior thalami, 6⁷⁹.
 —caudatus, 5¹⁸⁻³⁹.
 —caudatus [cauda]. *See* CAUDA.
 —dentatus, 10⁴⁴.
 —funiculi gracilis (*nucleus of column of Goll*), 11⁴⁷⁻⁹¹.
 Nucleus hypothalamicus [Corpus Luysi] (*corpus subthalamicum*), 7³².
 —lateralis thalami, 6²⁴⁻⁶⁴, 7¹¹.
 —medialis thalami, 6²⁸⁻⁵⁷, 7²².
 —ruber tegmenti (*red nucleus*), 7³², 8⁵⁰.
 (Esophagus, 20⁶⁷, 21⁷⁹, 22¹⁰⁰, 23⁵⁷, 24¹⁰, 25⁴³, 26⁴⁷, 27⁴⁷, 28⁵⁵.
 Olecranon, 59¹⁹.
 Oliva (*olivary body*), 11⁴⁷.
 Omentum majus, 33³⁷, 35⁵³⁻⁶², 36³⁷, 38⁶².
 Operculum, 5¹¹, 6⁶⁸.
 Orificium ureteris, 46⁹⁻⁴⁸.
 —urethræ internum, 41¹, 47⁴.
 Os capitatum, 71¹⁶.
 —coccygis (*coccyx*), 41³⁷, 45²⁷, 46²⁹.
 —coccygis [processus transversus]. *See* PROCESSUS.
 —cuboideum, 109²¹, 110²⁴.
 —cuneiforme primum (*internal cuneiform*), 110⁷.
 —cuneiforme secundum (*middle cuneiform*), 110⁴.
 —cuneiforme tertium (*external cuneiforme*), 110⁷.
 —ethmoidale [lamina perpendicularis]. *See* LAMINA.
 —frontale, 1²⁰, 2²⁻²², 3⁹⁻²⁵, 4⁷⁻⁴⁸, 5⁶, 6⁷, 7⁹⁻⁸⁸, 8⁹¹.
 —frontale [processus zygomaticus]. *See* PROCESSUS.
 —frontale [pars orbitalis]. *See* PARS.
 —hamatum (*unciform*), 71¹¹.
 —hyoideum [cornu majus]. *See* CORNU.
 —hyoideum [cornus]. *See* CORPUS.
 —ilium, 35²⁴, 36²⁹⁻⁵³, 37²⁸, 38²⁹, 39¹⁶⁻⁴⁵, 40⁶², 41¹⁴, 45⁵⁶.
 —ischii [ramus inferior]. *See* RAMUS.
 —lacrimale, 9⁹⁰.
 —lunatum (*semilunar*), 70⁹.
 —metacarpale, 71²³, 72¹¹⁻¹⁵⁻²¹⁻²⁷, 73¹⁰⁻¹³⁻¹⁶⁻¹⁹.
 —metacarpale [capitulum]. *See* CAPITULUM.
 —metatarsale, 110²³, 111⁵⁻²³⁻²⁵⁻²⁹, 112⁵⁻²³⁻²⁵, 113³⁻⁸⁻¹²⁻¹⁵.
 —multangulum majus (*trapezium*), 71²².
 —multangulum minus (*trapezoid*), 71¹⁸.
 —nasale, 9⁹⁶.
 —naviculare manus (*scaphoid*), 70²¹.
 —naviculare pedis (*scaphoid*), 109⁴.
 —occipitale, 5²³, 6¹¹, 7¹⁵⁻⁵⁶, 8¹⁰, 10¹⁷, 11⁵⁰.
 —occipitale [pars basilaris]. *See* PARS.
 —parietale, 1⁹, 2⁸⁻¹⁹, 3¹⁷, 4²²⁻³², 5¹⁷⁻³³, 6²⁷⁻⁶³, 7⁶⁷, 8³⁷.
 —pubis, 41², 47⁵⁵.
 —pubis [ramus superior]. *See* RAMUS.
 —pubis [ramus inferior]. *See* RAMUS.
 —sacrum [pars lateralis]. *See* PARS.
 —sesamoideum pedis, 113⁹.
 Os sphenoidale.
 —sphenoidale [ala magna]. *See* ALA.
 —sphenoidale [corpus]. *See* CORPUS.
 —sphenoidale [processus pterygoideus]. *See* PROCESSUS.
 —sphenoidale [spina angularis]. *See* SPINA.
 —temporale, 6¹⁸, 7²⁵⁻⁷⁷, 8²⁶⁻⁶⁵, 9²⁶⁻⁵⁸⁻⁶⁹, 10²⁹, 11⁶³.
 —temporale [apex pyramidis]. *See* APEX.
 —temporale [pars mastoidea]. *See* PARS.
 —temporale [pars petrosa]. *See* PARS.
 —temporale [pars tympanica]. *See* PARS.
 —temporale [processus zygomaticus]. *See* PROCESSUS.
 —triquetrum (*cuneiform*), 70¹².
 —zygomaticum (*malar*), 8²¹, 10⁹, 11¹⁴.
 —zygomaticum [facies orbitalis]. *See* FACIES.
 —zygomaticum [processus frontosphenoidalis]. *See* PROCESSUS.
 —zygomaticum [processus temporalis]. *See* PROCESSUS.
 Ostium pharyngicum tubæ auditivæ (*pharyngeal opening of Eustachian tube*), 11⁷.
 —tympanicum tubæ auditivæ (*tympanic opening of Eustachian tube*), 10⁹².
 Ovarium, 45¹⁷⁻⁵².
 Palatum durum (*hard palate*), 12¹.
 Pancreas, 30⁷⁴.
 — [caput]. *See* CAPUT.
 — [corpus]. *See* CORPUS.
 Panniculus adiposus (*subcutaneous adipose tissue*), 22²⁷⁻⁷⁵, 28⁸, 35⁶⁸, 42¹⁴, 49²².
 Papilla renalis, 32²³⁻⁴⁸.
 Pars anterior vaginæ (*anterior wall*), 47²¹.
 — posterior vaginæ (*posterior wall*), 46²¹, 47²⁰.
 Pars analis recti (*anal canal*), 42⁴⁵.
 —basilaris ossis occipitalis, 10²²⁻⁷⁵, 11⁴⁴.
 —cardiaca ventriculi, 28³⁷.
 —cavernosa urethræ, 43⁶⁴⁻⁶⁹.
 —centralis ventriculi lateralis cerebri, 5³⁻¹⁶.
 —descendens duodeni, 32¹², 33¹³.
 —frontalis capsulæ internæ (*anterior limb of internal capsule*), 6⁸⁻⁷⁷, 7⁸⁸.
 —frontalis radiationis corporis callosi, 3⁴, 4⁴⁻⁴¹.
 —inferior duodeni, 31²², 33⁴, 34¹³.
 —laryngea pharyngis, 17³, 18⁶, 19⁶².
 —lateralis ossis sacri, 37²⁴, 39²⁹, 40³⁰.
 —mastoidea ossis temporalis, 9²⁵.
 —nasalis pharyngis, 11³, 13¹.
 —occipitalis capsulæ internæ (*posterior limb of internal capsule*), 6²²⁻⁵⁹.

- Pars occipitalis radiationis corporis callosi, 3¹⁹, 4²¹⁻²⁹.
 — oralis pharyngis, 14⁷³, 15⁵.
 — orbitalis gyri frontalis inferioris, 7⁸⁷.
 — orbitalis ossis frontalis, 8⁸⁵.
 — palpebralis m. orbicularis oculi, 7¹¹.
 — parietalis radiationis corporis callosi, 3⁷, 4¹⁶⁻³⁷.
 — petrosa ossis temporalis, 9³⁰.
 — prostatica urethrae, 42³⁹.
 — pylorica ventriculi, 31⁷¹, 32⁷⁰.
 — superior duodeni, 31⁶, 32².
 — transversa m. nasalis (*compressor naris*), 10⁸⁰, 11².
 Patella, 89¹, 90³⁰.
 Pedunculus cerebri, 8⁶¹.
 Pelvis renalis, 32²³.
 Pericardium (*parietal layer of pericardium*), 23², 24¹⁸, 25⁴⁻³⁴, 27⁹⁻⁵³, 28⁷².
 Pericranium, 1¹⁸.
 Peritoneum, 29⁶², 40³⁸, 45³³.
 — parietale, 27⁶⁵, 33⁶⁻⁶⁷, 34¹⁹, 35⁹⁻⁷⁰.
 — viscerale, 33⁷, 34⁹.
 Phalanges digitorum manus, 73²⁵, 75³⁻⁶⁻¹².
 — digitorum pedis, 113¹⁶.
 Pharynx, 12¹, 16⁶.
 — [pars laryngea]. See PARS.
 — [pars nasalis]. See PARS.
 — [pars oralis]. See PARS.
 Pia mater encephali, 1⁷.
 Planus popliteus femoris, 87¹, 88¹³.
 Platysma, 13¹¹, 14²⁰, 16¹³⁻⁶⁰, 17⁹⁻⁵⁷, 18⁶⁻⁵⁷, 19⁸, 20⁶⁵.
 Pleura diaphragmatica, 27¹⁵⁻⁵⁹, 29¹³.
 — mediastinalis, 25⁸, 27¹³.
 — parietalis, 22¹⁰, 23⁸⁻⁹¹.
 — pulmonalis, 23¹³⁻⁹², 28²⁷.
 Plexus chorioideus ventriculi lateralis, 5⁷, 6³³⁻⁸².
 — chorioideus ventriculi quarti, 10⁴².
 — chorioideus ventriculi tertii, 6⁴.
 — nervosus aorticus abdominalis, 32²⁷⁻³⁷⁻⁵⁰, 33¹⁶, 34²³, 35³³, 36³⁴.
 — nervosus brachialis, 21⁷⁰.
 — nervosus mesentericus inferior, 35²⁷.
 — nervosus mesentericus superior, 32⁶³⁻⁶⁷, 33⁶².
 — nervosus œsophageus anterior, 25⁴³, 26³³⁻⁵¹, 27³⁰⁻⁵⁴, 28⁶³.
 — œsophageus posterior, 26⁴⁹.
 — venosus pampiniformis, 41⁶⁸, 42⁷⁵, 43⁶⁶, 44²⁻³⁴.
 — venosus pudendalis, 41⁵⁵, 42⁸, 43⁰⁻³³.
 — venosus sacralis anterior, 39³⁵.
 — venosus uterovaginalis, 45⁵¹, 46¹⁸⁻³⁹, 47¹⁷⁻³⁸⁻⁴².
 — venosus vertebralis internus, 30⁴³.
 — venosus vertebralis posterior, 12²⁵⁻⁴⁰, 13⁴¹, 14⁴⁷.
 — vesicalis, 40⁵¹.
 Plica (ae) alaris (*alar lig.*), 90².
 — arypegilotica (*aryepiglottic fold*), 17⁵.
 — circulares [Kerkringi] (*valvulae conniventes*), 34⁹⁻⁶⁶, 35⁶⁴, 36³.
 Plica (ae) longitudinalis duodeni, 33¹¹.
 — transversalis recti (*valve of Houston*), 41¹¹.
 — umbilicalis lateralis (*deep epigastric fold*), 38², 39¹⁻⁷¹, 40⁸.
 Polus temporalis, 9⁷⁶.
 Portio minor n. trigemini (*motor root*), 9²³.
 Præcuneus (*quadrate lobule of cerebrum*), 2¹⁴, 3²⁴, 4²⁸, 5²⁷, 6¹⁴.
 Præputium clitoridis, 49¹.
 Processus articularis superior ossis sacri, 37²⁹.
 — caudatus hepatis (*caudate lobe*), 30², 31¹⁹, 32¹⁴.
 — clinoides anterior, 8²².
 — clinoides posterior, 8²⁴.
 — condyloideus mandibulae, 10⁶².
 — coracoideus, 21¹⁷⁻⁶⁴.
 — coronoideus mandibulae, 11¹⁶⁻⁸⁴.
 — frontalis maxilla (*nasal process*), 8², 9³⁻⁹⁴.
 — frontosphenoidalis ossis zygomatici (*frontal process of malar*), 8⁷⁴, 9¹⁸⁻⁷⁸.
 — lateralis tuberis calcanei (*lateral process of calcaneus*), 108¹⁴.
 — papillaris hepatis (*tuber papillare*), 30⁸⁸.
 — pterygoideus ossis sphenoidalis, 10⁸.
 — spinosus epistrophei [vertebrae cervicalis II], 14⁴⁰, 15³⁰.
 — spinosus vertebrae cervicalis IV, 18³².
 — spinosus vertebrae cervicalis V, 19²⁴.
 — spinosus vertebrae thoracalis II, 21⁴².
 — spinosus vertebrae thoracalis IV, 23⁵⁵.
 — spinosus vertebrae thoracalis V, 24³⁹.
 — spinosus vertebrae thoracalis VI, 25⁴¹.
 — spinosus vertebrae thoracalis VII, 26⁴⁰.
 — spinosus vertebrae thoracalis VIII, 27⁴¹.
 — spinosus vertebrae thoracalis IX, 28³⁹.
 — spinosus vertebrae thoracalis XII, 30⁴⁶.
 — spinosus vertebrae lumbalis I, 32⁵⁶.
 — spinosus vertebrae lumbalis II, 33³⁶.
 — spinosus vertebrae lumbalis IV, 36³⁸.
 — spinosus vertebrae lumbalis V, 37³⁴.
 — styloideus ossis temporalis, 13¹⁵⁻³².
 — styloideus radii, 70²³.
 — trochlearis calcanei (*peroneal spine*), 108¹⁷.
 — vermiformis (*vermiform appendix*), 38¹², 39⁹.
 — xiphoideus (*ensiform process*), 28⁷⁸, 29¹.
 — zygomaticus maxilla (*malar process of maxilla*), 10⁷⁰.
 — zygomaticus ossis frontalis (*external angular process of frontal*), 7¹⁷.
 — zygomaticus ossis temporalis (*zygoma*), 10⁶⁴.
 Protuberantia occipitalis interna, 9⁴⁴.
 Pulmo [lobus inferior]. See LOBUS.
 Pulmo [lobus medius]. See LOBUS.
 — [lobus superior]. See LOBUS.
 Pulvinar, 6³⁹, 7⁶⁰.
 Putamen, 5¹⁰, 6²⁰⁻⁶⁹, 7²²⁻⁸⁴.
 Pyramis medullae oblongatae, 11⁵⁶.
 Radiatio corporis callosi, 5³⁷.
 — corporis callosi [pars frontalis]. See PARS.
 — corporis callosi [pars occipitalis]. See PARS.
 — corporis callosi [pars parietalis]. See PARS.
 — occipitothalamica [Gratioleti] (*optic radiation*), 6²⁹⁻⁵⁶.
 Radius, 61²¹, 62²², 63²⁹, 64¹⁸, 65¹⁶, 66¹⁸, 67¹⁷, 68¹⁴, 69²⁹.
 Radix linguae, 16⁵⁸.
 Ramus bronchialis bronchi, 24⁶³, 25¹⁶⁻⁶².
 — inferior ossis ischii (*ramus of ischium*), 43³¹, 48³⁰.
 — inferior ossis pubis (*descending ramus*), 42⁹, 43⁴⁹, 48⁸.
 — mandibulae, 12¹³, 13³⁴.
 — superior ossis pubis (*ascending ramus*), 41⁶.
 Ramus, Rami arteriosi.
 — ascendens a. transversae colli (*superficial cervical artery*), 20²³.
 — circumflexus a. coronariae cordis sinistrae, 25⁷⁰, 26⁵⁷.
 — descendens a. circumflexae femoris lateralis (*descending branch of external circumflex artery*), 42¹⁵, 44¹⁹.
 — descendens anterior a. coronariae cordis sinistrae (*anterior descending branch of left coronary artery*), 25⁶⁸⁻⁷³, 26⁷¹, 27⁷⁶.
 — descendens a. occipitalis (*princeps cervicis artery*), 12⁴¹, 13⁴¹.
 — descendens a. transversae colli (*posterior scapular artery*), 21³².
 — dexter a. pulmonalis (*right pulmonary artery*), 24¹⁵.
 — œsophagei a. gastricae sinistrae (*œsophageal branch of gastric artery*), 27⁵⁷, 28⁴⁹.
 — posterior a. obturatoriae (*external branch of obturator artery*), 49³¹.
 — sinister a. pulmonalis (*left pulmonary artery*), 24⁵².
 — suprarenales superiores a. phrenicae inferioris (*superior suprarenal artery*), 28⁵⁰.
 — volaris profundus a. ulnaris (*deep ulnar artery*), 72¹⁴.
 Ramus, Rami nervosi.
 — anterior n. obturatorii (*superficial branch of*), 43¹³, 48⁴¹, 49³³, 76⁹, 77⁹.
 — bronchialis anterior n. vagi, 25⁵⁴.
 — colli n. facialis (*cervical branch of facial nerve*), 17¹⁰⁻³⁴.

- Ramus cutanei anteriores n. femoralis (*cutaneous branch of anterior cranial nerve*), 44²⁸, 76², 77³, 78³, 79⁴, 80⁵, 81⁵, 83⁵.
- descendens n. hypoglossi, 161⁸⁻¹², 171¹⁵⁻¹⁷, 181¹¹⁻¹².
- dorsalis manus n. ulnaris (*dorsal cutaneous branch of ulnar nerve*), 68⁶, 69⁹, 70⁹, 71¹⁰.
- externus n. accessorii (*spinal portion of spinal accessory*), 191⁸⁻²⁴.
- externus n. laryngei superioris (*external laryngeal nerve*), 171¹⁴⁻²².
- inferior n. oculomotorii, 91²⁻⁸³.
- internus n. laryngei superioris (*internal laryngeal nerve*), 171¹³⁻²³, 185⁵⁻⁶⁴.
- musculares n. femoralis (*muscular branch of anterior cranial*), 42⁶⁸, 44²⁰⁻²¹⁻²³, 76²⁸.
- pharyngeus n. vagi, 131⁷, 142⁵⁻⁵⁷.
- posterior n. obturatorii (*deep branch of*), 42²⁰⁻⁶⁴, 43²², 44², 48¹¹, 49¹², 76⁸, 77⁹.
- profundus n. plantaris lateralis (*deep branch of external plantar*), 111¹⁶.
- profundus n. radialis (*posterior interosseous nerve*), 60²³, 61²⁰, 62¹⁹.
- profundus n. ulnaris (*deep palmar branch of ulnar nerve*), 72⁹.
- superficialis n. radialis (*radial nerve*), 60²³, 61²⁷, 62²⁵, 63²⁴, 64²², 65²⁰, 66²¹, 67²⁰, 68²⁰, 69¹⁵⁻¹⁹, 70²², 71²³.
- superficialis n. ulnaris (*superficial palmar branch of ulnar nerve*), 73⁹.
- ulnaris n. cutanei antibrachii medialis (*posterior branch of internal cutaneous*), 55⁶, 56⁵.
- volaris manus n. ulnaris (*superficial branch of ulnar nerve*), 69³, 70⁴, 71², 72⁴.
- volaris n. cutanei antibrachii medialis (*anterior branch of internal cutaneous*), 55⁴, 56², 57², 58³, 59⁴, 60⁴, 61³, 62³, 63³, 64³.
- Raphe pterygomandibularis (*pterygomandibular lig.*), 131⁵⁻⁵⁶.
- Recessus epitympanicus, 9¹.
- infundibuli (*cavity of infundibulum*), 8⁸¹.
- pharyngeus [Rosenmuelleri] (*fossa of Rosenmueller*), 11¹⁵.
- Ren dexter (*right kidney*), 30²², 31²³, 33²⁴.
- sinister (*left kidney*), 29²⁴, 30²³.
- Rete venosum vertebrae, 13¹⁰, 14⁴, 16²⁸, 17²⁸, 21⁴⁵.
- Retina, 81¹.
- Retinaculum patellae laterale (*external patellar lig.*), 90²⁸.
- patellae mediale (*internal patellar lig.*), 90⁴, 91².
- Rima glottidis, 19⁶⁰.
- Saccus lacrimalis, 8⁷.
- Scapula, 21²⁶⁻³⁷, 22²⁵, 23⁴⁰, 24³⁰.
- Scapula [angulus inferior]. See ANGULUS.
- [angulus medialis]. See ANGULUS.
- [margo axillaris]. See MARGO.
- [margo vertebralis]. See MARGO.
- Scrotum, 44²³.
- Septum atriorum cordis (*septum of auricles*), 26⁹.
- corporum cavernosorum, 48¹.
- intermusculare femoris laterale (*external intermuscular septum*), 77²⁰, 78¹⁴, 79¹⁶, 80¹², 81¹⁸, 82¹², 84¹⁵, 86¹⁵.
- intermusculare femoris mediale (*internal intermuscular septum*), 80¹⁷, 81⁹, 82².
- intermusculare humeri laterale (*external intermuscular septum*), 51¹⁶, 52¹⁶, 53¹⁶, 54¹¹, 55¹², 56¹¹, 57¹⁰.
- intermusculare humeri mediale (*internal intermuscular septum*), 51⁴, 52⁹, 53⁹, 54⁸, 56⁷, 57⁶.
- linguae, 14².
- membranaceum ventriculorum cordis, 26⁶⁰.
- musculare ventriculorum cordis, 26⁷⁰.
- nasi, 10⁷⁰.
- Sinus aortae [Valsalva] (*sinus of Valsalva*), 25⁹⁰.
- coronarius, 26⁵⁵.
- frontalis, 6², 7⁴, 8⁸⁸.
- maxillaris [Highmore] (*antrum of Highmore*), 91⁹, 10⁶⁻⁷⁴⁻⁷⁶, 11⁶⁻⁹², 12⁶⁶.
- petrosus inferior, 92⁴⁻⁷⁵, 10²³.
- phrenicocostalis, 28⁵⁰⁻⁷¹, 29⁸⁻⁴⁸⁻⁷³, 30¹⁶, 31²⁰⁻⁵¹.
- rectus (*straight sinus*), 7⁵², 9⁴⁵.
- renalis, 31⁴⁹, 32²⁴.
- sagittalis inferior (*inferior longitudinal sinus*), 6⁴².
- sagittalis superior (*superior longitudinal sinus*), 1¹³, 21³⁻²⁴, 31¹⁻²³, 42⁶⁻⁵⁰, 52⁶⁻⁵⁴, 64³, 75², 84⁵.
- transversus (*lateral sinus*), 92⁶⁻⁴⁰⁻⁴⁵⁻⁵⁴, 102⁷⁻⁵⁴, 113⁸⁻⁶⁴.
- transversus pericardii, 24⁵.
- vertebralis longitudinalis, 15²⁴.
- Spina angularis ossis sphenoidalis (*sphenoidal spine*), 101¹⁷.
- iliaca anterior inferior, 39⁶⁰, 45⁴².
- iliaca anterior superior, 38¹³.
- ischiadica (*spine of the ischium*), 41²⁻⁴⁸, 46²⁰⁻³⁸.
- scapulae, 201⁷⁻²², 21²⁹⁻⁵⁵.
- Splenium corporis callosi, 52³, 63⁶⁻⁴⁹.
- Stratum circulare tunicae muscularis intestini recti, 42³⁸.
- longitudinale tunicae muscularis intestini recti, 42³⁷.
- Striae medullares thalami, 6¹⁰.
- transverse corporis callosi, 53³.
- Substantia nigra pedunculi cerebri, 73², 85⁸.
- Sulcus centralis [Rolandi] (*fissure of Rolando*), 1⁸, 21⁸, 31¹⁰⁻³², 43⁹, 54¹.
- Sulcus corporis callosi (*callosal sulcus*), 52⁴, 64⁷⁻⁸⁵.
- coronarius cordis (*auriculo-ventricular groove*), 26⁵⁹, 27⁵.
- frontalis superior, 32⁷, 44⁶, 53¹.
- interparietalis, 316²⁷, 43²⁰, 53¹.
- obturatorius ossis pubis (*obturator groove*), 41⁸.
- praecentralis (*interparietal sulcus of Turner*), 22⁹, 44¹.
- temporalis medius, 8⁶⁴.
- Sustentaculum tali, 108⁵.
- Sutura coronalis, 15¹⁹, 21⁴, 33³⁻⁴, 48⁴, 59⁴⁻⁵, 61²⁻⁷⁶.
- lambdoidea, 52⁵, 63⁸, 74⁵⁻⁶¹, 83⁸.
- occipitomastoidea, 113²⁰.
- sagittalis, 1², 21³, 32², 42⁵.
- sphenosquamosa (*squamoso-sphenoidal*), 72³.
- squamosa (*squamo-parietal*), 62⁵, 73⁴, 83⁴.
- Talus (*astragalus*), 107³, 108⁴.
- Tarsus inferior oculi (*inferior tarsal plate*), 9⁸⁵.
- superior oculi (*superior tarsal plate*), 71³.
- Tegmentum (*tegmental part of pons*), 85⁴.
- Tela subcutanea (*subcutaneous tissue*), 14¹⁻¹², 31⁵.
- Tendo calcaneus [Achillis] (*tendon of Achilles*), 102⁹, 103⁹, 104⁹, 105¹⁰, 106², 107¹².
- Tentorium cerebelli, 84⁵.
- Testis, 44³⁵.
- Thymus, 229⁹, 231⁴, 24³.
- Tibia, 911⁹, 921⁹, 93², 94¹, 95², 96¹, 97¹, 98¹, 99¹, 100¹, 102², 103², 104², 105³, 106³.
- Tonsilla cerebelli (*amygdala*), 104¹, 116¹.
- palatina (*tonsil*), 13⁶⁰, 141²⁻⁶⁶, 151¹.
- Torus tubarius (*Eustachian cushion*), 112³.
- Trabeculae carnae (*columnae carnae*), 273⁷⁻⁷⁵.
- Trachea, 206⁸, 211², 221², 231².
- Tractus iliobtibialis [Maisiati] (*iliotibial band*), 871⁷, 881², 912⁷.
- olfactorius, 83³.
- opticus, 75²⁻²⁴⁻³⁰, 881¹.
- Trigonum vesicae [Lieutaudi], 46⁴.
- Trochanter major, 415³, 422⁵.
- minor, 432⁵⁻⁵¹, 491³.
- Truncus corporis callosi (*body*), 52⁹.
- lumbosacralis (*lumbosacral cord*), 382⁴⁻⁴⁸, 392².
- sympathicus (*sympathetic nerve trunk*), 112⁸, 121⁷⁻⁴⁹, 151⁷, 161⁷, 171⁸⁻³⁰, 181¹⁰⁻⁵⁰, 191¹²⁻⁵⁹, 20⁶, 224⁸⁻⁵⁴, 232²⁻⁶⁰, 243⁵⁻⁴³, 253⁷, 263⁵⁻⁴⁴, 273⁷⁻⁴⁵, 283³⁻⁴⁶, 293⁶⁻⁴⁶, 303⁸⁻⁵⁴, 322⁸, 332⁸⁻⁴⁶, 342⁸⁻⁴⁵, 352⁹⁻⁴³, 364⁸, 372²⁻⁴⁴.
- Tuba auditiva [Eustachii] (*Eustachian tube*), 101³, 111³.

- Tuba uterina [Fallopil] (*Fallopian tube*), 45⁹⁻⁴⁹⁻⁶².
- Tuber calcanei, 108¹³.
- cinereum, 7¹⁹.
- ischiadicum (*tuberosity of the ischium*), 42²³, 47³⁸, 48²⁰.
- vermis (*tuber valvulus*), 10⁴⁰.
- Tuberculum majus humeri (*greater tuberosity*), 21⁶¹.
- minus humeri (*lesser tuberosity*), 21⁶².
- pubicum (*spine of pubis*), 41⁴, 47⁵⁻⁵⁴.
- Tuberositas glutea femoris (*gluteal ridge*), 76¹⁰.
- ossis metatarsalis quinti (*tubercle of fifth metatarsal*), 110²².
- ossis navicularis pedis, 109⁶.
- tibiae (*tubercle of tibia*), 93¹.
- ulnae (*tubercle of ulna*), 60¹⁵.
- Tunica albuginea testis, 42⁷⁸, 43³.
- muscularis [stratum circulare intestini recti]. See STRATUM.
- muscularis [stratum longitudinale intestini recti]. See STRATUM.
- muscularis intestini recti, 46³².
- muscularis vesicae urinariae, 41⁷⁰, 46⁵⁵, 47⁵⁹.
- vaginalis communis, 43⁷.
- vaginalis propria testis, 44³⁶.
- Ulna, 61¹³, 62¹², 63¹¹, 64⁹, 65⁹, 66⁸, 67⁸, 68⁹, 69⁸.
- Uncus gyri hippocampi, 8⁶⁶.
- Ureter, 31⁴⁸, 32⁴⁸, 33²²⁻⁴⁸, 34²³⁻⁴⁸, 35²³⁻⁴⁷, 36²¹⁻⁵³, 37¹⁷⁻⁵³, 38¹⁹⁻⁵³, 39²⁰⁻⁵², 40²¹⁻⁴⁹, 45²¹⁻⁵¹, 46⁴¹.
- Urethra muliebris, 48⁴⁹.
- virilis [pars prostatica]. See PARS.
- virilis [pars cavernosa]. See PARS.
- Uvula palatina, 13⁶⁵.
- vermis (*uvular lobe*), 10⁴⁰.
- Vagina, 46²⁷, 47²⁷, 48⁴³.
- [paries anterior]. See PARS.
- [paries posterior]. See PARS.
- m. recti abdominis (*sheath of rectus muscle*), 37⁶, 40⁴, 45⁶⁸, 46⁵⁶.
- n. optici, 8¹⁵.
- Vallecula, 16⁵⁰.
- Valvula bicuspidalis [mitralis] (*mitral valve*).
- bicuspidalis [mitralis] [cuspis posterior]. See CUSPIS.
- coli (*ileo-caecal*), 38¹¹.
- tricuspidalis (*tricuspid valve*), 26⁷⁶.
- venae cavae inferioris [Eustachii] (*Eustachian valve*), 26¹².
- Valvulae semilunares aortae (*aortic valve*), 25⁸⁰.
- semilunares a. pulmonalis (*pulmonary valve*), 24⁷³.
- Velum medullare anterius (*valve of Vieussens*), 9⁴⁷.
- Vena angularis, 84⁸⁹, 10⁷, 11⁸⁻⁹², 12⁶³.
- anonyma dextra, 22⁵.
- anonyma sinistra, 22⁹⁴.
- arciformis, 30⁵⁸.
- auricularis posterior, 12⁴⁶, 13⁴⁷.
- axillaris, 22¹⁵⁻⁸⁴, 23²³⁻⁸³.
- azygos, 24³⁶, 25⁴⁰, 26³⁹, 27⁴⁰, 28³⁴, 29³⁸.
- basilica, 50⁸, 51⁷, 52⁵, 53⁵, 54⁵, 55⁵, 56⁴, 57⁴, 58⁵, 59⁷, 60⁸, 61¹⁰, 62¹⁰, 63⁹, 64⁸, 65⁷, 66⁷, 67⁷, 68⁷, 69⁵, 70⁸.
- brachialis, 50⁹, 51⁸, 52⁷, 53²⁻⁶, 54², 55², 56¹, 57¹, 58¹, 59².
- cava inferior, 27²⁰, 28¹⁹, 29¹⁷, 30²⁰, 31²³, 32¹⁶, 33¹⁹, 34²², 35²⁵, 36²³.
- cava superior, 23⁴, 24⁹, 25¹¹.
- cephalica, 22¹⁹, 23⁸⁰, 50²⁰, 51¹⁹, 52²⁰, 53²⁰, 54¹⁹, 55¹⁹, 56¹⁵, 57¹⁶, 58²¹, 59²⁸, 60²⁷, 61²⁸, 62²⁴, 63²³, 64²¹, 65¹⁹, 66²⁰.
- cerebri interna (*vein of Galen*), 7⁴⁰.
- cerebri magna [Galen] (*vein of Galen*), 6⁴⁰.
- cerebri media (*superficial Sylvian*), 6¹⁵, 7²⁰⁻²².
- cerebri superior, 1², 3²¹.
- cervicalis profunda, 14³⁸, 15²⁷, 16²⁷⁻³³, 17²⁹, 18²²⁻³⁸, 19²⁴⁻⁴⁴, 20²⁹.
- circumflexa femoris lateralis (*external circumflex*), 43⁵⁷, 48¹⁹, 49⁹.
- circumflexa femoris medialis (*internal circumflex*), 48¹⁴⁻²³.
- circumflexa femoris medialis [ramus], 49¹⁴⁻²⁸.
- circumflexa ilium profunda (*deep circumflex iliac*), 37¹⁴, 38⁵⁹, 45⁶¹.
- colica dextra, 34¹¹⁻⁷¹, 35¹⁵, 36¹⁶, 37¹⁵, 38¹⁴.
- colica media, 31⁶⁴.
- colica sinistra, 31⁵³, 32⁵², 33⁴⁹.
- cordis anterior (*anterior cardiac*), 26⁴, 27⁸³.
- cordis magna (*great cardiac vein*), 25⁶⁷⁻⁷², 26⁷¹.
- cordis media, 27⁷⁷.
- coronaria ventriculi (*coronary vein of stomach*), 29⁹⁶, 30⁷⁸⁻⁸⁴.
- diploica, 6⁷⁸, 10⁸⁰.
- diploica frontalis, 4³, 5⁴, 6⁵.
- dorsalis penis, 42¹⁻⁵, 43⁷³.
- epigastrica inferior (*deep epigastric*), 38⁶⁸, 39⁷⁰, 45⁸.
- epigastrica superior, 30⁵.
- facialis anterior, 13⁹⁻⁵⁹, 14¹¹⁻⁶⁹, 15⁹⁻⁵⁴, 16¹¹⁻⁴⁹, 17¹⁰⁻⁵⁴.
- facialis communis, 17¹⁵, 18⁵², 19⁵⁷.
- facialis posterior, 11²³⁻⁷⁴, 17¹²⁻⁵².
- femoralis, 41⁹⁻⁶³, 42⁶⁹, 43⁶⁰, 44²⁶, 46⁸⁻³¹, 48⁹, 49³⁴, 76¹, 77², 78², 79³, 80³, 81⁴, 83⁵, 84², 85⁴.
- frontalis [rami], 3⁴⁰.
- gastrica brevis (*vasa brevia*), 28⁸².
- glutea inferior (*sciatic vein*), 40²⁸⁻⁴⁴, 41²³⁻²⁹⁻⁴⁷, 42²⁰⁻⁵⁰⁻⁵², 43⁴⁸, 45²⁷⁻⁴⁸, 46¹⁹, 47¹⁹⁻³⁹, 48³⁰.
- Vena glutea superior, 39²⁶⁻⁴⁷⁻⁴⁹.
- haemorrhoidalis inferior, 48²¹⁻²⁹.
- haemorrhoidalis media, 45²⁸⁻⁴⁵, 46²³⁻⁵⁷.
- haemorrhoidalis superior, 36⁶⁴, 37⁴⁰, 38⁵⁹, 39⁵⁸, 45³⁴⁻⁴¹, 46²⁵⁻³⁴.
- hemiazygos, 28⁴⁴, 29⁴⁵.
- hemiazygos accessoria, 23⁵⁹, 24⁴⁴, 26⁴³, 27⁴⁴.
- hepatica, 27¹², 28⁹, 29¹⁰⁻²³, 30²².
- hypogastrica (*internal iliac vein*), 38²⁶⁻⁴⁷, 39²⁶⁻⁴⁷.
- hypogastrica [ramus], 39²³.
- ileocolica, 35¹⁹, 36⁹, 37⁹, 38¹⁹.
- iliaca communis, 37²¹⁻⁴².
- iliaca externa, 38²¹⁻⁵¹, 39¹³⁻⁵⁹, 40¹¹⁻⁶³, 45¹¹.
- iliolumbalis, 38⁴⁹.
- iliolumbalis [rami], 37⁵².
- intercostalis, 22⁴¹⁻⁵⁴, 23⁶⁶, 25⁵², 26¹⁸⁻³¹⁻⁴⁸, 27²²⁻²⁷⁻⁵⁰.
- interlobaris renis, 30⁶¹.
- intervertebralis, 20⁵³.
- intestinalis, 34²⁰⁻⁵⁷, 35⁵²⁻⁵⁴, 36⁶².
- jugularis anterior, 18¹, 19³, 20²⁻⁶², 21².
- jugularis externa, 11⁷⁰, 13¹⁹⁻⁴⁹, 14²⁴, 15¹⁵, 16¹⁷, 17¹⁹, 18¹⁴, 19²¹, 20⁴⁶, 21¹⁹.
- jugularis interna, 11³³, 12⁴⁶, 13²¹, 14²⁷⁻⁵⁴, 15¹⁹⁻⁴⁴, 16²¹⁻⁴⁰, 17²⁰⁻⁴⁵, 18⁴⁷, 19¹⁴⁻⁵³, 20⁹⁻⁵⁸, 21⁷⁻⁷⁴.
- lienalis (*splenic*), 29⁵⁸, 30⁷¹, 31⁶⁹.
- lingualis, 15⁹, 16⁷⁻³³.
- lumbalis ascendens, 33⁴⁶, 34⁴³, 35³¹⁻³⁹.
- mammaria interna, 23⁴, 24⁴, 25³, 26³⁻⁷⁴, 27⁴, 28³⁻⁷⁷.
- meningeae media, 5¹¹, 6¹⁷⁻⁷⁰.
- meningeae media [rami], 27².
- mesenterica inferior, 32⁵⁵, 33⁵¹, 34⁵¹, 35⁴⁴.
- mesenterica superior, 32⁶⁸, 33⁷⁰, 34⁵⁹.
- mesenterica superior [rami], 32⁶⁹.
- metatarsae plantaris, 112¹³.
- obliqua atrii sinistri [Marshall] (*oblique vein of Marshall*), 25⁶⁶.
- obturatoria, 39¹⁹⁻²⁵⁻⁴⁸, 40¹⁸⁻⁵⁶, 41¹⁶⁻⁶⁰, 45¹⁵⁻⁵⁴, 46¹¹, 47⁵⁹, 48¹².
- occipitalis, 5²²⁻²⁹, 10³⁵, 11⁴⁰.
- occipitalis [ramus], 2¹⁰⁻¹², 3¹⁸⁻²⁵, 4²³, 11⁴³⁻⁵⁵.
- ophthalmica superior, 7⁸, 8¹⁷⁻⁷⁸, 9⁸².
- ovarica, 45⁵⁵.
- palatina, 17⁵⁹.
- perforans, 42²²⁻⁶², 43⁵⁰, 44⁸, 76¹⁸, 77¹⁹, 81¹⁰, 82⁹.
- peroneae, 94¹², 95¹², 96¹³, 97¹², 98¹⁰, 99¹², 100¹², 101¹², 102¹³, 104¹³.
- pharyngea, 11¹⁸, 12¹³⁻³⁸, 13¹³, 14⁶², 15¹⁴.
- phrenica inferior, 28²³⁻³³.
- poplitea, 87¹⁰, 88², 89¹⁰, 90¹⁰, 91¹⁸, 92⁹, 93¹³.
- portae, 30⁶⁻⁹⁻¹⁷, 31⁷².
- portae [ramus], 31¹⁸, 33¹⁷.
- posterior ventriculi sinistra, 27⁷⁸.

- Vena profunda femoris, 44¹⁵, 49³³, 76³⁹, 77²³, 78²², 79⁹, 80¹³, 81¹, 82¹⁴, 83¹⁶.
- profunda penis, 43¹⁸.
- pudenda interna, 40⁶, 41¹⁶.
- pulmonalis dextra, 24¹⁷, 25¹⁹.
- pulmonalis dextra [ramus], 25²⁰⁻²⁹⁻²⁶⁻⁶².
- pulmonalis sinistra, 24¹⁹⁻⁶², 25⁵²⁻⁶¹.
- radialis, 60³⁹, 61³⁹.
- renalis, 31²⁶⁻⁴⁷, 32²²⁻⁴⁷.
- renalis [rami], 29⁵⁵⁻⁵⁷, 32⁴⁹.
- sacralis lateralis [rami], 38⁵¹.
- sacralis media, 38⁵².
- saphena magna (*internal saphenous*), 41⁶⁴, 42¹¹⁻⁷¹, 43¹¹, 44³⁹, 48⁷⁻⁴², 49⁵⁻³⁹, 76⁵, 77⁵, 78⁵, 79⁵, 81⁵, 85⁵, 86⁵, 87⁵, 88⁷, 89⁹, 90⁹, 91⁹, 92⁹, 93⁹, 94⁹, 95⁹, 96⁹, 97⁹, 98⁹, 99⁹, 100⁹, 101⁹, 102⁹, 103⁹, 104⁹, 105⁹, 106⁹, 107⁹.
- saphena parva (*external saphenous*), 86¹¹, 87¹², 88¹¹, 89¹¹, 90¹², 91¹², 92¹⁰, 93¹⁰, 94⁹, 95⁹, 96¹⁰, 97⁹, 98⁷, 99⁹, 101¹¹, 102¹¹, 103¹¹, 104¹¹, 105¹¹, 106¹².
- sigmoidea, 36⁶³, 37⁵⁹⁻⁶⁸.
- sigmoidea [rami], 38⁵⁷, 40⁵³.
- spermatica, 32²⁰⁻⁵¹, 33²¹⁻⁴⁷, 34²⁴⁻⁴⁹, 35²²⁻⁴⁸, 36²⁶, 37¹⁶, 38¹⁵⁻⁶⁹.
- subclavia, 22⁵⁸.
- submental, 17⁶⁶.
- suprarenalis, 30⁶⁵, 31⁴⁶.
- temporalis media, 8⁶⁵, 9⁶⁷.
- temporalis superficialis, 5¹², 6²¹, 7²⁹, 8³⁹, 9²⁸, 10¹⁹⁻⁶¹.
- temporalis superficialis [rami], 3¹¹, 4¹³.
- Vena thoracalis lateralis, 22⁵⁶, 23¹⁶⁻⁵⁷, 27²²⁻⁶².
- thoracalis lateralis [ramus], 24¹⁶.
- thyreoidea superior, 17¹¹.
- tibialis anterior, 94¹⁵, 95¹⁵, 96¹⁷, 97¹⁷, 98¹⁶, 99⁵, 100¹⁵, 101¹, 102⁵, 103¹⁹, 104¹⁹, 105¹⁸.
- tibialis posterior, 94⁵, 95⁵, 96⁴, 97⁵, 98⁴, 99⁵, 100⁵, 101⁵, 102⁵, 103⁵, 104⁵, 105⁵, 106⁷, 107⁹.
- transversa colli (*transversalis colli*), 20²³⁻⁴⁷.
- transversa colli [ramus], 21³².
- transversa scapulae (*suprascapular vein*), 21²³.
- ulnaris, 60⁷, 61⁷.
- uterina, 45¹⁹⁻²⁹⁻⁵³.
- vertebralis, 12³⁸, 13²⁵⁻⁴⁷, 14²²⁻⁵⁹, 16²³, 17²³⁻⁴³, 18⁴⁷, 19¹³, 20¹⁰⁻³⁹, 21⁵.
- Venter posterior m. digastrici, 12²²⁻⁴⁵, 13²³, 14²⁵.
- superior m. omohyoidei, 19⁵⁻⁶⁹.
- Ventriculus [Gaster], 28⁶⁴, 29⁶⁹, 30⁶⁹, 31⁶⁵, 32⁶⁶.
- [pars cardinea]. See PARS.
- [pars pylorica]. See PARS.
- dexter cordis (*right ventricle*), 25⁷⁴⁻⁷⁶, 26⁷², 27².
- lateralis cerebri [pars centralis]. See PARS.
- lateralis cerebri [cornu anterius]. See CORNU.
- lateralis cerebri [cornu inferius]. See CORNU.
- lateralis cerebri [cornu posterius]. See CORNU.
- Ventriculus quartus cerebri (*fourth ventricle*), 9⁶¹.
- sinister cordis (*left ventricle*), 26⁶³, 27⁷⁴.
- tertius cerebri, 7¹⁶.
- Vertebra cervicalis I, 13²⁵.
- cervicalis II, 14¹³, 15²⁵.
- cervicalis III, 16³².
- cervicalis IV, 17³⁹, 18³⁹.
- cervicalis V, 19⁷.
- cervicalis VII, 20¹.
- lumbalis I, 31³⁷.
- lumbalis II, 32³⁶.
- lumbalis III, 33³⁶.
- lumbalis IV, 35³⁶.
- lumbalis V, 37³⁷.
- sacralis I-V, 38¹¹, 39²³, 40²⁵.
- thoracalis III, 22⁵¹.
- thoracalis IV, 23⁵⁴.
- thoracalis V, 24⁵⁹.
- thoracalis VII, 25⁴¹.
- thoracalis VIII, 26⁴¹.
- thoracalis XII, 30⁴⁸.
- Vertex vesicae urinariae, 40², 45³.
- Vesica fellea (*gall bladder*), 32¹¹, 33¹⁰.
- urinaria (*urinary bladder*), 41⁶⁹, 46⁵⁷, 47⁵.
- urinaria [tunica muscularis]. See TUNICA.
- Vesiculae seminales, 41²⁹.
- Vestibulum bursae omentalis, 30⁵⁵.
- Vestibulum laryngis, 18⁷.
- oris, 12⁸, 14⁷⁰.
- vaginae, 49²⁸.
- Vomer, 10⁵, 11⁹⁸.

SUPPLEMENTAL INDEX

This supplemental index gives the mixed terms as found in the indices of the older anatomies. The larger numerals cite the number of the section, while the smaller cite the particular leader where a given structure may be found. The letter "K" indicates a reference to a Key-figure.

- Acetabulum, 40⁵⁵, 46¹⁴⁻⁴³⁻⁴⁵.
 Acromion process, K4.
 Adrenal capsule, K7, 29²⁷⁻⁵¹, 30²⁶.
 Ala of sacrum, 37²⁴, 39³⁰, 40³⁰.
 — of sphenoid, greater, 6¹⁴, 7²¹, 8²³⁻⁷², 10⁷¹.
 Alar ligament of knee, 90².
 Ampulla of rectum, KS, 41³⁶, 47²⁹, 48²⁴.
 Amygdala, 10⁴¹, 11⁶¹.
 Angle of scapula, inferior, 25⁵⁰.
 — of scapula, superior, K4.
 Anal cleft, KS, 42⁴¹, 46²⁸, 47²⁸, 48²⁵.
 Antrum, maxillary of Highmore, 9¹⁰, 10⁶⁻⁷⁴⁻⁷⁶, 11⁶⁻⁹², 12⁶⁶.
 — mastoid, 9³⁴.
 Anus, 43³⁸, 49²¹.
 Aorta, abdominal, 31³⁸, 32³⁹, 33³³, 34³⁸.
 — arch of, K6.
 — ascending, 23¹⁰², 24².
 — descending, 23⁹⁹.
 — thoracic, K6, 24⁴⁷, 25⁴⁸, 26⁴⁶, 27⁴⁶, 28⁴⁰, 29⁴³, 30⁵¹.
 Apex of heart, K6.
 Aponeurosis, epicranial, 1¹⁻¹⁶, 2¹¹, 3²⁰, 4²⁰, 5³⁴, 6³¹, 8⁴².
 Appendices epiploicæ, 34⁵⁻¹⁰⁻⁶⁷⁻⁶⁸, 36¹⁴, 37⁵⁷.
 Appendix, vermiform, 38¹², 39⁹.
 Aqueduct of Sylvius, K3, 7⁴⁶, 8⁴⁴.
 Arachnoid, cranial, 1⁷, 2⁹, 6⁶⁰.
 Arch of aorta, 23⁹⁹.
 — palmar, deep, K9, 72¹⁹.
 — palmar, superficial, K9.
 — plantar, arterial, 111²⁷.
 — posterior of atlas, 13³⁷.
 Artery, anastomotica magna, of brachial, 59¹.
 — anastomotica magna, of femoral, 86³, 88⁴, 89⁵.
 — angular, 8⁵⁹, 11⁹¹.
 — articular, inferior internal, 92⁸.
 — auricular, posterior, 12⁴⁷.
 — axillary, K6, 22¹⁹⁻⁵¹, 23²³⁻⁵³.
 — basilar, 8²⁹, 9²⁴, 10²⁹.
 — brachial, K6, K9, 50⁹, 51⁸, 52⁷, 53⁹, 54², 55², 56¹, 57¹, 58¹, 59².
 — bronchial, 24²⁹⁻⁴⁵⁻⁵¹, 25²⁸, 26⁵³.
 Artery, carotid, common, 18¹⁰⁻⁵⁰, 19¹⁰⁻⁵⁵, 20⁷⁻⁶⁰, 21⁴⁻⁷⁶.
 — carotid, external, 12¹⁰⁻⁵¹, 13¹⁷⁻⁵⁰, 14²³⁻⁵⁹, 15¹⁴⁻⁴⁸, 16¹⁰⁻⁴⁵, 17¹⁴.
 — carotid, internal, 8⁶⁹, 9¹⁷⁻⁷⁷, 10²¹⁻⁶⁵, 11²⁷⁻⁷³, 12¹⁸⁻⁵¹, 13⁵¹, 14²⁶⁻⁵⁶, 15⁴⁵, 16¹⁸⁻⁴³, 17¹⁷⁻⁵⁰.
 — cerebellar, anterior inferior, 9³⁶.
 — cerebellar, superior, 7⁴⁴.
 — cerebral, anterior, 7².
 — cerebral, middle, 5¹⁵, 6¹⁵, 7²², 8³⁸⁻⁶⁹.
 — cerebral, posterior, 8⁵⁵.
 — cervical, ascending, 20⁸.
 — cervical, deep, 17²⁹, 18³⁸, 19²⁴⁻⁴⁴.
 — cervical, superficial, 20²³.
 — circumflex, of axillary, anterior, 22⁵⁰.
 — circumflex, of axillary, posterior, K6, 22²⁰⁻⁸⁰, 23³⁰.
 — circumflex, of iliac, deep, 37¹⁴, 38⁵⁹, 39¹¹, 45¹⁰⁻⁶¹.
 — circumflex, of iliac, superficial, 45¹⁰, 46⁷, 47⁸⁻⁵¹.
 — circumflex, of thigh, external, 43⁵⁷, 47⁹, 48¹⁰, 49⁹.
 — circumflex, of thigh, external descending branch, 42¹⁶, 44¹⁹.
 — circumflex, of thigh, internal, 47¹⁰⁻⁴⁷, 48¹⁴⁻³³.
 — circumflex, of thigh, internal branch of, 49¹⁴⁻²⁸.
 — celiac, K6.
 — colic, left, 31⁵³, 32⁵², 33⁵⁰.
 — colic, right, 34¹¹, 35¹⁵, 36¹⁶, 37¹⁵, 38¹⁴.
 — communicating, of brain, posterior, 8⁶².
 — coronary, of heart, left, K6, 25⁷⁰, 26⁵⁷.
 — coronary, of heart, left anterior descending branch, 25⁶⁸⁻⁷³, 26⁷¹, 27⁷⁶.
 — coronary, of heart, right, K6, 25², 26⁴, 27⁷.
 — cystic, 31¹⁵.
 — digital of hand, palmar, 74¹⁻⁴⁻⁷⁻²⁵, 75¹.
 — dorsal of foot, 108²⁵, 109¹, 110³.
 — dorsal of penis, 42¹.
 — dorsal of scapula, 23³³⁻⁷⁶⁻⁷⁸.
 — epigastric, deep, K6, 36⁴, 37⁴, 38⁶⁸, 39⁵⁻⁷⁰, 40⁹⁻⁶⁴, 45⁸.
 Artery, epigastric, superficial, 45⁷⁻⁶⁶, 46⁵, 47⁷⁻⁵².
 — epigastric, superior, 29⁷⁸, 30⁵.
 — external plantar digital branch, 111¹⁷, 112⁹⁻¹³.
 — facial, 14¹⁰⁻⁶⁹, 15⁸⁻⁴⁹, 16¹¹⁻⁴⁹.
 — facial, branch of, 17⁵⁸.
 — femoral, common, K6, K11, 41⁹⁻⁶³, 42⁶⁹, 43⁶⁰, 44²⁶, 46⁸⁻⁵¹, 47⁴⁹, 48⁹⁻⁴⁰, 49⁷⁻³⁴, 76¹, 77², 78², 79², 80², 81⁴, 83⁵, 84², 85⁴.
 — femoral, deep, K6.
 — frontal, 5¹, 7⁹⁸, 8⁸⁶.
 — frontal, branch of, 3³⁻⁴⁰, 4².
 — gastric, or coronary, 29⁶⁶⁻⁶⁴⁻⁶⁸, 30⁸².
 — gastric, branch of, 30⁷⁸.
 — gastric, cesophageal branch, 27⁵⁷, 28⁴⁹.
 — gastro-duodenal, 31¹¹, 32¹.
 — gluteal, 35⁴⁰, 36⁶⁴, 37⁴⁰, 38⁵⁹, 39²⁸, 45³⁴⁻⁴¹, 46²⁵⁻³⁴.
 — gluteal, inferior branch of, 40²⁸⁻⁴⁴, 41²³⁻²⁹⁻⁴⁷, 42³⁰⁻⁵⁰, 43²⁸⁻⁴⁶, 45²⁷⁻⁴⁶, 46¹⁹, 47¹⁹⁻³⁹, 48³⁰.
 — hæmorrhoidal, middle, 45²⁸⁻⁴⁵, 46²³⁻³⁷.
 — hæmorrhoidal, inferior, 48²¹⁻²⁹.
 — hepatic, 30⁴.
 — ileo-colic, 35⁴⁰, 36⁹, 37⁹, 38¹⁹.
 — iliac, common, K6, 35³⁸, 36²⁸⁻⁴⁹.
 — iliac, external, K6, 37¹⁹⁻⁴⁵, 38¹⁷⁻⁵⁶, 39¹³⁻⁵⁹, 40¹¹⁻⁶³, 45¹¹.
 — iliac, internal, K6, 37²⁰⁻⁴⁵, 38²²⁻⁵², 39²⁴⁻⁵¹.
 — ilio-lumbar, 35³²⁻³⁷, 36⁴⁴, 38²³⁻⁴⁹.
 — ilio-lumbar, branch of, 37³².
 — infra-orbital, 10⁷³.
 — innominate, 22¹.
 — intercostal, 21⁹, 22⁴¹, 23⁶⁶, 24²⁸, 25³⁵⁻⁴⁵, 26¹⁸⁻³¹⁻³⁶⁻⁴⁸, 27²³⁻²⁷⁻⁴⁰⁻⁴⁴⁻⁵⁰, 28²⁹⁻³⁶⁻⁴³, 29⁴⁹, 30⁴⁰⁻⁵².
 — interosseous, of arm, common, 61⁸.
 — interosseous, of arm, anterior, 62², 63²⁸, 64¹³, 65²³, 66¹⁴.
 — interosseous, of arm, posterior, 62¹⁸, 63¹⁴, 64¹², 65¹², 66¹².
 — interosseous, dorsal of foot, 111¹.
 — interosseous, dorsal of hand, 73²³.
 — interosseous, palmar, 72²³.

- Artery, lachrymal, 87³.
 — lingual, 167-200.
 — lumbar, 313⁵.
 — mammary, internal, K6, 21⁸, 22⁶⁻⁹⁴, 24¹, 25⁵, 26³⁻⁷⁴, 27¹, 28³⁻⁷⁷.
 — maxillary, internal, 10⁸, 11¹⁶⁻⁸⁸.
 — meningeal, middle, 5¹¹, 6¹⁷⁻⁷⁰, 9²¹, 10¹⁶⁻⁶⁵, 11²⁴⁻⁷⁵.
 — meningeal, middle, branch of, 27, 3¹¹, 4¹².
 — mesenteric, inferior, 33⁵⁸, 34⁵⁴.
 — mesenteric, superior, K6, 31⁴⁰, 32⁶¹, 33⁶³, 34⁶⁴.
 — mesenteric, superior, branch of, 32⁶⁰.
 — musculo-phrenic, 29⁵⁶.
 — obturator, 40⁹⁻⁶⁴, 41¹⁰⁻⁶⁰, 42⁶⁷, 45¹⁵⁻⁵⁴, 46¹¹, 47³⁹, 48¹².
 — obturator, external branch, 49³¹.
 — occipital, 6³⁷, 7⁴⁷, 8⁴³, 10⁵⁵, 11⁴⁰, 12⁴⁴, 13²⁰, 15¹⁶.
 — occipital, branch of, 3¹⁸, 11⁴⁵⁻⁵⁵.
 — of the corpus cavernosum, 43².
 — ophthalmic, 8¹⁷⁻⁸³.
 — ovarian, 45¹³⁻⁵⁵.
 — palatine, posterior or descending, 11⁹⁰.
 — perforating, first of profunda femoris, 42²²⁻⁶², 43²⁵⁻⁵⁰, 44⁸, 76¹⁸.
 — perforating, branch of, 77¹⁹.
 — perforating, second of, 79¹⁹.
 — perforating, third of, 81¹⁹, 82⁹.
 — peroneal, 94¹², 95¹², 96¹³, 97¹², 98¹⁰, 99¹², 100¹², 101¹³, 102¹³, 105¹⁵.
 — phrenic, inferior, 28²³⁻⁵³, 29⁵⁰⁻⁵², 30⁷⁷.
 — phrenic, superior, 23³, 24¹⁰⁻⁶⁸, 26¹⁵⁻⁶⁵, 27¹⁹⁻⁷¹, 28⁶⁸.
 — plantar, external, 108¹¹, 109¹⁵, 110¹⁵.
 — plantar, internal, 108⁹, 109¹⁴, 110¹².
 — popliteal, 86⁸, 87¹⁰, 88², 89¹³, 90¹⁵, 91¹⁸, 92⁹, 93¹³.
 — posterior scapular, 21⁶².
 — princeps cervicis, 12⁴¹, 13⁴¹.
 — profunda, of brachial, inferior, 52⁸, 53⁸, 54⁷.
 — profunda, of brachial, superior, 50¹⁰, 51¹⁰.
 — profunda, articular branch of, 52¹⁵, 53¹⁵, 54¹⁵, 55¹¹.
 — profunda, median collateral branch of, 52¹², 53¹².
 — profunda, of femoral, 41⁶², 42¹⁷⁻⁵⁷, 43¹⁹⁻⁵⁶, 44¹⁵, 48³⁹, 49³⁻³³, 76³⁰, 77²⁵, 78³², 79⁹, 80¹³, 81¹, 82¹⁴, 83¹⁶.
 — pudic, internal, 40²⁵⁻⁴⁹, 41²⁷, 42¹⁴, 45²⁵⁻⁴⁸, 46²¹, 47³⁷.
 — pulmonary, 24⁷¹.
 — pulmonary, branch of, 25¹⁸⁻⁵⁸, 26²⁰, 27²¹.
 — pulmonary, left, K6, 24⁵².
 — pulmonary, right, K6, 24¹⁵.
 — pyloric, 31⁶⁴⁻⁷³, 32⁶⁰.
 — pyloric, branch of, 31⁶⁴.
 — radial, K9, 60³⁰, 61²⁹, 62³⁷, 63²⁶, 64²², 65²⁸, 66²⁸, 67²², 68²², 69²¹, 70²⁵, 71²¹.
 Artery, ranine, 15².
 — recurrent, radial, 58¹⁸, 59²³, 60²⁶.
 — recurrent, ulnar, 58⁹, 59¹³, 60¹².
 — renal, K6, 30⁶², 31²⁷⁻⁴⁶, 32²².
 — renal, branch of, 30⁶⁴⁻⁶⁴⁻⁶⁶, 31⁴³⁻⁵⁰.
 — sacral, lateral, 28⁸¹, 39³², 40⁸¹, 41³⁵, 45²⁸.
 — sacral, middle, 36⁴³, 37³⁶, 38⁴², 45³⁶.
 — sciatic, 39²⁴⁻⁴⁸⁻⁴⁹.
 — sigmoid, 35⁴², 36⁶³, 37⁵⁹⁻⁶⁸.
 — sigmoid, branch of, 38⁵⁷, 40³³.
 — spermatic, 33⁴⁴⁻⁴⁷, 34²¹⁻⁴⁹, 35²²⁻⁴⁸, 36⁵⁶, 37¹⁶, 38¹⁵⁻⁶⁰.
 — sphenopalatine, 10⁷.
 — splenic, K6, 29⁵⁸, 30⁷¹.
 — subclavian, 21⁶, 22²⁷.
 — submental, 16⁵⁴.
 — subscapular, 23³⁶⁻⁷⁵, 24²²⁻⁵⁷, 26²².
 — suprarenal inferior, 29³⁰.
 — suprarenal superior, 28³⁰.
 — suprascapular, 21²³.
 — tarsal, external, 107²⁰.
 — temporal, deep, anterior, 10⁶⁷.
 — temporal, deep, posterior, 10⁶⁷.
 — temporal, superficial, 6²⁰, 7²⁰, 8²⁰, 9²⁸⁻⁶⁵, 10¹⁹⁻⁶¹, 11²⁶⁻⁷⁴.
 — temporal, branch of, 1⁶, 2³, 3¹¹, 4¹³⁻¹⁷.
 — thoracic, long, 22⁵⁵, 23¹⁶⁻⁸⁷, 27²²⁻⁶².
 — thyroid, inferior, K6, 20⁶⁻⁹¹.
 — thyroid, superior, 17¹¹, 18⁵².
 — tibial, anterior, K11, 94¹⁵, 95¹⁵, 96¹⁷, 97¹⁷, 98¹⁵, 99², 100¹⁵, 101¹, 102⁵, 103¹⁹, 104¹⁹, 105¹⁸, 107²².
 — tibial, posterior, K11, 94⁵, 95⁵, 96⁴, 97², 98⁴, 99⁵, 100⁵, 101⁷, 102⁷, 103⁶, 104¹, 105⁸, 106⁷, 107⁹.
 — transversalis colli, K6, 20²⁵.
 — ulnar, K9, 60², 61⁷, 62⁶, 63⁶, 64⁵, 65⁵, 66⁴, 67³, 68⁴, 69³, 70⁴, 71³, 72¹.
 — ulnar deep, 72¹⁴.
 — umbilical, 45¹².
 — uterine, 45¹⁹⁻²⁹⁻⁵³.
 — vaginal, 45²³, 46⁴², 47¹⁶.
 — vasa brevia, 28⁵².
 — vertebral, K6, 11⁴²⁻⁶⁰, 12³⁹, 13²⁵⁻⁴⁷, 14³²⁻⁵⁰, 15³⁸, 16²³, 17²³⁻⁴³, 18⁴⁷, 19¹³⁻⁵², 20¹⁰⁻⁵⁹.
 — vesical, inferior, 40²⁷⁻⁴⁵.
 Articulation, sacro-iliac, 37⁴³, 39²⁹.
 Aryteno-epiglottidean folds, 17⁵.
 Atlas, 12²⁶.
 Attic of tympanum, 9³¹.
 Auricle of heart, left, K6, 25¹⁴, 26⁶¹.
 — of heart, right, K6, 26⁷, 27⁸.
 Auricular appendix, right, 25⁶.
 Auriculo-ventricular groove, 26²⁹, 27⁵.
 Axilla, 22⁶⁶, 23¹⁸⁻⁸⁵.
 Axis, 14¹², 15²⁵.
 — spinous process of, 14⁴⁰, 15²⁰.
 Bicipital groove of humerus, K4.
 Bile duct, common, 32⁸.
 Bladder, gall, K7, 32¹¹, 33¹⁰.
 — urinary, K8, 41³⁹, 46²⁷, 47⁶.
 Bladder, urinary, apex of, 40², 45².
 — urinary muscular coat of, 41⁷⁰, 46²⁵, 47⁵⁶.
 Bone, astragalus, K13, 107³, 108⁴.
 — coccyx, K8, 41³⁷, 45³⁷, 46²⁹.
 — cuboid, K13, 109²¹, 110²⁴.
 — cuneiform, of carpus, K9, 70¹².
 — cuneiform, of tarsus, K13, 110⁴⁻⁷⁻²⁷.
 — frontal, K2, K3, 1²⁰, 2³⁻²², 3⁶⁻³⁵, 4⁷⁻¹⁸, 5⁶, 6⁷, 7⁹⁻⁸⁸, 8⁹¹.
 — hyoid, K3, 17³³.
 — iliac, K4, 35²⁴, 36²⁰⁻³³, 37²⁸, 38²⁹, 39¹⁶⁻⁴⁵, 40², 41⁴, 45³⁶.
 — ischial, K4.
 — lachrymal, K2, 9³⁰.
 — malar, K2, 8²¹, 10³, 11¹⁴.
 — metacarpal, K9, 71²⁵, 72¹¹⁻¹⁵⁻²¹⁻²⁷, 73¹⁰⁻¹³⁻¹⁶⁻¹⁹.
 — metatarsal, K13, 110²³, 111³⁻²³⁻²⁵⁻³⁰, 112³⁻²³⁻²⁵, 113³⁻⁸⁻¹²⁻¹⁵.
 — metatarsal, tubercle of, 110²².
 — nasal, K2, K3, 9³⁰.
 — navicular of foot, tuberosity of, 109⁶.
 — occipital, K2, K3, 5²⁵, 6¹¹, 7⁴⁵⁻⁵⁶, 8⁴⁰, 10⁴⁷, 11³⁰.
 — occipital, basilar portion, 102²²⁻⁷⁵, 114⁴.
 — occipital, protuberance of, 9¹¹.
 — parietal, K2, K3, 1⁹, 2⁸⁻¹⁶, 3¹⁷, 4²²⁻³², 5¹⁷⁻²⁵, 6²⁷⁻⁶³, 7⁶⁷, 8³⁷.
 — pisiform, K9.
 — pubic, 41², 47²⁵.
 — sesamoid of foot, 113⁵.
 — scaphoid, of carpus, 70²¹.
 — scaphoid, of tarsus, K13, 109⁴.
 — semilunar, K9, 70⁶.
 — sphenoid, 87, 9².
 — sphenoid, pterygoid process of, 10⁸.
 — sphenoid, spine of, 10¹⁷.
 — temporal, 6¹⁸, 7²⁵⁻⁷⁷, 8²⁶⁻⁶⁵, 9²⁶⁻⁵⁸⁻⁶⁹, 10²⁰, 11⁶³.
 — temporal, mastoid portion of, K2, 9²⁵.
 — temporal, petrous portion of, 9³⁰.
 — temporal, tympanic portion of, K2.
 — trapezium, K9, 71²².
 — trapezoid, K9, 71¹⁸.
 — unciform, K9, 71¹¹.
 Bronchus, left, 24⁵⁰, 25¹⁰⁻⁵⁷⁻⁶².
 — right, 24²⁶⁻⁶³, 25²⁵.
 Bulb, olfactory, 8³.
 — urethral, 43³⁹.
 Bulla of ethmoid, 9⁶.
 Bundle of Vieq d'Azayr, 6¹⁹, 7⁸⁴.
 Bursa, Bursae. See BNA INDEX.
 Cæcum, 39⁷, 40⁶.
 Calcaneum, K13, 107¹², 108¹⁵, 109¹⁹.
 — lateral process of, 108¹⁴.
 Calcar avis, 7²⁸⁻⁶².
 Calcarine fissure, 6²⁹.
 Calices, of kidney, 31²⁸.
 Canal of Hunter, 84⁶.
 — incisive, 12².
 — sacral, 38³⁸.
 — semicircular superior, 9²³.

- Capsule of cerebrum, external, 5¹⁴, 6¹¹⁻⁷⁵, 7⁷⁵.
 — of cerebrum, internal, 5¹⁰, 7³¹⁻⁷⁴.
 — of cerebrum, internal frontal part, 6⁸⁻⁷⁷, 7⁸⁵.
 — of cerebrum, internal knee of, 6¹⁰⁻⁷².
 — of cerebrum, internal occipital part, 6²²⁻⁵⁰.
 Cardiac portion of stomach, 28⁵⁷.
 Cartilage, arytenoid, 19².
 — cricoid, K7.
 — of ear, 8³³, 11²⁹⁻⁷².
 — of epiglottis, K3, 17⁶⁴, 18².
 — of nose, K8.
 — of nose, septal, K3, 10⁸¹, 11⁹⁰.
 — of Santorini, 18⁵⁸.
 — thyroid, K7, 18⁵⁷, 19⁶⁷.
 — triticeal, 17¹³.
 Carunculae myrtiformes, K8.
 Cauda equina, 33³⁵, 34³⁷.
 Caudate nucleus, tail of, 5¹⁹, 6⁵⁴, 7⁶⁸, 8⁶¹.
 Cavity, sigmoid of ulna, greater, 59⁸.
 Cerebellum, K2.
 — biventral lobe of, 11⁵⁷.
 — central lobe of, K3, 7⁵¹.
 — crescentic, posterior lobe of, 9²⁹⁻⁵¹.
 — medullary layers, K3.
 — quadrate lobe of, 8²⁹.
 — semilunar, inferior of, 10³⁴⁻⁴⁶⁻⁵¹, 11⁵³.
 Chamber of eyeball, anterior, 8¹³, 9⁸⁵.
 Chorda tympani, 10⁵⁶.
 Chordæ tendinæ, 25⁷⁷, 26⁶⁷.
 Choroid plexuses, K3, 5⁷, 6³³⁻⁴⁶⁻⁸², 10⁴².
 Choroid skein, 6⁵³.
 Claustrum, 5¹³, 6⁶⁷, 7⁷⁶.
 Clavicle, K4, K5, 20²⁰⁻⁴⁹, 21⁶⁷, 22⁹¹.
 Clitoris, K8, 48²⁻⁴⁷.
 — glans of, K8, 49²⁰.
 Cochlea, 10⁹⁷.
 Colon, ascending, K7, 34²⁰, 35²⁰, 36¹⁹, 37¹¹, 38⁹.
 — descending, K7, 30⁶⁷, 31⁵⁶, 32⁵³, 33⁵², 34⁵², 35⁵¹, 36⁵², 37⁵⁵, 38⁵¹.
 — hepatic flexure, 34¹⁵.
 — sigmoid flexure, K7, 39²⁷⁻⁶⁶.
 — splenic flexure, 29⁶³.
 — transverse, K7, 30⁷³, 31⁵⁹, 32⁵⁹, 33⁵⁹⁻⁷¹, 34⁷².
 Columnæ carneæ, 27³⁻⁷⁵.
 Columns of Morgagni, 42¹².
 Commissure of cerebrum, anterior, K3, 6¹, 7⁷⁹⁻⁹⁶.
 — of cerebrum, middle, K3, 6²⁶.
 — of cerebrum, posterior, K3, 7⁵⁹.
 Condyle of femur, internal, 90⁸.
 — of tibia, external, 92¹⁸.
 — of tibia, internal, 92².
 — occipital, 12⁴¹.
 Conus arteriosus, 24⁷⁴.
 Convolution, frontal, inferior, K2, K3, 4¹⁰, 5⁴⁴, 6⁷³.
 — frontal, orbital part of, 7⁸⁷.
 — frontal, middle, K2, 3³⁶, 4⁴³⁻⁴⁵, 5⁴⁴⁻⁴⁷⁻⁴⁹, 6⁸⁰.
 Convolution, frontal, superior, K2, 1³, 2²³, 3²⁻³⁹, 4⁴⁷⁻⁴⁹, 5⁵², 6⁸⁴, 7³⁻⁹⁴.
 — hippocampal, 7⁴²⁻⁵⁵, 8⁵⁰, 9⁹⁸.
 — occipital, lateral, K2, 7⁵⁸, 8⁵², 9¹⁸.
 — occipital, superior, 6¹⁸⁻⁵².
 — occipito-temporal, 8⁵¹, 9⁵³.
 — orbital, 8⁷⁰.
 — postcentral, K2, 1¹⁰, 2¹⁷, 3¹²⁻³¹, 4¹⁴⁻³⁸, 5⁴⁰.
 — precentral, K2, 2¹⁹, 3⁸⁻³³, 4¹¹⁻⁴⁰, 5⁴².
 — supramarginal, K2, 4¹⁵⁻³⁶, 5³⁸, 6⁶⁶.
 — temporal, inferior, K2, 8⁵⁹, 9²⁷⁻⁵⁶.
 — temporal, middle, K2, 8⁶³, 9⁶⁰.
 — temporal, superior, K2, 6⁵⁵⁻⁶², 7⁶⁵⁻⁶⁹⁻⁷⁸, 8⁶⁷, 9⁷³.
 Cornua of hyoid bone, 16⁴³, 17⁶¹.
 — of lateral ventricles, inferior, 8²⁸⁻⁶⁰.
 — of lateral ventricles, posterior, 5²⁰, 7³⁹.
 — of thyroid cartilage, superior, 18⁹.
 Corona radiata, 5³⁷.
 Coronoid process of mandible, 11¹⁶⁻⁸⁴.
 Corpus callosum, body of, 5³⁰.
 — callosum, knee of, K3, 5², 6⁸³.
 — callosum, striations of, 5³³.
 — callosum radiations, of frontal part, 3⁴, 4⁴⁻⁴⁴.
 — callosum radiations, of occipital part, 3¹⁹, 4²¹⁻²⁹.
 — callosum radiations, of parietal part, 3⁷, 4¹⁰⁻³⁷, 5³⁷.
 — cavernosum, of penis, 42², 43⁷⁰.
 — cavernosum, of urethra, 43¹⁻⁸.
 Crista galli, 8⁹².
 Crus of diaphragm, medial, 31³³⁻⁴², 32²², 33²².
 — of penis, 43⁹.
 Crusta of cerebral peduncle, 7³¹.
 Culmen of cerebellum, 8⁴⁶.
 Cuneate lobule of cerebrum, K3, 4²⁷, 5²⁷, 6⁴⁴, 7⁴⁹.
 Cystic duct, 31¹⁴.
 Declive of cerebellum, 9⁴⁶.
 Decussation of the mesial fillets, 11⁴⁹.
 Dentate fascia, 6³⁵.
 Diaphragm, K7, 27⁶⁷, 28¹⁵⁻⁶⁶, 29⁶⁻¹⁶⁻³²⁻⁴⁹, 30¹⁰⁻³⁰, 31⁵¹.
 Disc, interpubic, 41⁷², 47¹.
 — intervertebral, 21⁸⁰, 27⁴³, 28³⁸, 29⁴¹, 34³⁰, 37³⁵, 38³⁶.
 — triangular radioulnar articulation, 70⁷.
 Duodeno-jejunal flexure, 30⁷⁵, 31⁵⁸.
 Duodenum, K7.
 — papilla of, 33¹¹.
 — first part, 31⁶, 32².
 — second part, 32¹², 33¹³.
 — third part, 31⁵², 33⁴, 34¹³.
 Dura mater, of brain, 1²¹, 2², 4⁶, 7¹⁸, 10³³.
 — of spinal cord, 19³⁵, 21⁴¹, 30⁴⁴, 33³⁴, 35³⁵, 38³⁵.
 Epicranial aponeurosis, 11¹⁹, 2¹¹, 3²⁰, 4²⁰, 5³⁴, 6³¹, 8⁴².
 Epidermis, 1¹⁴.
 Epiglottis, K3, 16⁵⁵.
 Ethmoid bone, perpendicular plate of, 9⁹⁵.
 — cells of, 8⁵, 9⁸¹⁻⁸⁷.
 Eustachian cushion, 11⁹³.
 — tube, 10¹³, 11¹³.
 — tube, pharyngeal opening, K3, 11⁷.
 — tube, tympanic opening, 10⁶³.
 Eye, anterior chamber of, 8¹³, 9⁸⁵.
 Fallopian tube, K8, 45⁶⁻⁴⁹⁻⁶².
 Falx of cerebrum, 2¹, 3¹, 4¹⁻²⁴, 7¹⁰⁰.
 Fascia, anal, 41⁴⁴, 42⁴⁰, 47²³⁻³³.
 — bicipital, K10, 59³¹, 60¹.
 — endopelvina, 42⁷.
 — of forearm, deep, 62²².
 — iliac, 39⁵⁸.
 — lata, 41³³⁻⁶⁵, 43⁴⁴, 44²⁹, 45¹⁶⁻⁵⁷, 46⁴⁶, 47¹³, 48¹³⁻³⁶, 77¹², 83³.
 — lumbodorsal, 41³⁸, 45³⁷.
 — obturator, 40⁵³, 45¹⁸, 46¹⁵.
 — palmar, 72³, 73².
 — pelvic, 40²⁶, 41²⁰⁻⁴², 45³², 46²⁶⁻³⁵.
 — pelvic, visceral, 47²³⁻³⁵.
 — of penis, 42⁷⁹, 43⁷².
 — plantar, 109¹⁴, 110¹⁴, 111¹², 112¹², 113⁹.
 — temporal, 9²⁵⁻⁷².
 — transversalis, 34¹⁴, 36⁷⁰, 38⁶⁵, 40⁶⁸, 46³⁴.
 Fastigium, K3.
 Femur, K11, 43²³, 44¹⁰, 48³⁵, 76²⁰, 77¹⁰, 78¹⁷, 79¹⁹, 80¹⁶, 81²³, 82¹⁸, 84¹⁸, 85¹, 86¹⁷, 87², 88¹⁷, 89², 90².
 — head of, K4, 40⁵⁶, 41³⁷, 46¹²⁻⁴⁵.
 — neck of, 42⁵⁸, 47⁴⁵.
 — external epicondyle of, K11, 90²⁶.
 — internal epicondyle of, K11, 90⁵.
 Fibula, K11, K13, 93¹⁵, 94¹³, 95¹³, 96¹⁴, 97¹⁴, 98¹², 99¹³, 100¹³, 101¹², 102¹⁴, 103¹⁵, 104¹⁴, 105¹⁴, 106¹⁵.
 — external malleolus of, K13, 107¹⁷.
 — head of, 92¹⁶.
 Fillet, mesial, 10³⁹.
 Filum terminale of dura mater, 39³⁷, 40³⁶.
 Fimbria of hippocampus, 6³²⁻⁵¹, 7³⁵⁻⁶⁶.
 Fissure, callosal, K3, 5²⁴, 6⁴⁷⁻⁸⁵.
 — calloso-marginal, K3.
 — frontal, superior, 3³⁷, 4⁴⁶, 5⁵¹.
 — interparietal, K2, 3¹⁶⁻²⁷, 4³⁰, 5³¹.
 — interparietal, of Turner, 2²⁹, 4⁴¹.
 — occipital, anterior, K2.
 — parieto-occipital, K2.
 — of Rolando, K2, 1⁸, 2¹⁸, 3¹⁰⁻³², 4³⁹, 5⁴¹.
 — sphenoidal, 9¹⁴.
 — sphenomaxillary, 9¹⁴.
 — of Sylvius, K2, 5¹³, 6⁷¹, 7⁸¹, 8⁶⁸.
 — temporal, middle, K2, 8⁸⁴.
 — temporal, superior, K2.
 Flocculus of cerebellum, 9³⁵, 10²⁸⁻³³.

- Fold, epigastric, deep, 38², 39⁴⁻⁷¹, 40⁶.
- Foramen cæcum, posterior of Vieq d'Azyr, K3.
- cæcum, of tongue, 15⁶².
- jugular, 10²⁴.
- of Monro, K3.
- obturator, K4.
- ovale of sphenoid, 10⁶⁶.
- of sacrum, K4, 38³², 39³⁴⁻⁴¹.
- thyroid, K4.
- of Winslow, 31¹⁶.
- Fornix, anterior pillar of, 6³, 7³³.
- body of, K3, 5²¹, 6⁵³.
- posterior pillar of, 6⁵¹.
- Fossa, coronoid, 58⁴.
- digital, of femur, 47¹⁵⁻⁴⁴.
- ischio-rectal, 42³⁶, 43³⁴, 47²²⁻³⁶, 48²⁷, 49¹⁹.
- olecranon, 58¹⁰.
- of Rosenmüller, 11¹⁵.
- radial, of humerus, 58¹⁷.
- spheno-maxillary, 9¹².
- Ganglion, cervical, superior, 13¹⁹⁻⁵¹, 14²⁸⁻⁵⁵, 15⁴³, 16⁴¹.
- Gasserian, 9²⁰.
- Meckel's, 10⁷³.
- nodosum, 11³¹⁻⁶⁸.
- spinal, 13³².
- thoracic, 21²⁸.
- Geniculate body, external, 7³³.
- body, internal, 7³⁷.
- Gladiolus of sternum, K4, K5, 24⁷⁵, 25¹, 26¹, 27¹.
- Gland, carotid, 17¹³.
- lachrymal, orbital portion, 7¹⁵, 8⁷⁵.
- lachrymal, palpebral portion, 8¹⁹.
- palatine, 12⁴.
- parotid, 11²⁴⁻²⁸⁻⁷²⁻⁷⁷, 12⁵², 14⁵⁸, 15¹⁵⁻⁴⁷.
- sublingual, 14³, 15⁴⁻³⁷.
- submaxillary, 15¹⁰⁻⁵¹, 16¹⁶, 17⁷⁻⁵⁹.
- thyroid, left lobe, 20⁶³, 21⁷⁷.
- thyroid, right lobe, K7, 19³, 20³.
- Globus pallidus, 6¹³, 7²⁸⁻⁸².
- Gluteal ridge of femur, 76¹⁹.
- Gums, 14⁶.
- Gyrus. See CONVOLUTION.
- Gyrus angularis, K2, 4¹⁸, 5³⁶, 6⁵⁸.
- fornicatus, 5²⁸⁻⁵³, 6⁴⁵⁻⁸⁵.
- paracentral, K3, 2¹, 3²⁹⁻³⁸, 4²⁴.
- rectus, 8²⁷.
- subcalcarine, K3, 7⁵⁰⁻⁵⁴, 8⁴⁷, 9⁵⁰.
- superior parietal, K2, 2¹⁵, 3²⁶, 4²⁷, 5³⁰.
- uncinata, 7⁴²⁻⁵⁵, 8⁵⁶, 9⁶⁸.
- Head of caudate nucleus, 5⁵, 6⁶⁻⁸¹, 7⁸⁹.
- of femur, 40³⁶, 41⁵⁷, 46¹²⁻⁴⁵.
- of fibula, 92¹⁶.
- of humerus, 21²¹⁻⁶⁹.
- of malleus, 9³¹.
- of metacarpal bone, 74¹⁰⁻¹³⁻¹⁷⁻²¹.
- of metatarsal bone, 112¹⁹, 113³.
- of pancreas, 32⁶.
- Head of radius, K9.
- Heart, K7.
- Hepatic duct, 30¹¹, 31¹².
- Hippocampus, Cornu Ammonis, 6²⁴, 7²⁶⁻⁶⁴.
- minor or Calcar avis, 7²⁸⁻⁶².
- Humerus, K9, 22⁴⁻⁷⁶, 23²⁶, 50¹⁹, 51¹⁸, 52¹⁹, 53¹⁹, 54⁹, 55⁹, 56⁹, 57⁹, 58¹³.
- external epicondyle of, K9, 58¹⁴.
- head of, K4, K5.
- internal epicondyle of, 58⁷.
- trochlea, K9.
- Hunter's canal, 84⁶.
- inferior opening of, 85¹⁰.
- Hypophysis or Pituitary body, K3, 9⁶.
- Ilio-pectineal line, 39¹⁸.
- Ilio-tibial band, 87¹⁷, 88¹⁵, 91²⁷.
- Ileum, 34²⁻⁷⁻⁸, 35⁶⁻⁸⁻¹⁴⁻¹⁶⁻¹⁷⁻⁷¹, 36³⁻⁸⁻¹⁵⁻¹⁷⁻⁵¹⁻⁵⁸⁻⁶⁵⁻⁶⁷⁻⁶⁸⁻⁷¹⁻⁷³, 37⁷⁻⁷⁻¹³⁻⁵⁴⁻⁵⁸⁻⁶⁰⁻⁶¹⁻⁶³⁻⁶⁴⁻⁶⁵⁻⁶⁶⁻⁶⁹⁻⁷⁰, 38²⁻⁴⁻⁶⁻⁸⁻¹¹⁻⁶⁴⁻⁶⁷⁻⁶⁹⁻⁷¹, 39²⁻⁶⁻¹³⁻¹⁸⁻⁵⁷⁻⁶⁸⁻⁷²⁻⁷³, 40⁵⁻²⁰⁻⁶⁶⁻⁶⁹⁻⁷¹.
- Infundibulum of brain, cavity of, 8³¹.
- of ethmoid, 8⁶.
- Intercondyloid notch of femur, 90⁶.
- Intermuscular septum, external of femur, 77²⁰, 78¹⁴, 79¹⁶, 80¹², 81¹⁸, 82¹³, 84¹⁵, 86¹⁵.
- septum, internal of femur, 80¹⁷, 81⁹, 82².
- septum, external of upper arm, 51¹⁶, 52¹⁶, 53¹⁶, 54¹¹, 55¹², 56¹¹, 57¹⁶.
- septum, internal of upper arm, 52⁹, 53⁹, 54⁸, 56⁷, 57⁶.
- Interosseous membrane, radio-ulnar, 61¹⁴, 62¹¹, 63⁸, 64²⁴, 65⁸, 66³, 67¹⁹, 68¹¹.
- membrane, tibio-fibular, 93²⁰, 94¹⁹, 96¹⁹, 99¹⁷, 101¹⁶, 102¹⁶, 103¹⁶.
- Interpeduncular space, 8³⁵.
- Intestine, large, cæcum, K7.
- large, rectum, K7, 40²⁹, 45³⁹, 46³⁰.
- large, circular fibres of, 42²⁸.
- large, longitudinal muscle fibres of, 42³⁷.
- large, anal canal, K8, 42⁴².
- Ischium, ramus of, 43³¹, 48³⁰.
- Island of Reil, 61⁴, 7⁸⁰.
- Jejunum, 30⁷², 31⁵⁵⁻⁵⁷, 32⁵⁴⁻⁵⁷⁻⁵⁸⁻⁶⁴, 33⁵³⁻⁵⁵⁻⁵⁶⁻⁶⁶, 34⁵³⁻⁵⁵⁻⁵⁸⁻⁶³⁻⁶⁹, 35³⁻⁴⁹⁻⁵³⁻⁶⁰⁻⁶¹⁻⁶³.
- Kidney, left, 29⁵⁴, 30³³.
- right, K7, 30³², 31²⁹, 33²⁴.
- pelvis of, 32²².
- Labia majora, K8, 49².
- minora, K8.
- Lachrymal gland, inferior, 8¹⁹.
- gland, superior, 7¹⁵, 8⁷⁵.
- sac, 8⁷.
- Lamina terminalis, K3, 7².
- Larynx, vestibule of, K3, 18³.
- Lens, 8¹⁴.
- Ligament, annular, anterior, of wrist, 70³, 71³².
- annular, posterior, of wrist, 70¹⁷.
- atlanto-axial transverse, 13²⁰.
- broad, of uterus, 45¹⁴.
- calcaneo-astragaloid external, 108²⁰.
- common, of vertebra, anterior, 11⁸⁷, 12⁶⁷, 13⁶⁴, 32⁵⁹, 34³¹, 35⁴¹, 36³², 38²⁸.
- common, of vertebra, posterior, 18²⁰, 37²⁸.
- coraco-clavicular, 21¹⁵⁻⁶⁵.
- coronary, of liver, 28²²⁻²⁴, 29²⁵.
- crucial, of atlas, 12²⁸.
- crucial, of knee joint, anterior, 90²⁴, 91²⁰.
- crucial, of knee joint, posterior, 91⁷.
- dentate, of spinal cord, 19¹².
- external lateral, of foot, anterior fasciculus, 107¹⁸.
- external lateral, of foot, posterior fasciculus, 107¹⁶.
- external lateral, of knee joint, 91²⁵.
- falciform, 28¹, 29³, 30³, 21¹.
- glenoid, 46⁴².
- hepato-colic, 33⁸.
- hepato-duodenal, 31¹⁵.
- hepato-renal, 31²⁵.
- ilio-femoral, 40¹⁶, 41¹⁵, 46¹³.
- ilio-lumbar, 36¹⁶.
- interclavicular, 22¹⁰⁰.
- internal lateral, of knee joint, 91⁵.
- internal lateral, of ulna, 59¹¹.
- interspinous, 29⁴¹.
- long plantar, 109¹⁷, 110²⁰.
- obliterated hypogastric, 37⁷¹, 38⁷⁰, 39¹⁰⁻⁵⁵⁻⁶⁹, 45⁵⁻⁷⁰.
- occipito-atlantal, 12³¹, 13³⁹.
- occipito-axial, posterior, 12²⁸.
- orbicular, of radius, 59¹⁸⁻²³.
- lateral phalangeal, 74¹⁶.
- piso-unciform, 71⁶.
- piso-metacarpal, 71⁸.
- patellar, K12.
- of Poupert, K5, 39¹¹⁻⁶³, 40¹⁹, 45⁶², 46⁵².
- pterygomandibulare, 13¹⁰⁻⁵⁶.
- pubic, inferior, 42³.
- radio-carpal, anterior, 70²⁸.
- radio-carpal, posterior, 70¹⁴.
- round, of femur, 40¹⁷, 41¹⁵, 46¹².
- round, of liver, 31⁵, 32³, 33³, 34¹, 35².
- round, of uterus, K8, 45⁹⁻⁶³, 46⁶⁻⁵², 47⁵⁻⁵⁴, 48³⁻⁴⁸.
- sacro-iliac, anterior, 37²⁵.
- sacro-iliac, posterior, 37²⁷⁻⁴¹, 38⁴⁰, 39⁴⁶.
- sacro-sciatic, great, 41⁴⁰, 42⁴⁷, 45²⁰⁻⁴², 46²²⁻³⁶, 47²²⁻³⁷.
- sacro-sciatic, small, 41³¹, 45²⁹⁻⁴², 46²⁰.
- spheno-mandibular, 11²⁰⁻⁵⁵, 12¹⁶⁻⁵³.
- stylo-hyoid, 16⁹⁻⁵¹.
- subflava, 17³⁴, 18²⁸, 19²⁷⁻³⁷, 20²⁵, 22⁵², 30¹⁰, 32²⁵, 33²⁷, 34²⁵, 36³⁷, 37³⁴.

- Ligament, supraspinous, 30⁴⁷.
 — suspensory, of penis, K5.
 — temporo-mandibular, 10¹⁸, 11⁷⁰.
 — thyro-arytenoid, inferior, 19⁶³.
 — tibio-tarsal, posterior, 107⁹.
 — triangular, of liver, 30³¹.
 — vaginal, of fingers, 75⁷.
 — vaginal, of toes, 113¹.
 Ligamentum venosum (Arantii), 28⁷³, 29³.
 — latum pulmonis, 26⁵³, 27¹⁸.
 — nuchæ, K3, 11⁵⁰, 12³³, 13³⁵, 16⁵⁰, 17³³, 18³¹, 19³⁰, 20³⁴.
 — patellæ, 91³¹, 92¹⁹, 93²².
 — patellæ, external, 90²⁸.
 — patellæ, internal, 90⁴, 91².
 Linea alba, K5, 30¹, 31¹, 32⁷², 33⁷², 34⁷³, 35¹.
 — aspera, 78¹⁵, 80¹⁴, 81²⁰, 82¹⁵, 84¹⁶, 85³.
 — semilunaris, 34⁶⁵, 35⁶⁵, 36⁷, 38⁷.
 Lip, lower, 13⁶³.
 Liver, K7.
 — caudate process, 30², 31¹⁹, 32¹⁴.
 — left lobe, 28⁶⁹, 29⁸⁰, 30⁹⁰, 31⁷⁴, 32⁷¹.
 — papillary process, 30⁸⁸.
 — posterior surface, 29²⁸.
 — quadrate lobe, 32⁷, 33⁵.
 — right lobe, 28¹⁷, 29²⁰, 30²⁴, 31²¹, 32¹⁸, 34¹⁸.
 — Spigelian lobe of, 28⁷⁵, 29⁷¹, 30¹⁴.
 — umbilical notch, K7.
 Lumbo-sacral cord, 38²⁴⁻⁴⁸, 39²².
 Lung, K7.
 — fissure of, 23⁶³.
 — inferior lobe, 22⁵⁸, 23⁶⁵, 24³³⁻⁴⁶, 25³³⁻⁵¹, 26²⁷⁻⁵², 27²⁹⁻⁵², 28¹⁸⁻²⁶⁻⁴⁸, 29²⁹.
 — middle lobe, 24¹⁴, 25¹⁷, 26¹¹.
 — superior lobe, 21³⁵, 22⁷, 23⁷⁻¹¹⁻⁹⁶, 24²⁴⁻⁶⁵, 25²⁶⁻⁶⁵, 26⁶⁴, 27⁷⁰.
 Lymphatic glands, 17¹, 24²⁹, 31³⁴, 32¹⁶, 35⁵⁰⁻⁵⁶, 42¹², 43¹², 45⁵⁶.
 — axillary, 22⁶⁷, 23⁷³⁻⁸⁰.
 — inguinal, 47⁵¹, 49³⁶.
 — mediastinal, 23³, 25³¹.
 Malar bone, orbital surface, 91⁶.
 Mammillary body, K3, 7²⁶.
 Mandible, K3, 14⁸⁸, 15⁶⁰, 16⁴.
 Manubrium, of sternum, K4, 23².
 Mastoid antrum, 9³⁴.
 — cells, 10²⁵⁻⁵⁵, 11³⁴⁻⁶⁷.
 Maxilla or superior maxilla, K2, K3, 10³, 11¹⁰, 12².
 — orbital surface, 9⁷.
 Meatus, auditory, external, K2, 10⁵⁸.
 — of nose, inferior, 11³.
 — of nose, middle, 9⁸⁹.
 — of nose, superior, 9⁸⁹.
 Mediastinum of thorax, anterior, 24¹, 25⁷⁹.
 Medulla oblongata, 12³⁴.
 Mental protuberance, K2.
 Mesentery, 35⁷, 36⁵⁹⁻⁶⁹, 37⁵⁻⁶⁷, 38⁶⁶.
 Meso-colon, transverse, 30⁷⁷, 31⁶³.
 Mitral valve, posterior cusp, 26⁶⁶.
 Monticulus of cerebellum, K3.
 Mouth, vestibule of, 12⁸, 14⁷⁰.
 Muscle, abductor digiti quinti, of the foot, 109¹⁶, 110²¹, 111²⁰, 112¹⁸.
 — abductor hallucis, 108¹⁹, 109⁸, 110⁸, 111⁷, 112⁷, 113⁴.
 — abductor minimi digiti, 71⁷, 72⁸, 73⁸, 74⁸.
 — abductor pollicis, 71²⁸, 72²⁹.
 — accelerator urine, 43³⁹.
 — accessorius, 25³², 28³⁰.
 — adductor brevis, K5, 42⁷², 43⁹², 44⁴, 48⁵⁻⁴⁵, 49⁶⁻³², 76⁷, 77⁷, 78¹².
 — adductor hallucis, 112¹⁹, 113⁷.
 — adductor hallucis, transverse portion, 111¹⁵.
 — adductor longus, K5, K12, 42⁷³, 43⁹³, 44³¹, 48⁴⁻⁴⁴, 49⁴, 76³, 77⁴, 78⁴, 79⁵, 80¹, 81⁷, 82³, 83².
 — adductor magnus, K5, 44⁴, 49¹⁷⁻²⁹, 76¹⁰, 77¹¹, 78⁶, 79⁸, 80⁸, 81¹⁴, 83⁸, 84⁷, 85⁶, 86⁴, 87⁵, 88⁵.
 — adductor minimus, 43³¹, 44¹⁰, 48⁶⁻³⁵, 49¹⁴⁻²⁹, 76¹⁷.
 — adductor pollicis, 72²¹, 73²¹.
 — anconæus, 59¹⁷, 60¹⁶, 61¹⁵, 62¹⁴.
 — arytenoid, transverse fibres of, 19⁶⁴.
 — atollens aurem, 62³⁻⁶⁵, 77⁰, 9⁶¹.
 — attrahens aurem, 9⁶³.
 — biceps brachii, K5, K10, 53²¹, 54¹⁷, 55¹, 56¹⁷, 57¹⁸, 58²³, 59³⁰, 60²⁸, 61².
 — biceps brachii, long head, 21¹⁹, 22²³⁻⁷⁶, 23²⁴, 50¹, 51²⁰, 52²¹.
 — biceps brachii, short head, 22²¹⁻⁷⁹, 23⁸¹, 50¹, 51¹, 52²².
 — biceps femoris, 42³², 43³⁹, 47¹⁸⁻⁴⁹, 48¹⁹⁻³¹, 85¹⁶, 86¹⁴, 87¹⁶, 88¹⁴, 90²⁵, 91²⁴, 92¹⁷.
 — biceps femoris, long head, 44⁶, 49¹⁶⁻²⁶, 76¹³, 77¹⁵, 78¹⁰, 79¹⁵, 80¹¹, 81¹⁶, 82¹¹, 83¹⁵, 84¹³.
 — biceps femoris, short head, 81¹⁷, 82¹², 84¹⁴.
 — brachialis anticus, K10, 52¹⁷, 53¹⁸, 54¹⁵, 55¹⁵, 56¹⁴, 57¹⁵, 58²⁰, 59²⁷, 60¹⁴.
 — brachioradialis, 55¹³, 56¹², 57¹³, 58¹⁹, 59²⁴, 60²⁴, 61²⁵, 62²³, 63²¹, 64²⁰, 65²¹, 66²², 67²¹, 68²¹, 69¹⁸.
 — buccinator, 12⁹, 13⁹⁻⁵⁹, 14⁹⁻⁷¹.
 — bulbocavernosus, 43³⁹.
 — cervicalis ascendens, 20⁴³, 22⁴².
 — coccygeus, 41²⁸⁻³²⁻⁴³, 45³¹, 46³³.
 — complexus, 10³⁷, 11³², 12³⁶, 13³¹, 14³⁶⁻⁴¹, 15²⁶, 16²⁶, 17³⁸, 18²⁹⁻³³, 19²⁹⁻⁴⁰, 20³³⁻³⁹, 21³⁹⁻⁴⁵.
 — compressor nares, 10⁸⁰, 11²⁻⁹⁷.
 — constrictor pharyngis, inferior, 18⁸.
 — constrictor pharyngis, superior, 11⁸⁹, 13²⁸.
 — constrictores pharyngis, K3, 12⁵, 13⁵, 14⁹¹, 15⁹⁰, 16¹⁴⁻⁴⁵, 17⁹⁵, 18⁹³, 19⁹¹.
 — coracobrachialis, K5, 22²¹⁻⁷⁹, 23³¹, 50⁴, 51³, 52².
 — corrugator supercilii, 79⁷.
 Muscle, cremaster, K5, 43⁹⁷.
 — crurens, K5, 42²³⁻⁶⁰, 44¹⁷, 48³⁷, 49¹⁶⁻³³, 76²⁵, 77²⁴, 78¹⁹, 79²¹, 80¹⁵, 81²¹, 82¹⁷, 83¹⁸, 84¹⁹, 85¹³.
 — deltoideus, K5, K10, 20¹⁸⁻⁵³, 21¹⁶⁻²⁴, 22²⁴⁻⁷⁵, 23²⁷, 50¹⁸, 51¹⁷, 52¹⁶.
 — depressor anguli oris, 14³⁻⁷⁴, 15⁶⁻⁹⁶.
 — depressor lobii inferioris, 14⁷⁷, 15⁷.
 — depressor menti, 15².
 — digastricus, K2, 13¹⁶, 15¹³⁻⁴⁷, 16³⁻¹²⁻⁴⁸⁻⁵⁶.
 — digastricus, posterior belly, 12²²⁻⁴⁵, 13²³, 14²⁵.
 — erector penis [vel clitoridis], 42¹⁸, 43¹², 48¹⁷⁻²⁸.
 — extensor brevis digitorum, 108¹⁹, 109²², 110²⁶, 111²⁶, 113¹⁷.
 — extensor carpi radialis brevis, 59²¹, 60²², 61²³, 62²¹, 63¹⁹, 64¹⁶, 65¹⁷, 66¹⁹, 67¹⁹, 68¹⁸, 69¹⁴, 70¹⁹, 71¹⁷.
 — extensor carpi radialis longus, 57¹², 58¹⁶, 59²¹, 60²², 61²³, 62²¹, 63¹⁹, 64¹⁶, 65¹⁷, 66¹⁹, 67¹⁹, 68¹⁸, 69¹⁴, 70¹⁹, 71¹⁷.
 — extensor carpi ulnaris, 59¹⁹, 60¹⁸, 61¹⁷, 62¹⁵, 63¹², 64¹⁹, 65¹⁰, 66¹⁹, 67¹¹, 68¹⁹, 69⁹, 70¹¹, 71⁹.
 — extensor digitorum communis, 59¹⁹, 60²⁰, 61¹⁹, 62¹⁸, 63¹⁷, 64¹⁵, 65¹⁵, 66¹⁵, 67¹⁴, 68¹⁴, 69¹², 70¹⁶, 71¹³, 72¹⁷, 74¹⁴⁻¹⁸, 75⁹.
 — extensor digitorum longus, K12, 93¹⁹, 94¹⁷, 95¹⁸, 96¹⁸, 97¹⁶, 99¹⁵, 100¹⁷, 101¹⁸, 102¹⁹, 103¹⁸, 104¹⁷, 105¹⁶, 106²⁰, 107²¹, 108²³, 109²⁴, 110²⁸, 111²⁸, 112²⁰⁻²², 113¹⁷.
 — extensor hallucis brevis, 108²¹, 109²⁵, 110¹, 111³, 112².
 — extensor indicis, 65¹¹, 66⁷, 67¹², 68¹², 69¹¹, 70¹², 71¹⁰, 72¹⁸, 73¹⁷, 75¹¹.
 — extensor minimi digiti, 59¹⁹, 60¹⁹, 61¹⁸, 62¹⁷, 63¹⁵, 64¹², 65¹³, 66¹³, 67¹³, 68¹², 69¹⁰, 70¹³, 71¹¹, 72¹², 73¹¹, 74¹¹, 75⁴.
 — extensor ossis metacarpi pollicis, 63¹⁶, 64¹⁴, 65¹⁴, 66¹⁷, 67¹⁸, 68¹⁹, 69¹⁷, 70²⁵, 71²⁸.
 — extensor primi internodii pollicis, 66¹⁶, 67¹⁹, 68¹⁷, 69¹⁸, 70²⁴, 71²⁴, 72²⁶.
 — extensor secundii internodii pollicis, 62¹³, 63¹³, 64¹¹, 65¹², 66¹¹, 67¹⁰, 68¹⁵, 69¹³, 70¹⁸, 71²⁰, 72²⁵, 73²⁴.
 — extensor proprius hallucis, 93¹⁹, 94¹⁷, 95¹⁶, 96¹⁸, 97¹⁶, 99¹⁵, 100¹⁹, 101¹⁹, 102²⁰, 103²¹, 104²⁰, 105¹⁹, 106²¹, 107¹, 108¹, 109², 110⁵, 111⁴, 112⁴, 113².
 — flexor accessorius, 108¹², 109¹³, 110¹⁶.
 — flexor carpi radialis, K10, 59⁶, 60⁶, 61⁴, 62¹, 63⁴, 64²⁵, 65²², 66²⁵, 67²⁴, 68²⁴, 69²³, 70²⁹.
 — flexor carpi ulnaris, K10, 59⁴, 60¹⁸, 61¹¹, 62⁸, 63⁷, 64⁷, 65⁸, 66⁸, 67⁴, 68⁸, 69⁴, 70⁸, 71²⁹.

- Muscle, flexor digitorum brevis, of the foot, 109¹², 110¹³, 111¹⁴, 112¹⁵, 113¹⁶.
- flexor digitorum longus, of the foot, K12, 96⁷, 97⁸, 98⁹, 99¹⁰, 100¹¹, 101¹², 102¹³, 103¹⁴, 104¹⁵, 105¹⁶, 106¹⁷, 107¹⁸, 108¹⁹, 109²⁰, 110²¹, 111²², 112²³⁻²⁵.
- flexor digitorum profundus, 59¹⁵, 60¹⁶, 61¹⁷, 62¹⁸, 63¹⁹, 64²⁰, 65²¹, 66²², 67²³, 68²⁴, 69²⁵, 70²⁶, 71²⁷, 72²⁸, 73²⁹, 74³⁰⁻³²⁻²⁴⁻²⁷, 75³³⁻³⁵.
- flexor digitorum sublimis, K10, 59¹⁹, 60²⁰, 61²¹, 62²², 63²³, 64²⁴, 65²⁵, 66²⁶, 67²⁷, 68²⁸, 69²⁹, 70³⁰, 71³¹, 72³², 73³³, 74³⁴⁻³⁶⁻²⁴⁻²⁷, 75³⁷⁻³⁹.
- flexor hallucis brevis, 109⁷, 110⁸, 111⁹, 112¹⁰, 113¹¹.
- flexor hallucis longus, 97¹³, 98¹⁴, 99¹⁵, 100¹⁶, 101¹⁷, 102¹⁸, 103¹⁹, 104²⁰, 105²¹, 106²², 107²³, 108²⁴, 109²⁵, 110²⁶, 111²⁷, 112²⁸.
- flexor minimi digiti, of the foot, 111¹⁸, 112¹⁷.
- flexor minimi digiti, of the hand, 72⁸, 73⁸.
- flexor pollicis brevis, 72²³, 73²⁶.
- flexor pollicis longus, K10, 62²⁴, 63²², 64¹⁹, 65¹⁸, 66²⁴, 67²³, 68²³, 69²², 70³⁰, 71³¹, 72³⁰, 73²⁷.
- frontalis, 3⁵, 4⁵, 5¹⁴⁻¹⁸.
- gastrocnemius, K12, 92¹³, 93¹⁴, 94¹⁵, 95¹⁶, 96¹⁷, 97¹⁸, 98¹⁹, 99²⁰, 100²¹.
- gastrocnemius, external head of, 90²³, 91²².
- gastrocnemius, internal head of, 89²³, 90²⁴, 91²⁴.
- gemellus, inferior, 41³⁸⁻⁵².
- gemellus, superior, 41³⁴⁻⁴⁹, 46³⁷⁻⁴⁹.
- genioglossus, K3, 14¹, 15¹.
- geniohyoideus, K3, 16³, 17².
- gluteus maximus, 38²⁷⁻⁴⁵, 39²⁹, 40³²⁻⁴⁴, 41²⁶⁻⁴⁵, 42⁴⁶⁻⁵⁵, 43²⁴⁻³²⁻⁴³, 44¹¹⁻¹⁴, 46⁴¹, 47³⁶⁻³², 48²²⁻²⁸, 49¹⁸⁻²⁴, 76¹⁶⁻¹⁹, 77¹⁷, 78¹³.
- gluteus medius, K5, 36²⁵⁻⁴⁷, 37¹⁸, 38²⁵, 39²³, 40³², 41¹⁶, 42³⁷, 45³², 46⁴⁹, 47¹³⁻⁴⁵.
- gluteus minimus, 37¹⁵⁻⁵⁵, 38²⁹, 39³⁴, 40³⁴, 41¹⁷, 45³⁸, 46⁴⁷, 47¹⁴⁻¹⁶.
- gracilis, K5, K12, 42⁴⁻⁷⁶, 43¹⁰, 44³², 48⁴⁹, 49³⁻³⁷, 76⁹, 77⁸, 79⁷, 81⁸, 83⁹, 84⁵, 85⁹, 86⁷, 87⁹, 88⁸, 89¹⁰, 90¹¹, 91¹⁰, 92³, 93³.
- hyoglossus, 14⁸⁻⁷⁵, 15⁶⁻⁵⁵, 16³, 17⁴⁻⁶².
- iliacus, 36²⁷, 37⁴⁷.
- iliocostalis, 21¹⁹, 22⁶⁰, 23⁴⁷, 24³², 26³², 27³²⁻⁴⁹, 29³⁴, 30³⁶.
- iliopsoas, K5, 38²⁰, 39²⁸, 40⁶¹, 41¹²⁻⁵⁹, 42²¹⁻⁵⁹, 43²⁰⁻⁵³, 45⁵⁹, 46⁴⁹, 47⁴⁷, 48¹³⁻⁵⁹, 49¹¹, 76²⁶.
- infrapinnatus, 21²⁵⁻⁵⁹, 22³³⁻⁷¹, 23³⁷⁻⁷², 24²⁷.
- intercostalis externus, 21⁵⁰, 22¹¹⁻³⁸⁻⁶³, 23¹⁴⁻⁴¹⁻⁴⁵, 26¹⁴⁻¹⁹, 27³³⁻⁶⁴, 29¹⁹⁻²⁴, 30¹³⁻²³⁻²⁵.
- Muscle, intercostalis internus, K5, 21⁵¹, 22¹²⁻⁴⁰⁻⁵⁹, 23¹⁰⁻¹⁵⁻⁴²⁻⁴⁵⁻⁶⁸⁻⁹⁴, 24⁸⁻⁶⁶, 25⁷⁻¹³, 26⁵⁻¹⁴⁻²⁸, 27⁶⁻¹⁴⁻²⁸, 28¹⁰⁻⁶⁵, 29⁷⁻⁷⁶, 29¹¹⁻¹⁹⁻²⁴, 30¹³⁻²³, 31⁹.
- interfoveolaris, 40⁶⁷.
- interosseus dorsalis, of the hand, 72¹⁶⁻¹²⁻²², 73¹²⁻¹⁵⁻¹⁸⁻²², 74¹⁵⁻¹⁹⁻²⁷, 75⁵⁻⁸⁻¹⁰.
- interosseus dorsalis, of the foot, 111¹⁹⁻²⁹, 112¹⁻¹⁶⁻²¹⁻²⁴.
- interosseus plantaris, 111²¹⁻²⁴⁻²⁹, 112²⁴.
- interosseus volaris, 72¹⁰⁻¹⁴⁻²⁰, 73⁷⁻¹⁴⁻²⁰, 74¹²⁻¹⁵⁻¹⁹, 75⁵⁻⁸⁻¹⁰.
- intertransversarius, 13²³, 14³⁰, 34²⁹⁻⁴¹.
- latissimus dorsi, K5, 22²², 23³²⁻⁸⁰, 24²³⁻⁵⁵, 25²³⁻⁵⁹, 26²⁶⁻⁵⁶, 27²⁴⁻⁵⁸, 28²¹, 29²², 30²⁹, 31²⁴, 32⁴³, 33²⁶, 34²⁷, 50¹³.
- levator anguli oris, 10³, 11⁴, 12³⁻⁶³.
- levator anguli scapulae, K2, 14²⁹⁻⁵³, 15²²⁻⁴⁹, 16²³⁻³⁷, 17²⁶⁻⁴¹, 18¹⁹⁻⁴³, 19²³, 20²⁶⁻⁴⁴.
- levator ani, K8, 41⁵⁰, 42²⁷⁻⁴⁵, 43⁴¹, 47²⁴⁻³⁴.
- levator costae, 21³⁴⁻⁴⁷, 25⁴⁷.
- levator labii superioris, 9²², 10³, 11⁹⁻⁹⁵.
- levator palati, 11²³⁻⁷⁹, 12¹⁷⁻⁵⁴.
- levator palpebrae superioris, 7¹², 8⁷⁹.
- levator superioris alaeque nasi, 9⁴.
- lingual superficial, 13⁹².
- longissimus dorsi, 21⁴⁸, 22¹⁶⁻⁵⁵, 23³¹⁻⁶¹, 24³⁴, 25²⁸, 26³⁴, 27³⁴, 28³⁴, 29⁴⁷, 30⁴¹, 31³², 32³¹, 33³⁰, 34⁴², 35³², 36³⁵.
- longus colli, 13¹³⁻⁵³, 14²², 15²⁰, 16³⁸, 17⁴⁹, 18¹²⁻⁵¹, 19⁵⁸, 20⁵, 21³.
- lumbrical, of the foot, 111¹¹⁻¹³, 112¹⁴.
- lumbrical, of the hand, 72⁶, 73¹⁻⁴, 74²⁻⁹⁻²³⁻²⁶, 75⁵⁻⁸⁻¹⁰.
- masseter, K2, 10¹⁴⁻⁶⁸, 11¹⁹⁻⁷⁸, 12¹², 13³⁷, 14¹⁸⁻⁶³, 15¹⁰⁻⁵¹.
- multifidus spinae, 15³³, 16³¹, 17³⁵, 18³⁴, 19³¹⁻³⁸, 20³², 21⁴⁴, 22⁴⁹, 23⁵⁸, 24⁴⁰, 25³⁹, 26³⁹, 27³⁹, 29⁴⁴, 30⁴⁵, 31³⁹, 32³⁸, 33³⁷, 34³⁷, 35³⁸, 36³⁹, 37³³, 38³³, 39⁴².
- mylohyoideus, K2, K3, 14¹³⁻⁶⁷, 15⁷⁻⁵², 16³⁷, 17⁶⁷.
- obliquus capitis inferior, 13²⁷⁻⁴¹, 14¹⁵.
- obliquus capitis superior, 11⁶², 12⁵⁶.
- obliquus externus abdominis, K5, 28¹³, 29⁹⁻⁷¹, 30¹²⁻⁸¹, 31⁶¹, 32¹⁰, 33¹⁵⁻⁶², 34¹²⁻⁶⁰, 35¹¹⁻⁵⁷, 36¹¹, 37¹¹.
- obliquus inferior oculi, 8¹⁸, 9⁸⁻⁸⁹.
- obliquus internus abdominis, K5, 32¹⁵, 33¹²⁻²⁰⁻⁵⁸, 34¹⁶⁻⁶¹, 35¹²⁻⁵⁸, 36¹², 38⁸, 39⁶⁷, 40⁷⁻⁶⁵, 46⁵³.
- obliquus superior oculi, 7⁷, 8⁸².
- obturator externus, K5, 42⁷⁰, 43⁴⁵, 47⁷⁻¹⁵⁻⁴³, 48¹⁵⁻³⁴.
- obturator internus, 39²¹, 40²²⁻⁵⁰, 41¹⁴⁻²¹⁻⁵²⁻⁵⁶, 42²⁶⁻⁵⁶, 45¹⁸, 46¹⁵, 47¹²⁻⁴².
- Muscle, occipitalis, 5²², 6³⁷, 7⁴¹, 8³⁶⁻⁵³, 9⁴²⁻⁵⁴.
- omohyoideus, K5, 18⁴, 19³⁻⁶⁰, 20⁵⁹.
- opponens minimi digiti, of the foot, 111²².
- opponens minimi digiti, of the hand, 72⁷, 73⁹.
- opponens pollicis, 71²⁷, 72²⁸.
- orbicularis oculi, 7⁶⁻¹¹⁻⁹⁵, 8⁷¹, 9¹⁵⁻⁸¹, 10⁹, 11¹².
- orbicularis oris, K3, 12⁶⁸, 13⁶⁻⁶¹, 14⁷².
- palatoglossus, 13⁷.
- palatopharyngeus, 12⁹, 13⁸, 14¹⁵, 15⁵⁰, 16¹⁰⁻⁴⁷, 17⁸.
- palmaris brevis, 71⁴, 72⁵.
- palmaris longus, K10, 59⁹, 60⁷, 61³, 62⁴, 63⁴, 64⁵, 65², 66³, 67¹, 68¹, 69²³, 70³², 71².
- papillares, 27⁸².
- pectineus, K5, 40⁶³, 41⁷⁻⁶⁶, 42¹⁰, 43⁵², 44¹², 45⁵⁰, 47⁸⁻⁵³, 48⁷⁻⁴⁰, 49¹²⁻³⁰.
- pectoralis major, K5, K10, 22⁹, 23²⁰⁻³³, 24⁷⁻⁶⁷, 25⁹⁻⁷³, 26⁹, 27⁷⁸, 28⁷, 50²¹.
- pectoralis minor, K5, 22¹⁰⁻⁵³, 23¹⁸⁻⁸⁹, 24¹²⁻⁶⁴, 25¹², 26¹².
- peroneus brevis, K12, 94¹⁶, 95¹³, 96¹⁶, 97¹⁵, 98¹³, 99¹⁴, 100¹⁴, 101¹⁴, 102¹³, 103¹³, 104¹², 105¹², 106¹⁴, 107¹⁵, 108¹⁸, 109²⁰.
- peroneus longus, K12, 93¹⁷, 94¹⁶, 95¹³, 96¹⁶, 97¹⁵, 98¹³, 99¹⁴, 100¹⁴, 101¹⁴, 102¹³, 103¹³, 104¹², 105¹², 106¹⁴, 107¹⁵, 108¹⁸, 109¹⁸, 110¹⁹, 111⁶.
- peroneus tertius, 106¹⁷, 107¹⁹, 108²², 109²³, 110²⁵.
- piriformis, 39³³⁻⁴³, 40³³⁻⁴⁸, 45²²⁻⁴⁹, 46¹⁶⁻⁴⁴.
- plantaris, 89¹⁸, 90²⁰, 91²⁰, 92¹⁴, 93⁹, 94⁷, 95⁹, 96⁷, 97⁸, 98⁹, 99⁵, 100⁷, 101⁸, 102⁸, 103⁸, 104⁸, 105⁸, 106⁸.
- popliteus, 92¹⁵, 93⁷, 94³, 95².
- pronator quadratus, 67⁶, 68⁸, 69⁷.
- pronator teres, K10, 58⁵, 59⁵, 60⁵, 61¹, 62⁸, 63²⁵, 64¹⁷.
- psoas major, 31²², 32²⁹, 33⁴², 34⁴⁴, 35²⁶⁻⁴⁵, 36²⁴⁻⁵⁶, 37⁵¹.
- pterygoideus externus, 9¹⁹, 10¹⁰⁻⁶⁹, 11²²⁻⁵⁰, 12¹¹⁻⁶⁰.
- pterygoideus internus, 11¹¹⁻⁸³, 12⁶¹, 13¹²⁻⁵⁵, 14²¹, 15¹².
- pyramidalis, K5, K8, 39⁴, 40¹, 41², 45⁷¹, 46¹, 47³⁻⁵⁷.
- pyramidalis nasi, 7¹⁻⁹⁹, 8⁹², 9¹.
- quadratus femoris, K5, 42²⁸⁻⁵⁴, 43²⁶, 47¹⁶⁻⁴¹, 48¹⁶⁻³³.
- quadratus lumborum, 30⁵³, 32⁴², 33²⁷⁻⁴⁴, 34²⁶, 35²⁶.
- quadriceps extensor, tendon of, 87¹⁹, 88¹, 89²¹.
- rectus abdominis, K5, K8, 28⁴, 29⁵⁻⁷⁸, 30⁹⁰, 31³⁻⁶⁹, 32¹⁻⁶⁹, 33³⁻⁶⁹, 34³⁻⁷⁰, 35⁴⁻⁶⁹, 36³⁻⁷², 37², 38¹, 39³, 40³, 41⁷¹, 45⁶⁸, 46³, 47².

- Muscle, rectus abdominis, sheath of, K5, 37^a, 40^a, 45⁶⁸, 46⁵⁰.
- rectus capitis anticus major, 10¹¹, 11²⁰⁻⁸¹, 12¹⁴, 13¹³⁻⁵³, 14²², 15⁴¹, 16¹², 17²⁰⁻⁴⁹, 18¹²⁻⁵¹, 19¹².
- rectus capitis anticus minor, 11²⁰, 12²¹.
- rectus capitis lateralis, 11³⁶, 12²³⁻⁴⁴.
- rectus capitis posterior major, 12²⁸, 13³⁴, 14³⁰.
- rectus capitis posterior minor, 12³⁰, 13³⁵.
- rectus external, 8²⁰, 9⁸⁰.
- rectus femoris, K5, K12, 40¹⁴⁻⁵⁹, 41¹³⁻⁵⁸, 42¹⁸⁻⁶⁵, 43¹⁵, 44²⁴, 45¹⁰⁻⁵⁷⁻⁶⁰, 46¹⁰, 47⁴⁸, 48¹⁰, 49⁸, 76²⁷, 77²³, 78²¹, 79²⁰, 80¹⁸, 81²², 82¹⁹, 83¹⁹, 84²⁰, 85¹⁹, 86¹⁸.
- rectus inferior, 9¹¹⁻⁸⁴.
- rectus internal, 8¹⁰.
- rectus superior, 7¹², 8⁷⁷.
- retrahens aurem, 9³⁴.
- rhomboideus major, 21³⁶, 22⁴³, 23⁴⁹, 24³², 25⁵⁰.
- rhomboideus minor, 20³⁰, 21⁴⁹.
- sacrolumbalis, 31³⁰, 32²⁹, 33³⁰⁻⁴⁰, 34⁴², 35³², 36³⁵, 37³³⁻³⁹, 38³³, 39⁴².
- sartorius, K5, K12, 39⁶¹, 40¹²⁻⁶⁰, 41¹², 42¹⁴, 43¹⁵, 44²⁷, 45⁶¹, 46⁵⁰, 47⁴⁹, 48⁸, 49⁷, 76²⁹, 77²⁶, 78²³, 79¹, 80⁴, 81², 82⁴, 83⁷, 84⁴, 85⁷, 86⁵, 87⁷, 88⁸, 89⁸, 90¹⁰, 91¹¹, 92⁵, 93³.
- scalenus anterior, K5, 17²¹⁻⁴⁸, 18¹³⁻⁴⁸, 19¹⁶, 20¹²⁻⁵⁷, 21⁸⁻⁷³.
- scalenus medius, K5, 14³⁰⁻⁵², 15²¹⁻⁴⁰, 16²²⁻³⁸, 17²¹⁻⁴⁴, 18¹⁶, 19²⁰, 20⁴⁵, 21¹¹⁻⁶⁹.
- scalenus posterior, 19²⁰, 20⁴⁵.
- semimembranosus, 43²⁹, 44⁶, 48¹⁸⁻³², 49¹⁵⁻²⁷, 76¹², 77¹³, 78⁷, 79¹¹, 80⁷, 81¹¹, 82⁹, 83¹⁰, 84⁸, 85¹¹, 86⁹, 87¹², 88¹⁰, 89¹², 90¹², 91¹², 92⁴.
- semispinalis colli, K3, 15²⁸⁻³¹, 16³¹, 17³¹⁻³⁶, 18²⁷⁻³³, 19³⁰⁻³⁹, 20³³⁻³⁹.
- semispinalis dorsi, 22⁴⁹, 24⁴⁰, 25³⁹, 26³⁹, 27³⁹, 29⁴⁴, 30⁴⁵.
- semitendinosus, 43³⁰, 44⁵, 48¹⁸⁻³¹, 49¹⁰⁻²⁶, 76¹¹, 77¹⁴, 78⁸, 79¹², 80⁹, 81¹², 82⁷, 83¹¹, 84⁹, 85¹², 86¹⁰, 87¹¹, 88⁹, 89¹¹, 90¹³, 91¹³, 92⁷, 93³.
- serratus magnus, K5, 21²⁸⁻⁵³, 22³⁷⁻⁶⁵, 23³⁹⁻⁶⁹, 24¹⁸⁻⁶¹, 25⁶¹, 26²⁰, 27¹⁸⁻⁶³, 28⁶⁰, 29¹⁵, 30²¹.
- serratus posterior inferior, 28²⁵⁻⁵¹, 29⁵³, 30⁶⁰, 32⁴⁴.
- serratus posterior superior, 20²⁷, 21³¹, 22⁶¹.
- soleus, K12, 92¹⁵, 93¹⁴, 94¹¹, 95¹¹, 96⁶, 97⁶, 98⁹, 99⁸, 100⁹, 101¹⁰.
- sphincter ani externus, K8, 43³⁶, 48²³, 49²³.
- sphincter ani internus, K8, 43³⁷, 48²⁶, 49²⁰.
- spinal, 23⁵⁸, 29⁴⁴.
- spinalis capitis, 12³².
- Muscle, spinalis colli, 19³¹⁻³⁸, 20³², 21⁴⁴.
- spinalis dorsi, 22⁵⁰, 23⁵⁹, 24³⁶, 25⁴², 26⁴¹, 27³⁹, 30⁴⁵, 31³⁹, 32³⁸.
- splenius capitis, K2, 10²⁹⁻⁴⁹, 11⁴¹⁻⁵⁹, 12²⁸, 13²⁹⁻⁴², 14³⁵⁻⁴⁹, 15³⁵, 16²⁵, 17³⁷, 18²⁵⁻³⁶, 19²⁸⁻⁴¹, 20⁴⁰.
- splenius colli, 14²⁰⁻⁵³, 15²⁰⁻³⁹, 16²⁴⁻³⁵, 17²⁸⁻³⁹, 18²³⁻³⁹, 19²⁵, 20⁴⁰, 21³⁷.
- sternocleidomastoideus, K2, K5, 10²⁶, 11⁶⁶, 12²⁴⁻⁴³, 13²⁴⁻⁴⁵, 14³¹⁻⁵¹, 15²²⁻³⁸, 16¹⁹, 17¹⁶⁻⁴⁰, 18¹⁴, 19¹¹, 20¹¹⁻⁵⁴, 21⁷², 22³.
- sternohyoideus, K2, K5, 18⁴, 19⁶⁻⁶⁵, 20⁶⁶⁻⁶⁹, 21², 22⁹³, 23⁹⁷.
- sternothyroideus, K2, K5, 20⁴⁻⁶², 21⁷⁷, 22⁹⁵, 23¹⁰⁰.
- styloglossus, 13¹⁶, 14¹⁷⁻⁶⁴, 15¹¹⁻⁵³.
- stylohyoideus, K2, 13¹⁶, 14²⁴⁻⁶⁰, 15¹³⁻⁴⁸, 16¹³⁻⁴⁸, 17⁴⁻⁶³.
- stylopharyngeus, 12¹⁹, 13¹⁶, 14¹⁹⁻⁶⁰, 16¹⁰⁻⁴⁷, 17⁸.
- subclavius, K5, 20¹⁹⁻⁵⁰, 21¹⁴⁻⁶⁶, 22⁸⁻⁸⁹.
- suberureus, 8⁶¹, 87¹.
- subscapularis, K5, 21²⁷⁻⁶⁴⁻⁶³, 22³⁴⁻⁶⁸⁻⁷⁸, 23³⁵⁻⁷¹, 24²⁷, 25⁵⁵.
- supinator brevis, 60²¹, 61¹⁶⁻²⁴, 62²⁰, 63¹⁸.
- supinator longus, K10, 55¹³, 56¹², 57¹³, 58¹⁹, 59²⁴, 60²⁴, 61²⁵, 62²³, 63²¹, 64²⁰, 65²¹, 66²², 67²¹, 68²¹, 69¹⁸.
- supraspinatus, 20¹⁰⁻⁵¹, 21⁵⁶.
- temporalis, 4⁹⁻⁴², 5⁸⁻⁴³, 6¹⁶⁻⁷⁴, 7²⁷⁻⁸³, 8²⁷⁻⁷⁰, 9²²⁻⁷¹, 10¹¹⁻⁷⁰, 11¹⁷⁻⁸⁵, 12¹³⁻⁵⁹.
- tensor palati, 11¹⁸⁻⁸⁶, 12⁶⁴.
- tensor vaginae femoris, K5, 38⁵⁸, 39¹⁴⁻⁶⁰, 40⁵⁸, 41⁵⁸, 42¹⁹⁻⁶³, 43⁵⁵, 44²², 45¹³, 46⁴⁸, 47¹¹, 48¹¹, 49³¹, 76²².
- teres major, K5, 23³¹⁻⁷⁹, 24²³, 25²⁷⁻⁵³, 50¹⁵.
- teres minor, 22²⁵⁻²⁸⁻⁷⁴, 23³⁴, 24⁵³.
- thyreoarytenoideus externus, 19⁶³.
- thyreoarytenoideus internus, 19⁴.
- thyrohyoideus, 17⁶⁻⁶⁰, 18⁵⁵, 19⁴.
- tibialis anterior, K12, 93²¹, 94¹⁸, 95¹⁷, 96²⁰, 97¹⁹, 98¹⁶, 99¹⁹, 100²⁰, 101²⁰, 102¹, 103¹, 104¹, 105¹, 106¹, 107², 108², 109³, 110⁶.
- tibialis posterior, 93¹⁸, 94², 95¹, 97², 99¹², 100², 101⁶, 102⁵, 103⁴, 104⁴, 105⁴, 106⁴, 107⁷, 108⁵, 109⁵.
- trachelomastoid, 12²⁴⁻⁴², 13²⁸⁻⁴³, 14³²⁻⁴⁸, 15²³⁻³⁷, 16²⁵⁻³⁴, 17²⁷⁻⁴⁰, 18²³⁻⁴⁰, 19⁴⁶, 21⁴⁷, 22⁴⁸.
- transversalis abdominis, K5, 30⁸⁷, 31⁷⁻⁶⁷, 32⁹, 33⁹⁻⁶⁴, 34¹⁷⁻⁶², 35¹³⁻⁵⁹, 36¹⁸⁻⁶⁰, 37¹⁰, 38¹²⁻⁶³, 39⁸, 45⁶⁴, 46⁵³.
- transversalis colli, 16³⁷, 17²⁷⁻⁴⁰, 18²¹⁻⁴², 19²², 20⁴², 21⁴⁸, 22⁴⁸.
- transversalis linguae, 13³.
- transversus perinei, 43³⁵.
- trapezius, K2, K5, 10³⁸, 11⁴⁸, 12³⁷, 13³³, 14⁴³, 15³², 17³⁷, 18²⁴⁻³⁷, 19²⁶, 20²¹⁻²²⁻⁴⁸, 21³⁰⁻⁵², 22⁴⁵, 23⁴⁸⁻⁶², 24³⁷, 25⁴⁶, 26⁴², 27⁴².
- Muscle, triangularis sterni, K5, 26⁷³, 27⁷⁹, 28⁵.
- triangularis, transverse fibres of, K3, 16¹.
- triceps, K10, 54¹⁹, 55⁸, 56⁸, 57⁷⁻⁸, 58¹².
- triceps, internal head of, 50¹⁴, 51¹³, 52¹¹, 53¹⁶.
- triceps, long head of, 22²⁹⁻⁷⁷, 23²⁹, 50¹⁶, 51¹⁴, 52¹⁶, 53¹¹.
- triceps, outer head of, 23²⁸, 50¹⁷, 51¹⁵, 52¹⁴, 53¹².
- uvulae, 13².
- vastus externus, K12, 42²¹⁻⁶¹, 43²¹, 44¹⁸, 48¹²⁻³⁸, 49¹¹⁻³⁰, 76²¹, 77²¹, 78¹⁶, 79¹⁷, 81¹⁹, 82¹⁶, 83¹⁷, 84¹⁷, 85¹⁷, 86¹⁶, 87¹⁸, 88¹⁶, 89¹⁹, 90²⁹.
- vastus internus, 43²⁴, 44¹³, 49¹⁰⁻³², 76²⁵, 77²⁴, 78¹⁹, 79²¹, 80¹⁹, 82¹, 83¹, 84¹, 85², 86², 87², 88³, 89⁴.
- zygomaticus major, 10¹², 11¹⁵, 12¹⁰⁻⁶².
- Myocardium, 26⁸, 27⁸⁰.
- Nares, 11⁹⁸.
- Nasal cavity, 81⁹⁰, 9⁸⁸⁻⁹³⁻⁹⁷, 10¹⁻⁷⁷, 11¹.
- Nasolachrymal duct, 9⁵⁻⁹¹, 10⁴⁻⁷⁷.
- Nerve abducent, 9⁷⁴, 10⁵³.
- alveolar, of mandible, 12¹⁶⁻⁵⁵, 13¹⁴⁻⁵³, 14¹⁶, 15⁹⁻⁵⁴.
- auditory, 9³³⁻⁵⁹, 10⁴⁵⁻⁵².
- auricular, great, 15¹⁸⁻⁴², 16²⁰⁻³⁹, 17²²⁻⁴⁴, 18¹⁵⁻⁴⁴.
- auriculo-temporal, 9²⁸, 11²⁵⁻⁷³.
- cardiac, superior, 22².
- cervical, 13³², 14³⁴⁻⁴⁶, 15²⁴⁻³⁶⁻⁴¹, 16²¹⁻³⁹, 17²³⁻²⁴⁻⁴³⁻⁴⁵, 18¹⁶⁻¹⁸⁻⁴⁰⁻⁴⁵, 19¹⁵⁻¹⁷, 20¹³⁻¹⁴⁻³⁷⁻⁵⁵.
- chorda tympani, 10⁵⁶.
- circumflex, K6, 22³⁰⁻⁷⁰.
- communicans, fibularis, 89¹⁷, 90²⁹, 91²¹, 92¹³, 93¹², 94¹⁹, 95¹⁰, 96¹¹, 97¹⁹.
- communicans, tibialis, 90¹⁹, 91¹⁹, 92¹⁰, 93¹¹, 94⁹, 95⁹, 96⁹, 97¹⁰.
- crural, anterior, K6, 36²⁹, 37²¹⁻⁴⁹, 38¹⁸⁻⁵⁴, 39⁶³, 40¹², 41¹¹⁻⁶¹, 42¹⁵⁻⁶⁸, 43¹⁶⁻⁵⁹, 45⁶⁹, 46⁴⁹, 47⁴⁸.
- crural, anterior, branch of, 43¹³⁻¹⁸⁻⁵⁸, 48³⁹, 49⁸⁻³⁴.
- crural, anterior, cutaneous branches, 44²⁸, 76², 77³, 78³, 79⁴, 80⁵, 81⁵, 83⁶.
- crural, anterior, muscular branches, 42⁶⁸, 44²⁰⁻²¹⁻²³, 76²⁸.
- cutaneous, external, of thigh, K6, 35²⁸, 36²⁶, 37¹⁸⁻⁵⁰, 38¹⁶⁻⁵³, 39¹²⁻⁶², 40¹³, 41¹³, 42⁶⁶, 43¹⁴, 46⁹, 47¹⁰, 48⁹, 76²⁴, 77²², 78²⁰, 79¹⁸.
- cutaneous, internal, of arm, 50⁵, 51⁵, 52⁴, 53⁴, 54⁴, 55⁴⁻⁶, 56²⁻⁵, 57², 58³, 59⁴, 60⁴, 61³, 62³, 63³, 64³.
- cutaneous, lesser internal, 50¹¹, 51¹¹.
- cutaneous, of musculo-spiral, 53¹⁷, 54¹³, 55¹⁰, 56¹⁰, 57¹¹, 58¹⁵, 59²⁰.
- dorsal, of penis, 42⁷⁷, 43¹⁻⁷¹.
- ethmoidal, posterior, 8⁹.

- Nerve, external respiratory, of Bell, 212⁶⁸, 2214-26-66, 2338-74, 2421, 2522, 2722-62, — facial, 922-69, 1024-52-56, 1132-69, 1222-47, 1320-49, 1423.
- facial, cervical branch of, 1710-54.
- frontal, 710-91, 816.
- genito-crural, 3329, 3426, 3523, 3622.
- genito-crural, crural branch of, 3410, 3514, 3625, 3726, 3828, 3912-64, 764.
- genito-crural, genital branch of, 3410, 3516, 3624, 3716-56, 3800, 3905.
- glosso-pharyngeal, 1031, 1130-71, 1218-59, 1322, 1422-58.
- gluteal, inferior, 4520-47, 4638.
- hamorrhoidal, inferior, 4310.
- hypoglossal, 1032, 1137-43-65, 1220-48, 1318-48, 1427-57, 1517-46-61, 1618-15-44-52.
- hypoglossal, descending branch of, 1618-42, 1717-51, 1811-49.
- ilio-hypogastric, 3521-59, 3625, 3712.
- ilio-inguinal, K6, 3521-49, 3623, 3714.
- infra-orbital, 103-72, 118-94.
- intercostal, K6, 219-39, 2211, 2314, 2545, 2621-37-48, 2727-50-55, 2820, 2923-45, 3019, 3114, 3225, 3420-39, 3518, 3613-61, 378.
- interosseous, anterior, 622, 6328, 6412, 6523, 6614, 672.
- interosseous, posterior, 6023, 6120, 6216-19, 6314.
- lacrimal, 714.
- laryngeal, inferior, 202-64.
- laryngeal, superior, 1510-46, 1610-44.
- laryngeal, superior, external branch, 1714-52.
- laryngeal, superior, internal branch, 1713-53, 185-54.
- lingual, 1215-56, 1310-56, 1414-65, 155-55-59.
- lingual, branch of, 141-76, 154.
- lumbar, K6, 3221-49, 3327-31-41-45, 3425-30-32-40-47, 3530-34, 3631-36, 3723.
- mandibular, 1015-66, 1121-82.
- masseteric, 1214-57.
- maxillary, superior, 1072.
- median, K9, 2218-82, 2321-82, 507, 516, 522, 533, 542, 552, 563, 572, 582, 592, 602, 616, 624, 632, 641, 651, 6626, 6722, 6825, 6924, 7021, 711, 721.
- median palmar, digital branch, 732-5-28-29, 741-7-25, 7514.
- mental, 147-72, 155-58, 162.
- musculo-cutaneous, of arm, 2220, 2322, 502, 512, 521, 531.
- musculo-cutaneous, of arm, cutaneous branch of, 541, 5515, 5616, 5715, 5822, 5929, 6029, 6128, 6228, 6327, 6423.
- musculo-cutaneous, of leg, 9316, 9414, 9514, 9615, 9814, 9916, 10016, 10117.
- musculo-cutaneous, of leg, internal dorsal branch, K11, 10217, 10418, 10517, 10619.
- musculo-cutaneous, of leg, external dorsal branch, K11, 10217, 10317, 10416, 10515, 10616.
- Nerve, musculo-cutaneous, of leg, digital branches, 11318.
- musculo-spiral, 2222-69, 2322-77, 5012, 5112, 5213, 5314, 5414, 5514, 5612, 5714, 5819, 5926.
- nasal, 815-83.
- obturator, K6, 3620, 3722, 3820, 3917-56, 4015, 4161, 4515-54, 4611, 479.
- obturator, deep branch, 4220-64, 4322, 442, 4811, 4912, 762, 772.
- obturator, superficial branch, 4313, 4811, 4925, 762, 772.
- occipital, great, 1146-54, 1225, 1336, 1427-45.
- occipital, lesser, 1227, 1320, 1424, 1524, 1624-36.
- oculo-motor, 825-62.
- oculo-motor, inferior branch, 912-82.
- ophthalmic, 979.
- optic, 88.
- optic, sheath of, 815.
- palatine, 107.
- petrosal, superficial, great, 929.
- phrenic, 1915-36, 209-56, 217-73, 226-66, 2411-68, 2569, 2617-65, 2717-71.
- plantar, external, 10811, 10915, 11017.
- plantar, external, deep branch, 11110.
- plantar, internal, 1089, 10911, 11010-12, 11119, 11312.
- popliteal, external, K11, 8714, 8812, 8917, 9021, 9123, 9215.
- popliteal, internal, K11, 8714, 8812, 8915, 9018, 9119, 9212, 939, 946, 956, 962, 9711, 985, 996, 1006, 1017, 1027, 1037, 1047, 1057, 1066, 10710.
- pudic, K6, 4020-42, 4127-46, 4225-49, 4526-44, 4621, 4721.
- radial, K9, 6025, 6127, 6225, 6324, 6422, 6520, 6621, 6720, 6820, 6915-19, 7022, 7122.
- recurrent laryngeal, 215-78, 2299, 23101.
- sacral, 3629, 3722, 3820-34-37, 3928-36-40-44.
- saphenous, external or short, 982, 9910, 10019, 10111, 10210, 10310, 10411.
- saphenous, internal or long, 4393, 4425, 7621, 771, 781, 792, 802, 812, 823, 834, 842, 852, 864, 872, 882, 892, 907, 912, 922, 932, 944, 954, 963, 973, 982, 993, 1002, 1014.
- scapular, posterior, 2122.
- sciatic, great, K6, K11, 4024-47, 4122-51, 4220-53, 4327-48, 449, 4524-47, 4640, 4718-49, 4822, 4915-27, 7615, 7718, 7811, 7914, 8019, 8112, 8210, 8314, 8412, 8512, 8612.
- sciatic, small, 4221-51, 4327-47, 447, 4619, 4720-39, 4819, 4917-25, 7614, 7716, 789, 7912, 808, 8113, 828, 8313, 8411, 8512, 8611, 8712, 8811, 9016, 9112.
- spinal, 3245.
- spinal accessory, 1121-43-71, 1220-37-48, 1318-50, 1426-56, 1519-45, 1620-49, 1725-47, 1818-43.
- spinal accessory, spinal portion, 1918-51.
- Nerve, splanchnic, great, 2520-44, 2625-44, 2728-46, 2822-47, 2927-46, 3027-57.
- splanchnic, lesser, 2727-45, 2821-45, 2925, 3027-56, 3111.
- sub-occipital (root of), 1229.
- subscapular, long, 2217, 2326-84, 2421-56, 2623-58, 2726-60.
- subscapular, long, branch of, 2624-56.
- supra-clavicular, 1919-48-49, 2024.
- supra-orbital, 792.
- supra-scapular, 2158.
- sympathetic, 1128, 1217-49, 1517, 1617, 1718-50, 1810-50, 1912-59, 209, 2218, 2322-60, 2425-43, 2527, 2625-44, 2727-45, 2825-46, 2926-46, 3028-54, 3228, 3328-46, 3428-45, 3520-43, 3618, 3722-44.
- thoracic, anterior, internal, 2216, 2317-88.
- tibial, anterior, K11, 9316, 9415, 9515, 9617, 9718, 9815, 9918, 10018, 1013, 10218, 10320, 10421, 10520, 10618, 10723, 10824, 10926, 1102, 1112, 1122.
- trigeminal, 962.
- trigeminal, motor root, 923.
- ulnar, K9, 2222-69, 2322-77, 508, 519, 529, 537, 542, 557, 562, 575, 582, 5912, 6011, 619, 627, 632, 645, 655, 664, 672.
- ulnar, superficial, deep branch of, K9, 692, 704, 715, 724, 732.
- ulnar, dorsal cutaneous branch, K9, 682, 692, 709, 7110, 729.
- vagus, 1021, 1221-49, 1321-48, 1428-55, 1518-44, 1619-41, 1719-49, 1813-48, 1914-54, 2027-58, 21625, 224-96, 2398, 2428-49.
- vagus, pharyngeal branch of, 1317, 1425-57.
- vagus, bronchial branch, 2524.
- Nodule of cerebellum, 944.
- Nucleus, amygdaloid, 866.
- anterior, of optic thalamus, 679.
- caudate, 518-39.
- caudate, tail of, 519, 654, 768, 861.
- dentate, 1044.
- gracilis, of column of Goll, 1147-51.
- lateral, of optic thalamus, 621-64, 711.
- of Luys, 772.
- middle, of optic thalamus, 628-57, 772.
- red, of tegmentum, 722, 820.
- Obturator groove, 418.
- membrane, 4159, 4759.
- Occipital protuberance, internal, 944.
- Odontoid process of axis, 1320.
- Oesophagus, K7, 2027, 2129, 22109, 2357, 2440, 2543, 2647, 2747, 2855.
- Olecranon, 5910.
- Olfactory tract, 82.
- Olive, 1147.
- Omentum, gastro-splenic, 2854-61.
- greater, 2965, 3327, 3525-62, 3627, 3862.
- lesser, 2929, 3115, 333.
- Operculum, K2, 511, 668.
- Optic chiasma, K3, 884.

- Optic radiations, 629-56.
 — thalamus, K3.
 — tract, 75-24-30, 88¹.
 Orbital fat, 79⁰.
 — plate of frontal bone, 85⁵.
 Os calcis, 107¹², 108¹⁵, 109¹⁹.
 — magnum, K9, 71¹⁶.
 — planum of ethmoid, 8⁰.
 Ovary, 45¹⁷⁻⁵².
- Pacchionian glands, 12².
 Palate, hard, K3, 12¹.
 Pancreas, K7.
 — body of, 29⁶⁰, 30⁷⁴, 31⁷⁰.
 — duct of, 30⁷⁶, 31⁶⁸.
 — head of, 32⁶.
 Panniculus adiposus or superficial fascia, 22²⁷⁻⁷³, 28⁸, 35⁶⁸, 42⁴⁴, 49²².
 Papillæ of kidney, 32²⁵⁻⁴⁸.
 Patella, K11, 89¹, 90²⁰.
 — external ligament of, 90²⁸.
 — internal ligament of, 90¹, 91².
 Peduncles, cerebellar, inferior, 10³⁶⁻⁴².
 — cerebellar, middle, 9³⁸⁻⁵², 10¹⁸.
 — cerebellar, superior, 8¹¹, 9⁴¹⁻⁴⁹.
 — cerebral, 8⁶¹.
 Pelvis, brim of, 39¹⁸.
 — white line of, 47¹⁴⁻⁴⁴.
 Perforated space, posterior, K3.
 Pericardium, visceral layer of, 25⁶⁰, 27¹⁰.
 — parietal layer of, 23², 24⁴⁸, 25⁴⁻²⁴, 27⁹⁻⁵³, 28⁷².
 Pericranium, 1⁸.
 Peritoneal sac, lesser, 28⁵⁸, 29⁵⁶⁻⁶⁷, 30⁶³, 31⁶².
 Peritoneum, 29⁶², 40³⁸, 45³³.
 — cavity, K8, 28¹¹⁻⁵⁹, 29¹²⁻⁷², 30⁷⁰, 31², 32²⁻¹⁹, 33¹⁻⁶⁰, 34⁴, 35¹⁹⁻⁶⁰⁻⁷², 36¹⁻¹⁰, 37³, 38⁵⁻⁴⁴⁻⁴⁶, 39²¹, 40⁴⁰⁻⁷⁰, 45⁶⁷, 46².
 — parietal, 27⁶⁵, 33⁶⁻⁶⁷, 34¹⁹, 35⁹⁻⁷⁰.
 — visceral, 33⁷, 34⁶.
 Phalanges of fingers, K9, 73²⁵, 75³⁻⁶⁻¹².
 — of toes, 113¹⁰.
 Pharynx, 12¹, 16⁸.
 — laryngeal portion, K3, 17³, 18⁵⁶, 19⁶².
 — nasal portion, 11³, 13¹.
 — oral portion, K3, 14⁷³, 15⁵.
 Pia mater of brain, 1⁷.
 Pineal body or gland, K3, 7³³.
 Pituitary body, K3, 9⁸⁶.
 Platysma myoides, K2, 13¹¹, 14²⁰, 16¹³⁻⁶⁰, 17⁹⁻⁵⁷, 18⁶⁻⁵⁷, 19⁸, 20⁶².
 Pleura, diaphragmatic, 27¹⁵⁻⁵⁹, 29¹³.
 — mediastinal, 25⁸, 27¹³.
 — parietal, 22¹⁰, 23⁸⁻⁹¹.
 — visceral, 23¹³⁻⁹², 28²⁷.
 Pleural cavity, 22⁹², 23⁹, 24⁶⁹, 25⁵, 26²⁴, 27⁶⁸, 28¹⁴.
 Plexus, nerve, brachial, 21⁷⁰.
 — celiac plexus, 30²⁸⁻⁶⁸, 31³¹⁻⁴⁵.
 — sympathetic, abdominal aortic, 32²⁷⁻³⁷⁻⁵⁰, 33¹⁶, 34³³, 35³³, 36²⁴.
 — sympathetic mesenteric superior, 32⁶³⁻⁶⁷, 33⁶⁵.
- Plexus, sympathetic, mesenteric inferior, 35²⁷.
 — sympathetic, œsophageal, 25⁴³, 26³³⁻⁴⁹⁻⁵¹, 27³⁰⁻⁵⁴, 28⁶³.
 — sympathetic, utero-vaginal, 45⁵¹, 46¹⁸⁻²⁹, 47¹⁷⁻³⁸⁻⁴².
 — venous, pampiniform, 41⁶⁸, 42⁷⁵, 43⁶⁸, 44²⁻³⁴.
 — venous, pudendal, 41⁵⁵, 42⁸, 43⁶⁻³³.
 — venous, sacral, anterior, 39³⁵.
 — venous, vesical, 40⁵¹.
 — venous, of vertebræ, 12²⁵⁻⁴⁰, 13⁴¹, 14¹⁷, 30⁴³.
- Pole, frontal, of brain, K2.
 — occipital, of brain, K2.
 — temporal, of brain, 9⁷⁰.
- Pons Varoli, K3.
 — Varoli, arm of, 9³⁸⁻⁵², 10¹⁸.
 — Varoli, deep fibres of, 8³¹, 9⁶⁴.
 — Varoli, pyramidal tracts of, 8³², 9³⁷, 10⁵⁰.
 — Varoli, superficial fibres of, 8³¹, 9⁵⁷⁻⁷⁰.
- Popliteal surface of femur, 87⁴, 88¹³.
 Portio minor of trigeminal nerve, 9²³.
 Pouch of Douglas, K8, 45³⁵.
 Prææneus, K3, 2¹⁴, 3²¹, 4²⁸, 5²⁷, 6⁴⁴.
 Prepuce of clitoris, 49¹.
 Process, angular, external of frontal, 7¹⁷.
 — clinoid, anterior, 8²².
 — clinoid, posterior, 8²⁴.
 — condyloid, of mandible, K2, 10⁶².
 — coracoid, K4, K5, 21¹⁷⁻⁶⁴.
 — coranoid, of mandible, 11¹⁶⁻⁸⁴.
 — frontal, of malar bone, 8⁷⁴, 9¹⁸⁻⁷⁸.
 — nasal, of maxilla, 8², 9³⁻⁶⁴.
 — spinous, of 5th cervical vertebra, 19³⁴.
 — spinous, of 1st lumbar vertebra, 32³⁶.
 — spinous, of 4th lumbar vertebra, 36³⁸.
 — spinous, of 5th lumbar vertebra, 37³⁴.
 — spinous, of 2d thoracic vertebra, 21⁴².
 — spinous, of 4th thoracic vertebra, 23³⁵.
 — spinous, of 5th thoracic vertebra, 24³⁹.
 — spinous, of 6th thoracic vertebra, 25⁴¹.
 — spinous, of 7th thoracic vertebra, 26⁴⁰.
 — spinous, of 8th thoracic vertebra, 27⁴¹.
 — spinous, of 9th thoracic vertebra, 28³⁹.
 — spinous, of 12th thoracic vertebra, 30⁴⁶.
 — styloid, of radius, K9.
 — styloid, of temporal bone, K2.
 — styloid, of radius, 70²³.
 — trochlear, of calcaneus, 108¹⁷.
 — zygomatic, of maxilla, 10⁷⁰.
- Prostate, K7.
 — base of, 42¹³.
 Prostatic urethra, 42³⁹.
 Pulvinar, 6³⁰, 7⁶⁰.
 Putamen, 5¹⁰, 6²⁰⁻⁶⁹, 7²²⁻⁸⁴.
 Pylorus, 31⁷¹, 32⁷⁰.
 Pyramidal body of medulla, 11⁵⁰.
- Quadrangle lobe of brain, 2¹⁴, 3²⁴, 4²⁸, 5²⁷, 6⁴⁴.
- Quadrigeminal body, anterior, K3, 7⁶³.
 — body, posterior, K3, 7⁴⁸⁻⁵⁷, 8⁶⁰.
- Radius, K9, 61²¹, 62²², 63²⁰, 64¹³, 65¹⁶, 66¹⁸, 67¹⁷, 68¹⁶, 69²⁰.
 — neck of, 60¹⁷.
 — pit of head of, 59²².
 Ramus of ischium, 43²¹, 48³⁰.
 — of mandible, 12¹³, 13⁵⁴.
 — pubic, ascending, 41⁶.
 — pubic, descending, 42⁹, 43⁴⁹, 48³.
 Rectum, 40³⁹, 45⁵⁹, 46³⁰.
 Rete venosum vertebræ, 13⁴⁹, 14⁴⁴, 16²⁸, 17²⁸, 21⁴³.
 Retina, 8¹¹.
 Rima glottidis, 19⁶⁶.
- Sacro-iliac articulation, 37⁴³, 39²⁹.
 Sacrum, K4.
 — articular process of, 37²⁹.
 — canal of, 38³⁸.
 — canal, inferior opening of, 40³⁷.
 — foramina of, 38³², 39³⁴⁻⁴¹.
 — lateral ridges of, 38⁴³, 40³⁴.
 Scapula, K4, 21²⁶⁻⁵⁷, 22³⁵, 23⁴⁰, 24³⁰.
 — acromion process, K4.
 — coracoid process, K4, 21¹⁷⁻⁶⁴.
 — angle, inferior, 25³⁰.
 — angle, superior, K4.
 — axillary border, 22³¹⁻⁷².
 — vertebral border, 22⁶².
 Serotum, 44²³.
 Semicircular canal, superior, 9³³.
 Semilunar cartilage of knee, external, 91²⁶.
 — cartilage of knee, internal, 91⁴.
 Septum, auricular, 26⁰.
 — of corpora cavernosa, 48¹.
 — fibrous, of tongue, 14².
 — nasi, K3, 10⁷³.
 — ventricular, 26⁶⁰⁻⁷⁰.
 Sheath of rectus muscle, K5, 37⁶, 40⁴, 45⁸⁸, 46⁵⁹.
- Sinus, coronary, of heart, 26⁵².
 — frontal, 6², 7⁴, 8⁸⁸.
 — lateral, 9³⁶⁻⁴⁰⁻⁴⁵⁻⁵⁴, 10²⁷⁻⁵⁴, 11³⁸⁻⁶⁴.
 — petrosal, inferior, 9²⁴⁻⁷⁵, 10²³.
 — phrenico-costalis, 28⁵⁹⁻⁷¹, 29⁸⁻⁴⁸⁻⁷³, 30¹⁸, 31²⁰⁻⁵¹.
 — rectus, 7⁵², 9⁴⁵.
 — of kidney, 31⁴⁹, 32²⁴.
 — longitudinal, inferior, 6⁴².
 — longitudinal, superior, 1¹³, 2¹³⁻²⁴, 3¹⁻²³, 4²⁰⁻³⁰, 5²⁸⁻⁵⁴, 6⁴³, 7⁵², 8⁴⁵.
 — longitudinal, vertebral, 15⁸⁴.
 — transverse, of pericardium, 24³.
 — of Valsalva (aorta), 25⁸⁰.
 Spermatic cord, K5, 40⁸, 41⁵, 42⁶.
 Spheno-maxillary fissure, 9¹⁴.
 Spinal cord, K3, 14⁴¹, 15²⁹, 16²⁹, 17³², 18²⁹, 19²³, 23⁵⁹.
- Spine, iliac, anterior, inferior, K4, 39⁶⁰, 45¹².

- Spine, iliac, anterior, superior, K4, K5, 38¹³.
 — of ischium, 41²⁵⁻⁴⁸, 46²⁰⁻³⁸.
 — nasal, K2.
 — of pubis, 41⁴, 47³⁻⁵⁴.
 — of scapula, 20¹⁷⁻⁵², 21²⁰⁻⁵⁵.
 — of tibia, 91³.
 Spleen, K7, 28⁵⁶, 29⁶¹.
 — accessory, 29⁵⁹.
 Splenium of corpus callosum, 5²³, 6⁵⁶⁻⁴⁹.
 Sterno-clavicular articulation, disc of, 22⁵.
 Stomach, K7, 28⁶⁴, 29⁶⁹, 30⁸⁰, 31⁶⁶, 32⁶⁶.
 Striations, medullary, of thalamus, 6¹⁰.
 — transverse, of corpus callosum, 5²³.
 Sub-arachnoid space, 13³⁸, 14⁴², 19²², 29⁴².
 Sub-dural space, 2², 3²⁵, 6³⁰, 8⁵⁷.
 Substantia nigra, 7³², 8⁵⁸.
 Suleus. See Fissure.
 Superficial fascia, 1⁴⁻¹³, 3¹⁵.
 Suprarenal bodies, K7, 29²⁷⁻⁵¹, 30⁵⁹.
 Sustentaculum tali, 108⁶.
 Suture, coronal, K2, 1⁵⁻¹⁹, 2⁴, 3⁹⁻⁵⁴, 4⁸, 5⁹⁻⁴⁵, 6¹²⁻¹⁶.
 — fronto-malar, K2.
 — lambdoid, K2, 5²⁵, 6³⁸, 7⁴³⁻⁶¹, 8⁵⁸.
 — malo-maxillary, K2.
 — naso-frontal, K2.
 — naso-maxillary, K2.
 — occipito-mastoid, 11³⁹.
 — sagittal, 1², 2¹³, 3²², 4²⁵.
 — spheno-frontal, K2.
 — spheno-squamosal, 7²³.
 — squamo-parietal, K2, 6²⁵, 8⁵⁴.
 — temporo-malar, K2.
 Symphysis pubis, K4, K8.
 — pubis, cartilage of, 41⁷², 47⁴.
 Tarsal cartilage, 7¹³, 9⁸⁶.
 Tegmentum, 8³⁴.
 Temporal ridge, 6⁹, 7⁸⁶.
 Tendo Achillis, 102⁹, 103⁹, 104⁹, 105¹⁰, 106⁹, 107¹³.
 Tentorium of cerebellum, 8⁴⁸.
 Testicle, 44²⁵.
 Thalamus, medullary layer of, 6⁶¹.
 Thoracic duct, 21²⁵, 22²⁸, 24⁴¹, 25⁴², 26²⁸, 28³⁵, 29³⁹, 30⁴², 31³⁶, 32⁵⁴.
 Thymus gland, 22³⁹, 23⁴, 24².
 Thyroid gland, 19⁹, 20³⁻⁶³, 21⁷⁷.
 Tibia, K11, K13, 91⁴, 92¹, 93², 94¹, 95², 96¹, 97¹, 98¹, 99¹, 100¹, 102², 103², 104², 105³, 106³.
 — articular surfaces, 91⁴⁻²⁹.
 — infraglenoid margin of, 91²⁸.
 — internal malleolus, 107³.
 Tongue, root of, 16³⁸.
 Tonsil, 13⁶⁹, 14¹²⁻⁶⁶, 15¹¹.
 Trachea, K7, 20⁶⁸, 21¹, 22¹, 23¹.
 Trigone, 46⁴.
 Trochanters of femur, greater, K4, 41⁵³, 42²⁵.
 — of femur, lesser, K4, 43²⁵⁻⁵¹, 49¹².
 Tuber cinereum, 7¹⁹.
 — valvulus, K3, 10¹⁰.
 Tuberosity of calcaneum, 108¹².
 — of humerus, greater, K4, 21⁶¹.
 — of humerus, lesser, 21⁶².
 — of ischium, 42²³, 47²⁸, 48²⁰.
 — of radius, K9.
 — of ulna, 60¹⁵.
 — of tibia, K11, 93¹.
 Tunica albuginea of testis, 42⁷⁸, 43³.
 — vaginalis, 43⁷.
 — vaginalis propria, of testis, 44³⁶.
 Turbinal, inferior, K3, 11⁹⁶.
 — middle, K3, 9², 10².
 Tympanic cavity, 10⁶⁰.
 — membrane, 10⁵⁹.
 Ulna, K9, 61¹², 62¹², 63¹¹, 64⁹, 65⁹, 66³, 67³, 68⁹, 69⁸.
 — greater sigmoid cavity of, 59⁹.
 Umbilicus, K5, K7.
 Uncus, 8⁶⁶.
 Urachus, K5, 36⁷⁴, 37⁷², 38⁷², 39⁷⁴, 40⁷², 45¹, 46⁵⁸.
 Ureter, K7, 31⁴⁸, 32⁴⁸, 33²²⁻⁴⁸, 34²³⁻⁴⁸, 35²³⁻⁴⁷, 36²¹⁻⁵³, 37¹⁷⁻⁵³, 38¹⁹⁻⁵³, 39²⁰⁻⁵², 40²¹⁻⁴⁹, 45²¹⁻⁵¹, 46⁴¹.
 — orifice of, K8, 46⁴⁸.
 Urethra of female, K8, 48⁴⁹.
 — of female, internal, orifice of, 47⁴.
 — of male, 43⁶⁴⁻⁶⁹.
 — of male, internal orifice of, 41³.
 Utero-vesical pouch, K8, 45⁴.
 Uterus, cervix of, K8, 45⁴⁹.
 — anterior lips of, 46³¹.
 — body of, 45⁶⁹.
 — fundus of, K8, 45².
 Uvula of cerebellum, K3, 10⁴⁹.
 — of palate, K3, 13⁶⁵.
 Vagina, K8, 46²⁷, 47²⁷, 48⁴³.
 — anterior wall of, 47³¹.
 — orifice of, K8.
 — posterior wall of, 46²⁴.
 — vestibule of, 49³⁸.
 Valve, Eustachian, 26¹³.
 — ileocaecal, K7, 38¹¹.
 Valve of heart, aortic, 25⁸⁰.
 — of heart, bicuspid, posterior cusp, 26⁶⁶.
 — of heart, pulmonary, 24⁷².
 — of heart, tricuspid, 26⁷⁶.
 — of Houston, 41⁴¹.
 — of Vieussens, 9⁴².
 Valvula conniventes, 34⁹⁻⁶⁶, 35⁶⁴, 36³.
 Vas deferens, 40¹⁹⁻⁵⁷, 41⁶⁷, 42⁷⁴, 43⁶², 44³⁴.
 Vasa brevia of splenic artery, 28³².
 — efferentia of testis, 44³.
 — intestini tenuis, K6, 33⁶¹, 34⁵⁶⁻⁵⁷, 35⁵²⁻⁵⁴, 36²⁻⁶⁶⁻⁶⁶, 37⁶².
 Vein, angular, 8⁴⁻⁸⁹, 10⁷, 11⁸⁻⁹², 12⁶³.
 — arcuate or archiform, 30²⁸.
 — auricular, posterior, 12⁴⁶, 13⁴⁷.
 — axillary, K6, 22¹⁵⁻⁸⁴, 23²³⁻⁸³.
 Vein, azygos, 24²⁶, 25⁴⁰, 26³⁹, 27¹⁰, 28³⁴, 29²⁸.
 — basilic, K9, 50⁵, 51⁷, 52⁵, 53³, 54⁵, 55⁵, 56⁴, 57⁴, 58⁵, 59⁷, 60⁸, 61¹⁰, 62¹⁰, 63⁹, 64⁸, 65⁷, 66⁷, 67⁷, 68⁷, 69⁷, 70⁸.
 — brachial, 50⁹, 51⁸, 52⁷, 53²⁻⁶, 54², 55², 56⁴, 57¹, 58¹, 59².
 — cardiac, anterior, 26⁴, 27⁸³.
 — cardiac, great, 25⁶⁷⁻⁷², 26⁷¹.
 — cephalic, K9, 22¹⁰, 23⁸⁰, 50²⁰, 51¹⁰, 52²⁰, 53²⁰, 54¹⁰, 55¹⁰, 56¹⁵, 57¹⁰, 58²¹, 59²⁸, 60²⁷, 61²⁰, 62²⁴, 63²³, 64²¹, 65¹⁹, 66²⁰.
 — cerebral, central or deep, 7⁴⁰.
 — cerebral, superior, 1², 3²¹.
 — cervical, deep, 14³⁸, 15³⁷, 16²⁷⁻⁵³, 17²⁹, 18²²⁻³⁸, 19²⁴⁻⁴⁴, 20²⁹.
 — circumflex, iliac, deep, 37¹⁴, 38⁵⁹, 45⁶¹.
 — circumflex, external, of femur, 43⁵⁷, 48¹⁰, 49⁹.
 — circumflex, internal, of femur, 48¹⁴⁻³³, 49¹⁴⁻²⁸.
 — colic, left, 31⁵³, 32⁵², 33⁴⁹.
 — colic, middle, 31⁶⁴.
 — colic, right, K6, 34¹¹⁻⁷¹, 35¹⁵, 36¹⁰, 37¹⁵, 38¹⁴.
 — coronary of stomach, 29⁶⁶, 30⁷⁸⁻⁸⁴.
 — diploic, 4³, 5⁴, 6⁵⁻⁷⁸, 10²⁰.
 — dorsal, of penis, 42¹⁻⁵, 43⁷².
 — emissary of condyle, 11²⁵⁻⁷⁰.
 — epigastric, deep, 38⁶⁸, 39⁵⁻⁷⁰, 45⁸.
 — epigastric, superior, 30⁵.
 — facial, common, 17¹⁵, 18²², 19⁵⁷.
 — facial, anterior, 13⁹⁻⁵⁹, 14¹¹⁻⁶⁹, 15⁹⁻⁵⁴, 16¹¹⁻⁴⁹, 17¹⁰⁻⁵⁴.
 — facial, posterior, 11²⁵⁻⁷⁴, 17¹²⁻⁵².
 — femoral, common, K11, 41⁹⁻⁶³, 42⁶⁹, 43⁶⁹, 44²⁶, 46⁸⁻⁵¹, 48⁹, 49⁴, 76¹, 77², 78², 79², 80², 81⁴, 83³, 84², 85⁴.
 — frontal, branch of, 3⁴⁰.
 — of Galen, 6⁴⁹, 7⁴⁰.
 — gluteal, 39²⁶⁻⁴⁷⁻⁴⁹.
 — hæmorrhoidal, inferior, 48²¹⁻²⁹.
 — hæmorrhoidal, middle, 45²⁸⁻⁴⁵, 46²³⁻³⁷.
 — hæmorrhoidal, superior, 36⁶⁴, 37⁴⁰, 38⁵⁹, 39³⁸, 45⁴⁴⁻⁴¹, 46²⁵⁻³⁴.
 — hemiazygos, 28⁴⁴, 29⁴⁵.
 — hemiazygos, accessoria, 23⁵⁹, 24⁴⁴, 26⁴², 27⁴⁴.
 — hepatic, K6, 27¹², 28⁹, 29¹⁰⁻²³, 30²².
 — iliac, common, K6, 37²¹⁻⁴².
 — iliac, external, 38²¹⁻⁵¹, 39¹³⁻⁵⁹, 40¹¹⁻⁶³, 45¹¹.
 — iliac, internal, K6, 38²⁶⁻⁴⁷, 39²⁶⁻⁴⁷.
 — iliac, internal, branch of, 39²³.
 — ilio-colic, 35¹⁰, 36⁹, 37⁹, 38¹⁰.
 — ilio-lumbar, 37⁵², 38⁴⁹.
 — innominate, right, K6, 22⁵.
 — innominate, left, 22⁹⁴.
 — intercostal, 22⁴¹⁻⁵⁴, 23⁶⁶, 25³², 26¹⁸⁻³¹⁻⁴⁸, 27²³⁻²⁷⁻⁵⁹.
 — inter-lobar, of kidney, 30⁶¹.
 — intervertebral, 20²⁸.
 — jugular, anterior, 18¹, 19², 20²⁻⁶², 21².

- Vein, jugular, external, K6, 11⁷⁰, 13¹⁰⁻⁴⁹, 14²⁴, 15¹³, 16¹⁷, 17¹⁹, 18¹⁴, 19²¹, 20¹⁶, 21¹⁰.
- jugular, internal, K6, 11³³, 12⁴⁶, 13²¹, 14²⁷⁻⁵⁴, 15¹⁹⁻⁴⁴, 16²¹⁻⁴⁰, 17²⁰⁻⁴⁵, 18⁴⁷, 19¹⁴⁻⁵³, 20⁹⁻⁵⁸, 21⁷⁻⁷⁴.
- lingual, 15⁵⁹, 16⁷⁻⁵³.
- lumbar, ascending, 33⁴⁶, 34⁴³, 35³¹⁻⁵⁹.
- mammary, internal, 23⁴, 24⁴, 25³, 26³⁻⁷⁴, 27⁴, 28³⁻⁷⁷.
- meningeal, middle, 27, 5¹¹, 6¹⁷⁻⁷⁰.
- meningeal, middle, branch of, 27.
- mesenteric, inferior, K6, 32⁵⁵, 33⁵¹, 34⁵¹, 35⁴⁴.
- mesenteric, superior, K6, 32⁶⁰⁻⁶⁸, 33⁷⁰, 34⁵⁹.
- oblique, of Marshall, 25⁶⁶.
- obturator, 39¹⁹⁻²⁵⁻⁴⁸, 40¹⁸⁻⁵⁰, 41¹⁰⁻⁶⁰, 45¹⁵⁻⁵⁴, 46¹¹, 47⁵⁰, 48¹².
- occipital, 5²²⁻²⁹, 10³⁵, 11⁴⁰.
- occipital, branch of, 2¹⁰⁻¹², 3¹⁸⁻²⁵, 4²³, 11⁴⁵⁻⁵⁵.
- ophthalmic, superior, 7⁸, 8¹⁷⁻⁷⁸, 9⁸².
- ovarian, 45⁵⁵.
- palatine, 17⁵⁶.
- of penis, deep, 43⁶⁸.
- of penis, dorsal, 42¹⁻⁵, 43⁷³.
- perforating, 42²²⁻⁶², 43⁵⁰, 44⁸, 76¹⁸, 77¹⁹, 81¹⁰, 82⁹.
- peroneal, 94¹², 95¹², 96¹³, 97¹², 98¹⁰, 99¹², 100¹², 101¹³, 102¹⁵, 104¹⁵.
- pharyngeal, 11¹⁸, 12¹⁵⁻⁵⁸, 13¹³, 14⁶², 15¹⁴.
- phrenic, inferior, 28²³⁻⁵³.
- plantar metatarsal, 112¹³.
- popliteal, K11, 87¹⁰, 88², 89¹⁰, 90¹⁵, 91¹⁸, 92⁹, 93¹³.
- portal, K6, 30⁶⁻⁹⁻¹⁷, 31¹⁸⁻⁷², 33¹⁷.
- profunda femoral, 44¹⁵, 49³³, 76³⁰, 77²⁵, 78²², 79⁹, 80¹³, 81¹, 82¹⁴, 83¹⁶.
- pudic, internal, 40⁴⁶, 41⁴⁶.
- pulmonary, right, K6, 24¹⁷, 25¹⁹⁻²⁰⁻²⁹⁻⁵⁰⁻⁶³.
- Vein, pulmonary, left, K6, 24⁶⁰⁻⁶², 25⁵²⁻⁶⁴.
- radial, 60³⁰, 61²⁹.
- renal, K6, 31²⁶⁻⁴⁷, 32²²⁻⁴⁷.
- renal, branch of, 29⁵⁵⁻⁵⁷, 32⁴⁹.
- sacral, middle, 38⁴².
- sacral, lateral, branch of, 38³¹.
- saphenous, long or internal, K6, K11, 42⁷¹, 43¹¹, 44³⁰, 48⁷⁻⁴², 49⁵⁻³⁶, 76⁵, 77⁵, 78⁵, 79⁶, 81⁶, 85⁸, 86⁹, 87⁸, 88⁷, 89⁹, 90⁹, 91⁹, 92⁶, 93⁹, 94⁴, 95⁴, 96³, 97³, 98³, 99³, 100³, 101⁴, 102⁴, 103³, 104³, 105², 106², 107⁴.
- saphenous, short or external, 86¹¹, 87¹³, 88¹¹, 89¹⁴, 90¹⁷, 91¹⁷, 92¹⁰, 93¹⁰, 94⁹, 95⁹, 96¹⁰, 97⁹, 98⁷, 99⁹, 101¹¹, 102¹¹, 103¹¹, 104¹¹, 105¹¹, 106¹².
- sciatic, 40²⁸⁻⁴⁴, 41²³⁻²⁹⁻⁴⁷, 42³⁰⁻⁵⁰⁻⁵², 43⁴⁶, 45²⁷⁻⁴⁶, 46¹⁹, 47¹⁹⁻³⁹, 48³⁰.
- sigmoid, 36⁶³, 37⁵⁹⁻⁶⁸.
- sigmoid, branch of, 38⁵⁷, 40³³.
- spermatic, K6, 32²⁰⁻⁵¹, 33²¹⁻⁴⁷, 34²⁴⁻⁴⁹, 35²²⁻⁴⁸, 36⁵⁶, 37¹⁶, 38¹⁵⁻⁶⁰.
- splenic, K6, 29⁵⁸, 30⁷¹, 31⁶⁰.
- subclavian, K6, 22⁸⁸.
- submental, 17⁶⁶.
- suprarenal, 30⁶⁵, 31⁴⁶.
- suprascapular, 21²³.
- Sylvian, superficial, 6¹⁵, 7²⁰⁻²².
- temporal, middle, 8⁶⁵, 9⁶⁷.
- temporal, superficial, 3¹¹, 4¹³, 5¹², 6²¹, 7²⁹, 8³⁰, 9²⁸, 10¹⁹⁻⁶¹.
- thoracic, long, K6, 22⁸⁶, 23¹⁰⁻⁸⁷, 24¹⁶, 27²²⁻⁶².
- thyroid, superior, 17¹¹.
- tibial, anterior, K11, 94¹⁵, 95¹⁵, 96¹⁷, 97¹⁷, 98¹⁶, 99², 100¹⁵, 101¹, 102³, 103¹⁹, 104¹⁹, 105¹⁸.
- tibial, posterior, K11, 94³, 95³, 96⁴, 97⁵, 98⁴, 99⁵, 100⁵, 101⁷, 102⁷, 103⁵, 104⁹, 105⁸, 106⁷, 107⁹.
- transversalis colli, 20²³⁻⁴⁷, 21³².
- ulnar, 60², 61⁷.
- uterine, 45¹⁹⁻²⁰⁻⁵³.
- Vein, vertebral, 12³⁹, 13³⁵⁻⁴⁷, 14³²⁻⁵⁰, 16²³, 17²⁵⁻⁴³, 18⁴⁷, 19⁴³, 20¹⁰⁻⁵⁹, 21³.
- Velum, anterior medullary, K3.
- Vena cava, inferior, K6, 27²⁹, 28¹⁹, 29¹⁷, 30²⁹, 31²³, 32¹⁶, 33¹⁹, 34²², 35²⁵, 36²³.
- cava, superior, K6, 23⁴, 24⁹, 25¹¹.
- Ventricle, lateral, of brain, 5²⁻⁶⁶.
- fifth, of brain, 6⁸⁶.
- fourth, of brain, 9⁴³.
- third, of brain, K3, 7¹⁶.
- of heart, left, K6, 26⁶³, 27⁷⁴.
- of heart, right, K6, 25⁷⁴⁻⁷⁶, 26⁷², 27³.
- Vermiform appendix, K7, 38¹³, 39⁹.
- Vermis of cerebellum, K3.
- Vertebra, cervical, 1st, 13²⁵.
- cervical, 2d, 14⁴³, 15²³.
- cervical, 3d, 16³².
- cervical, 4th, 17⁵⁹, 18⁵⁰.
- cervical, 5th, 19²⁷.
- cervical, 7th, 20¹.
- lumbar, 1st, 31³⁷.
- lumbar, 2d, 32³⁶.
- lumbar, 3d, 33³⁶.
- lumbar, 4th, 35³⁶.
- lumbar, 5th, 37³⁷.
- sacral, 1st, 38⁴¹.
- sacral, 3d, 39³⁹.
- sacral, 5th, 40³⁵.
- thoracic, 1st, 21⁴⁰.
- thoracic, 3d, 22⁵¹.
- thoracic, 4th, 23⁵⁴.
- thoracic, 5th, 24³⁹.
- thoracic, 7th, 25⁴¹.
- thoracic, 8th, 26⁴¹.
- thoracic, 12th, 30⁴⁸.
- Vesicles, seminal, 41³⁹.
- Vitreous body, or humor, 8¹⁴⁻⁸⁰, 9⁸⁵.
- Vomer, 10⁷⁸, 11⁹⁸.
- Xiphoid cartilage, K4, K5, 28⁷⁸, 29⁴.
- Zygoma, 10⁶⁴.

(1)

THE END

